Clínica Universitária de Radiologia
ADI Associação para o Desenvolvimento da Imagiologia nos CHUC

CHUC
CENTRO HOSPITALAR E UNIVERSITÁRIO DE COIMBRA

Caso clínico

Diogo Roriz

Serviço de Imagem Médica
Dir: Prof. Doutor Filipe Caseiro Alves

01/06/2015

História clínica

♂, 87 anos

Caucasiano

Seguido em consulta de Cardiologia

- Cardiopatia valvular
- Insuficiência cardíaca
- Enfarte agudo do miocárdio há 15 anos

DPOC

Fumador (30 UMA)

História clínica

Recorre ao SU por agravamento da dispneia, agora para pequenos esforços, ortopneia e tosse com expectoração nos últimos 2 dias, acompanhados de anorexia nos últimos meses

Radiografia do Tórax

Descrição

Opacidades micronodulares predominando nos andares médio e inferior, de forma mais exuberante à direita.

Ateromatose calcificada e desenrolamento do arco aórtico.

Alterações degenerativas da coluna lombar.

TC tórax

L

L

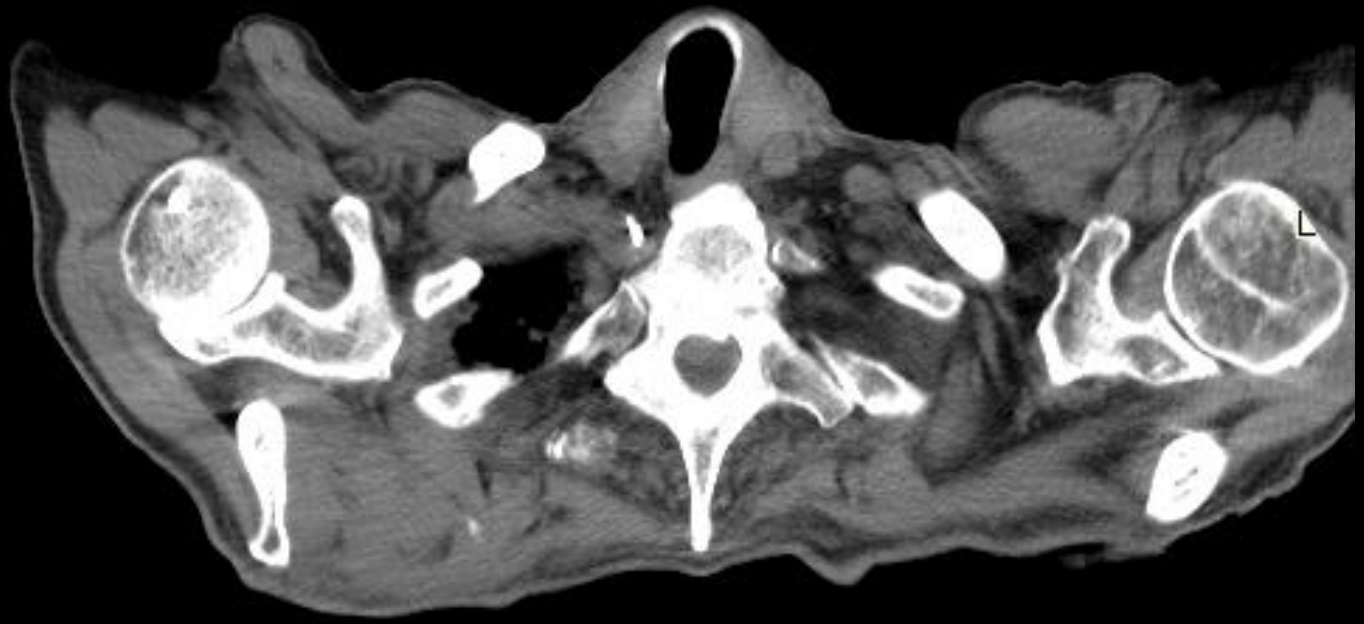
L

L

L

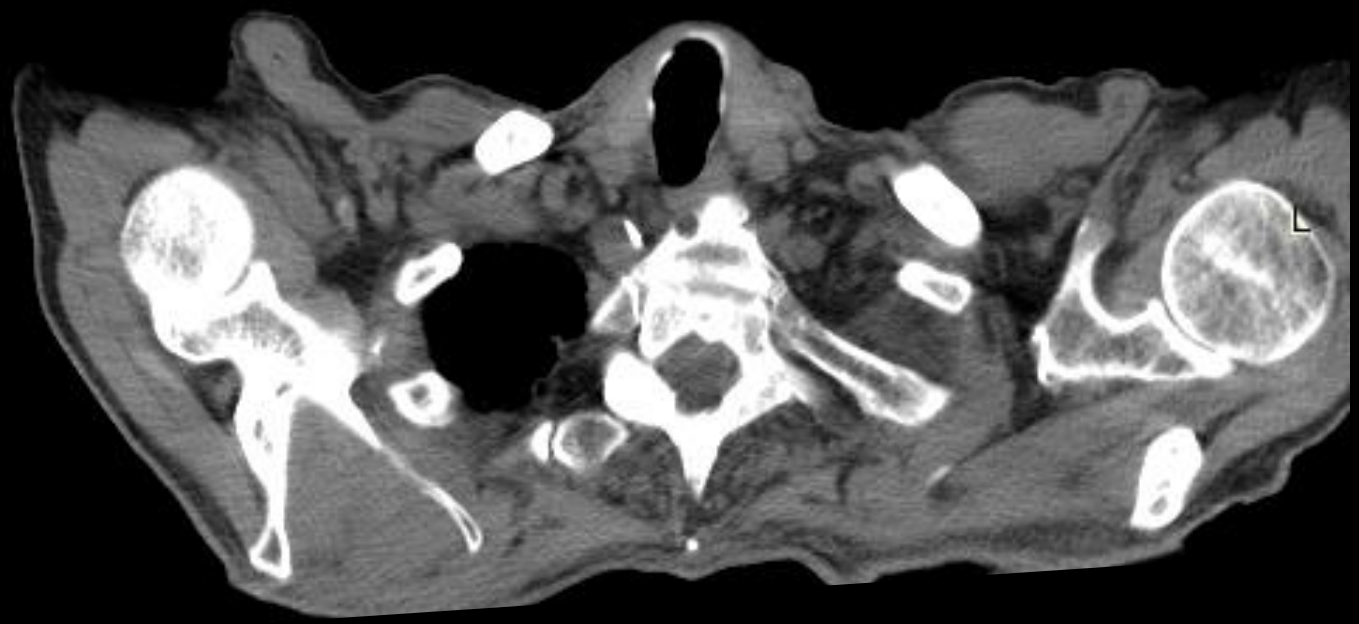
L

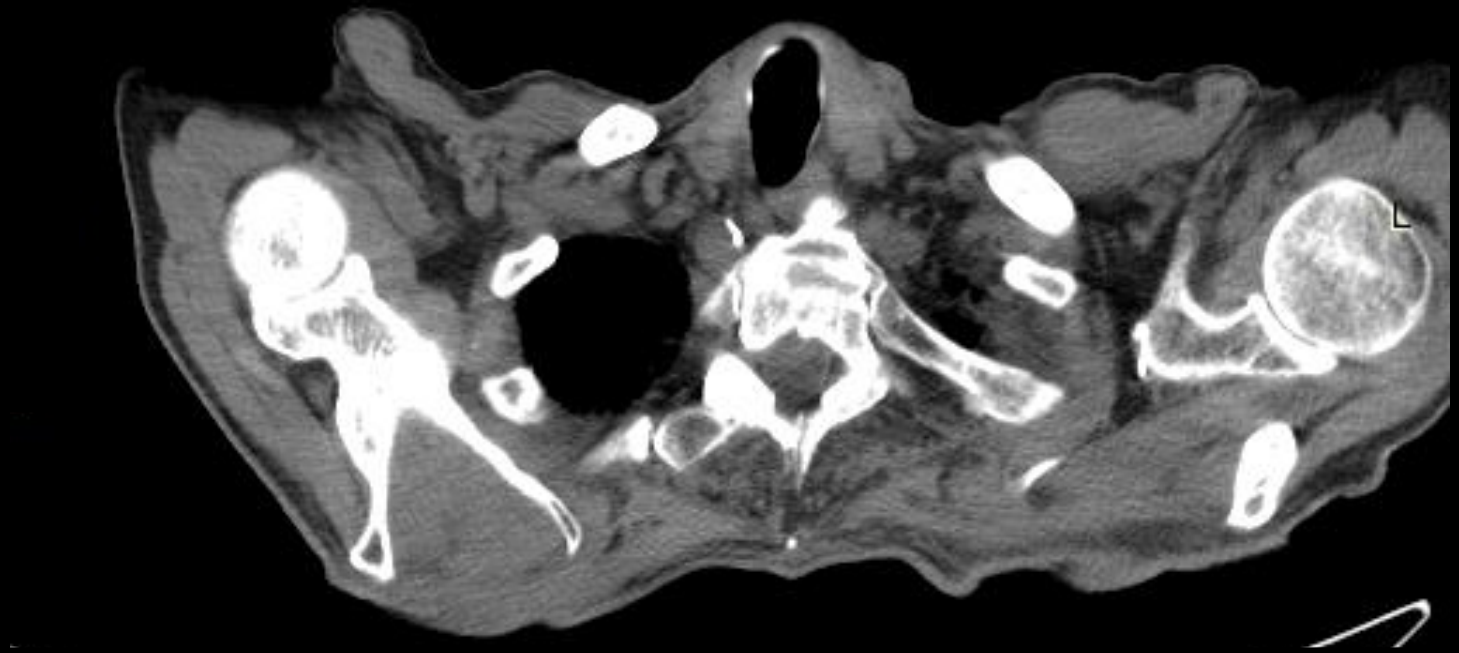
L

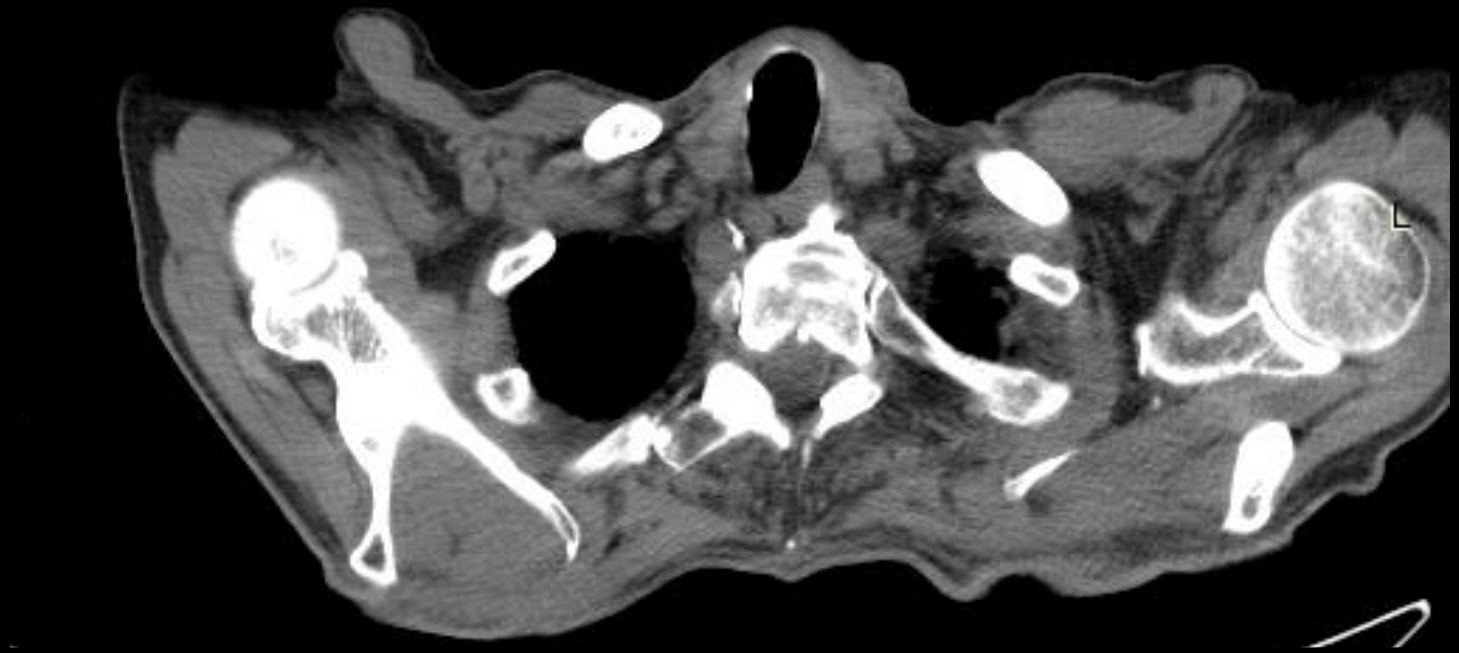
L

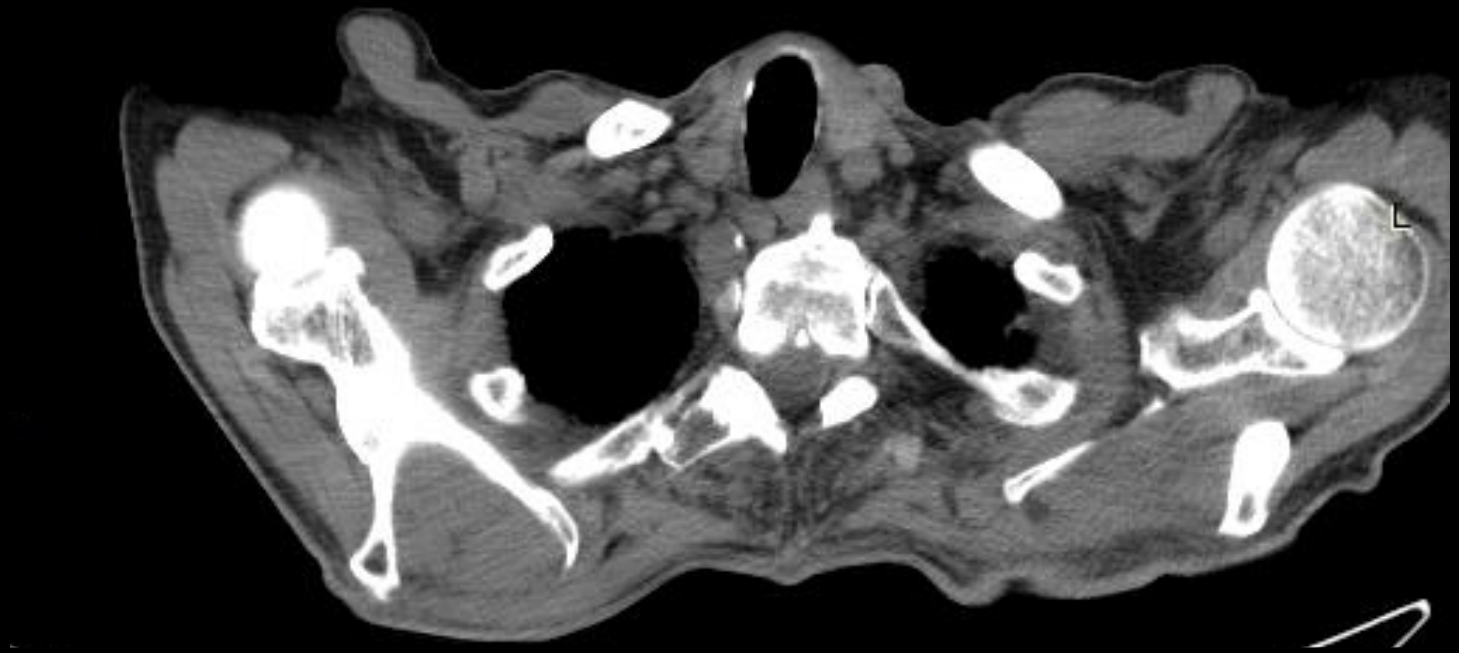
L

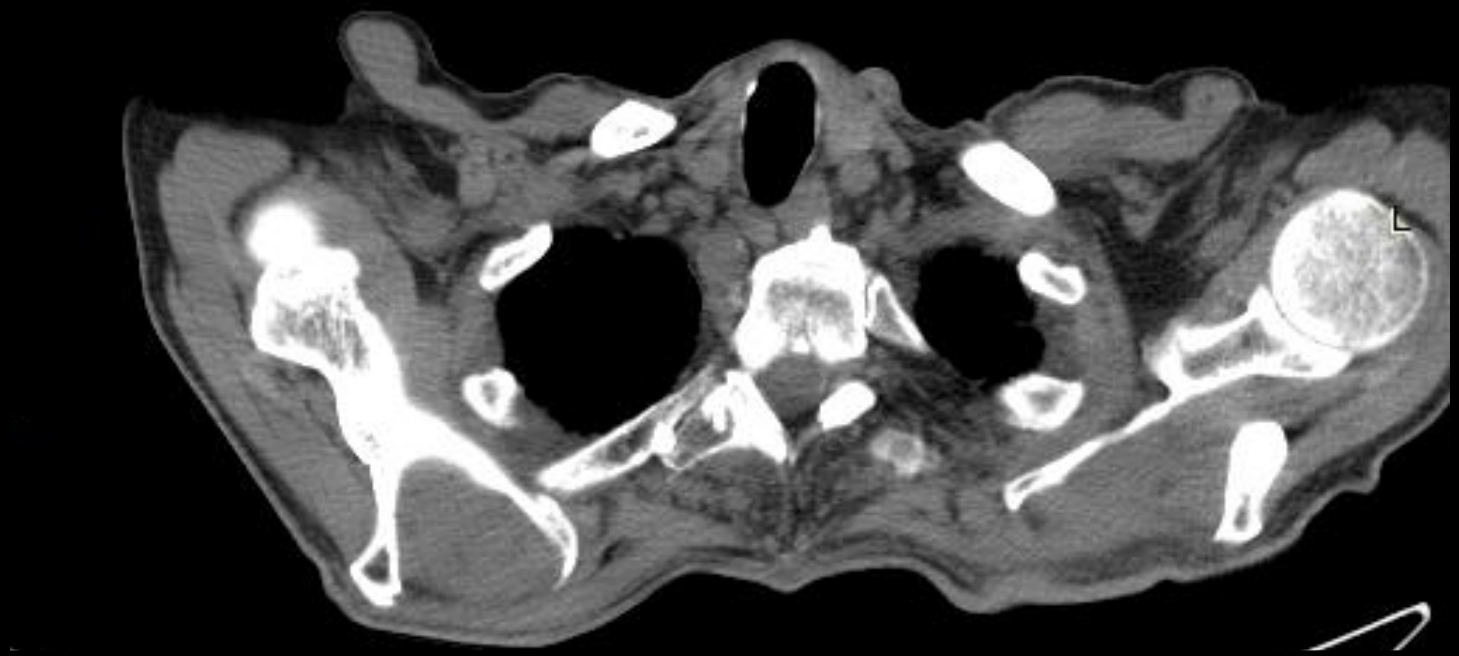
L

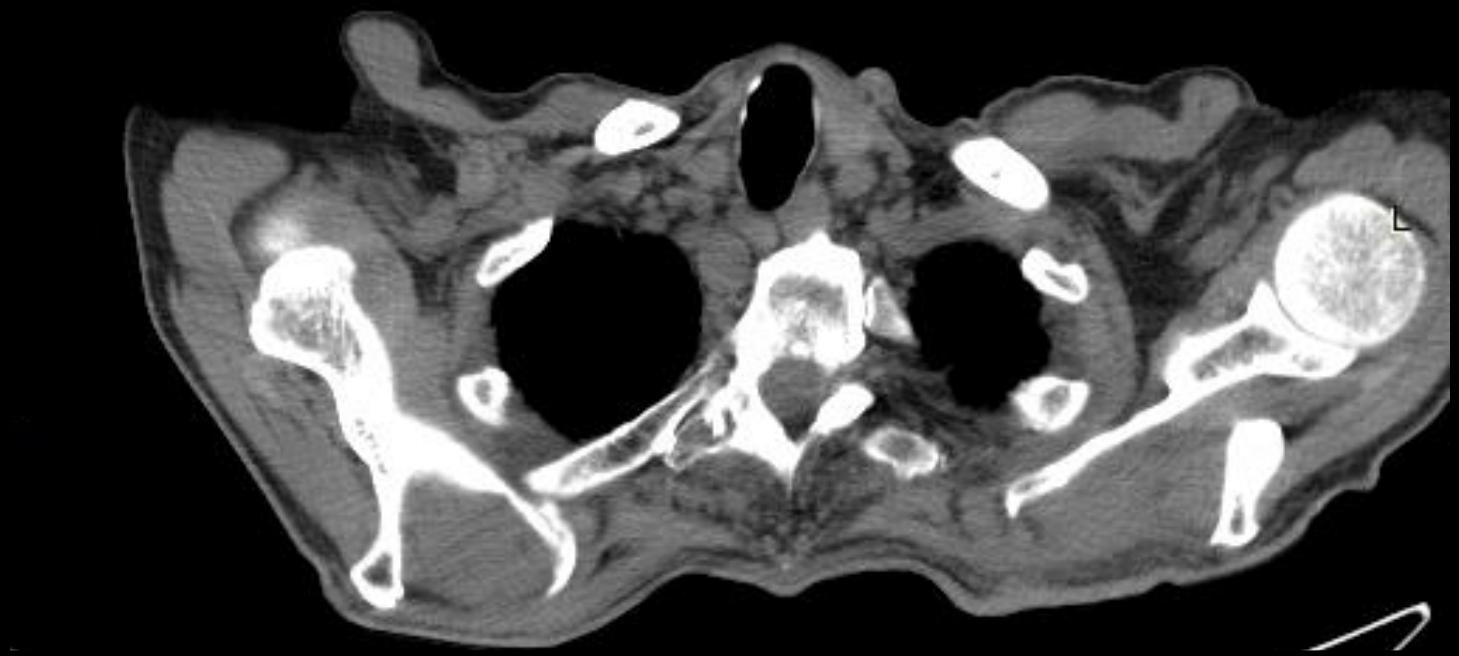
L

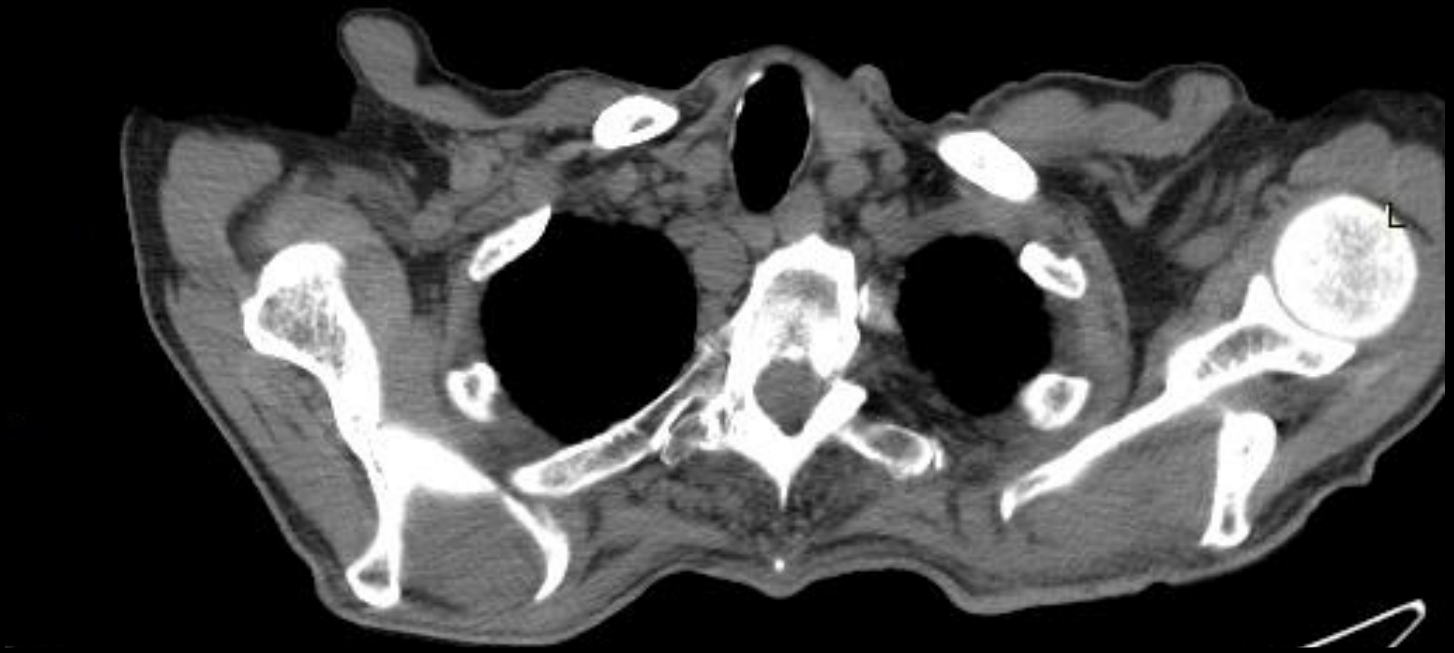
L

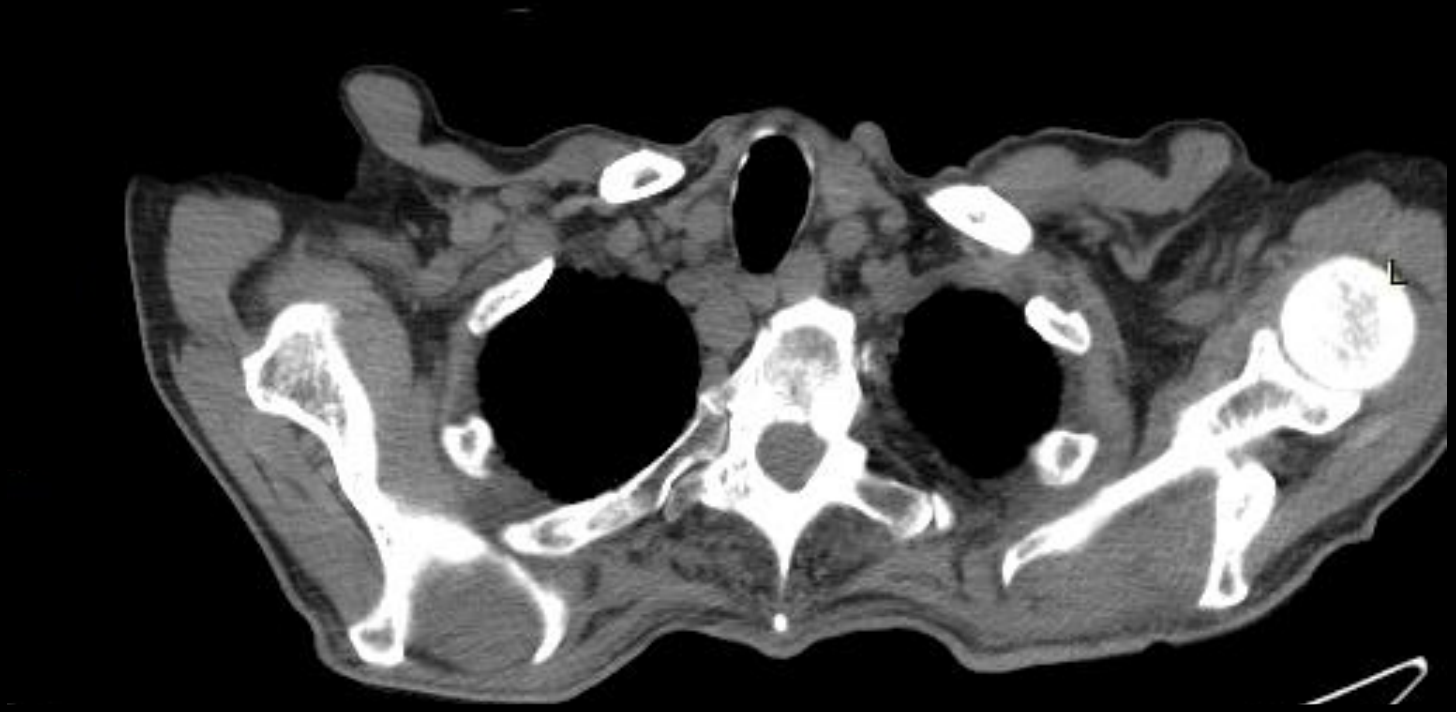
L

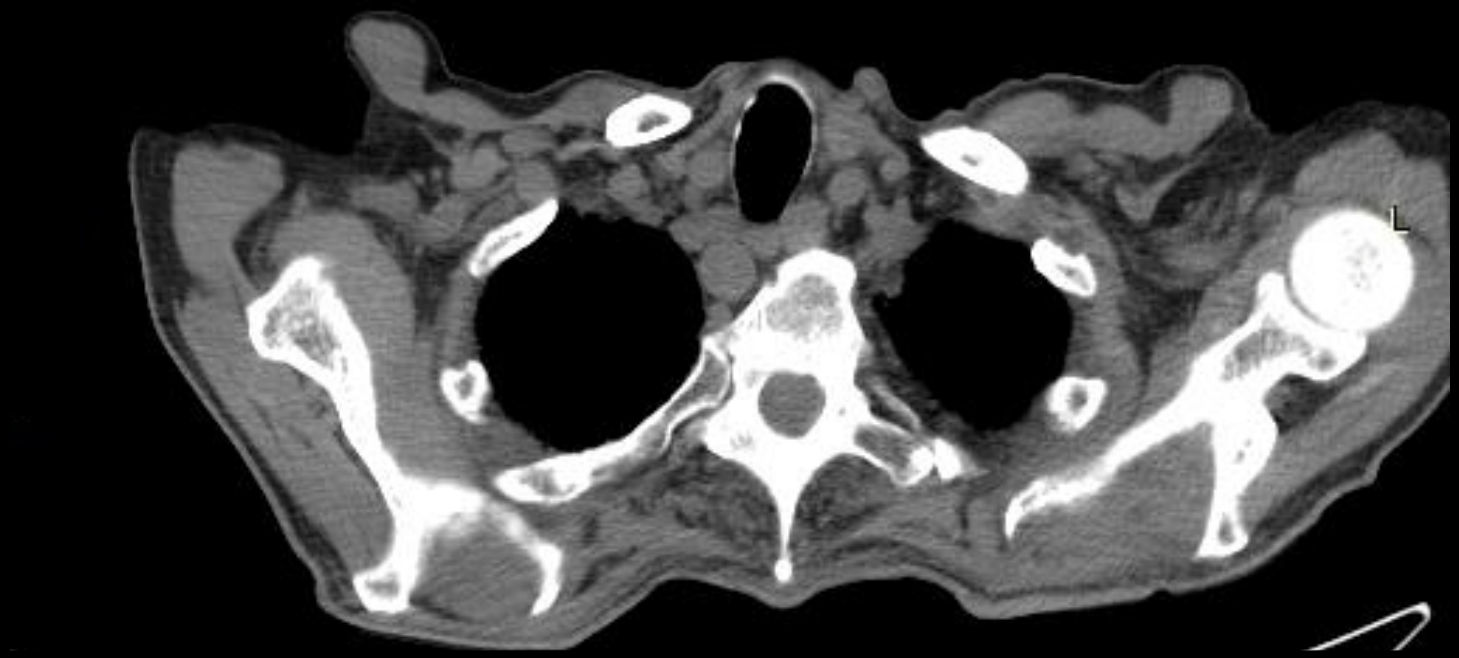
L

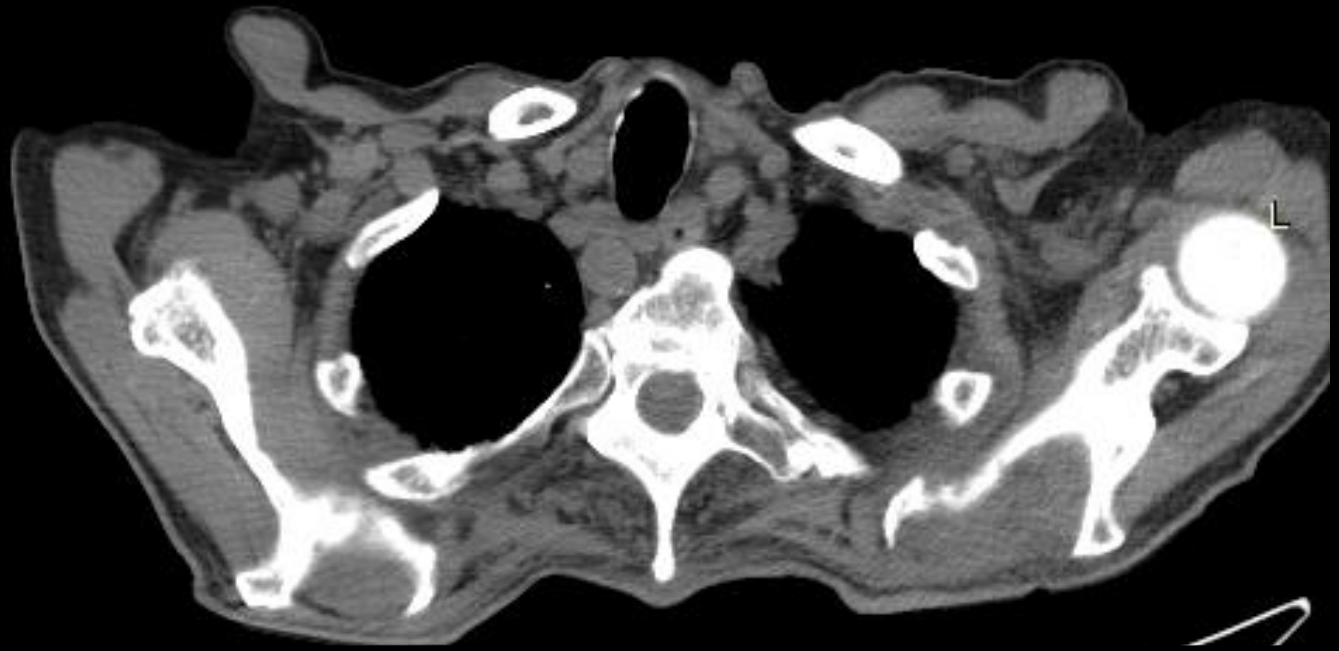
L

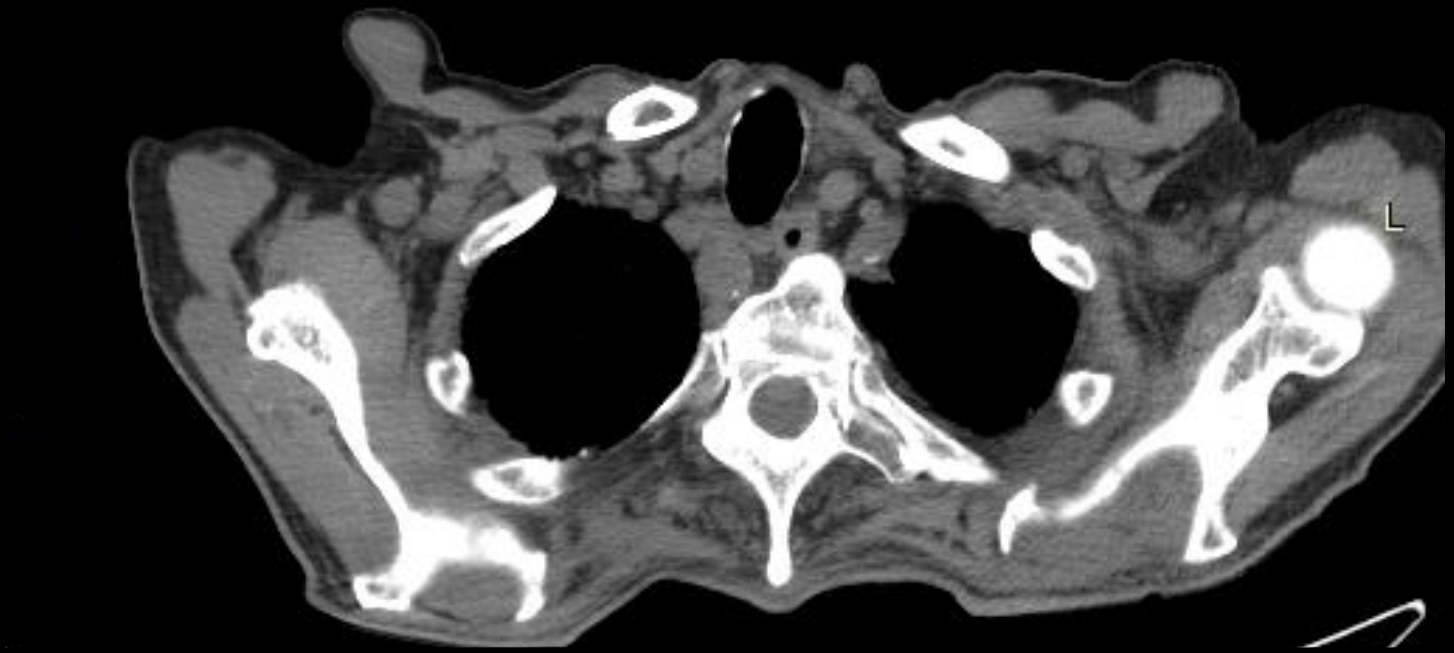
L

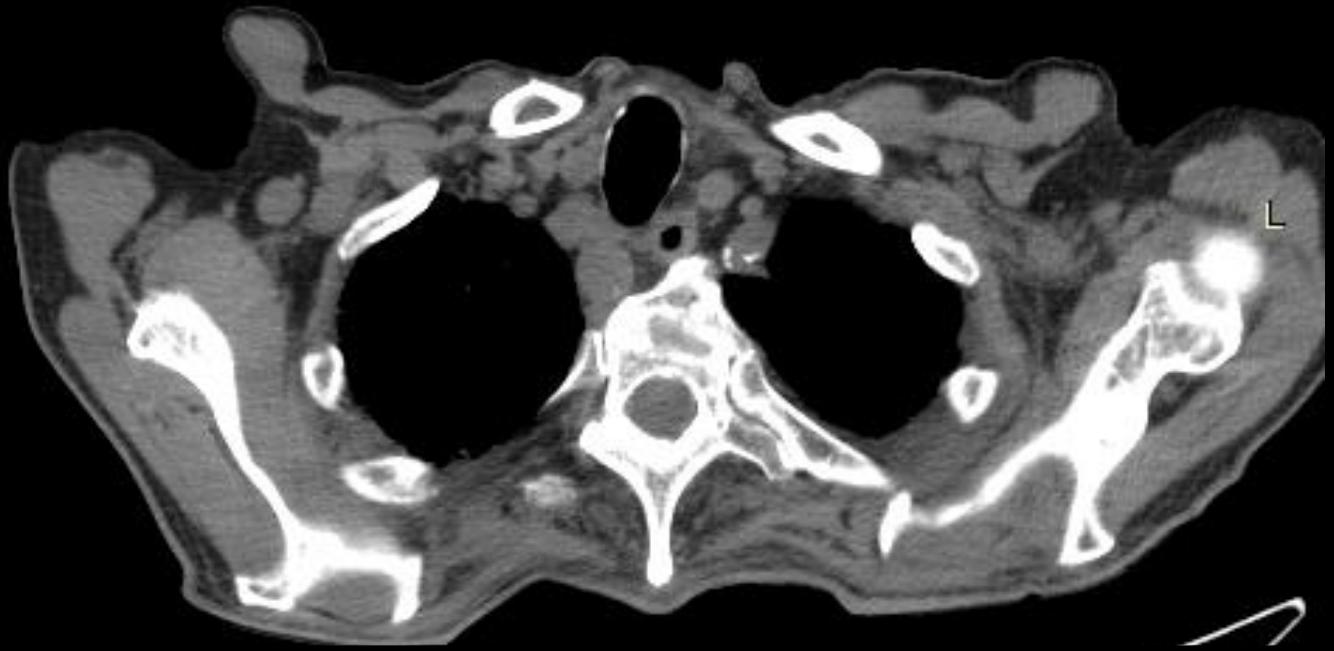
L

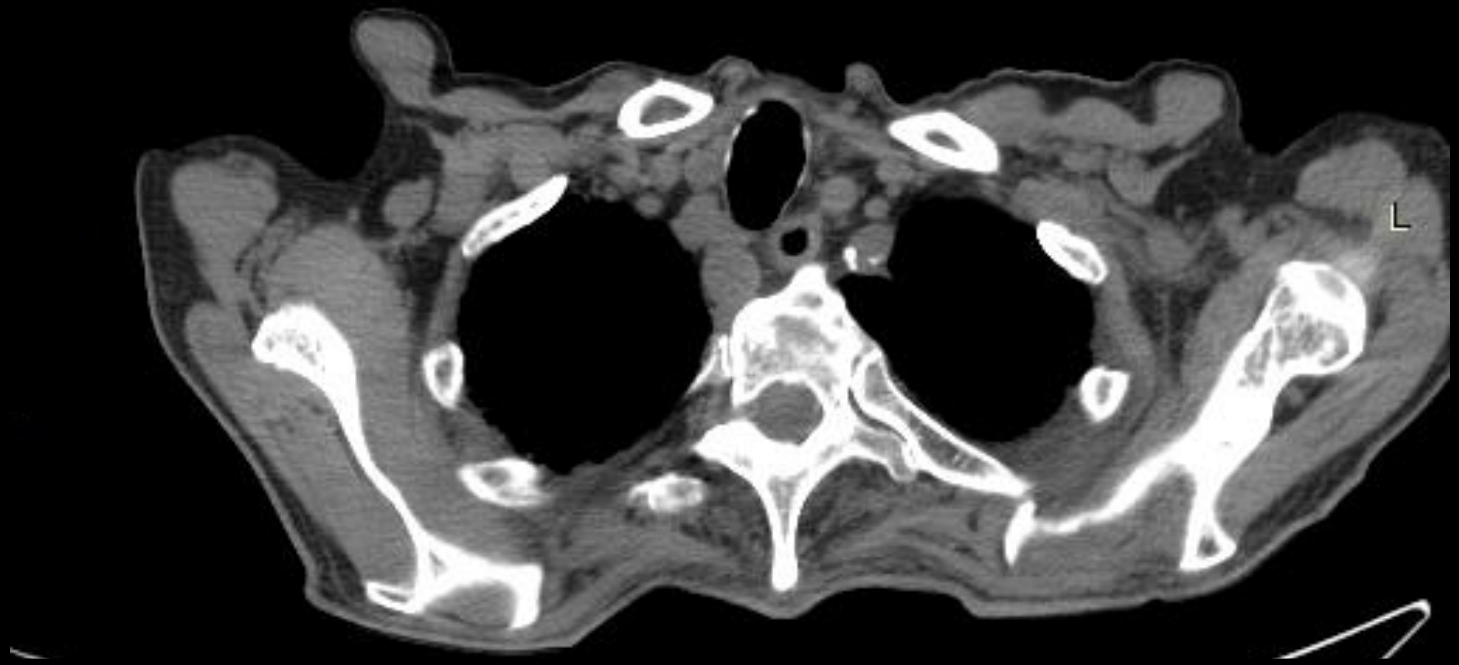
L

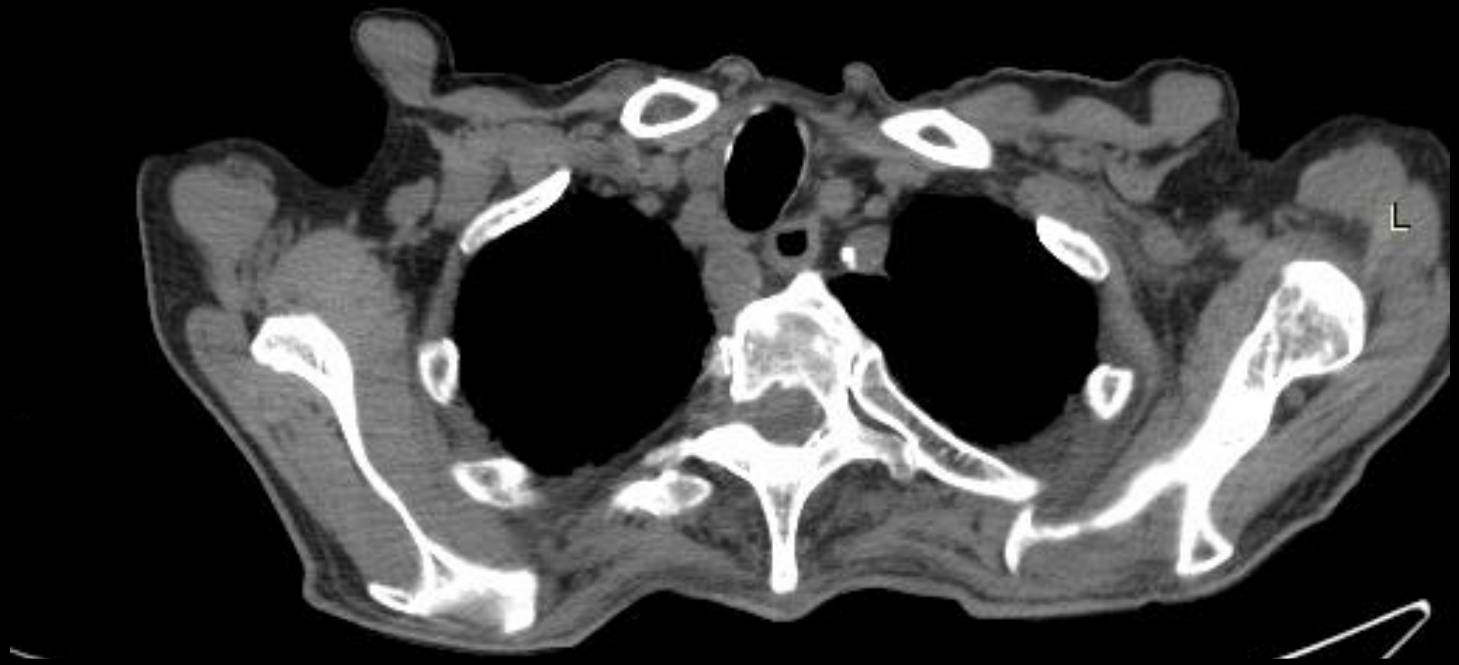
L

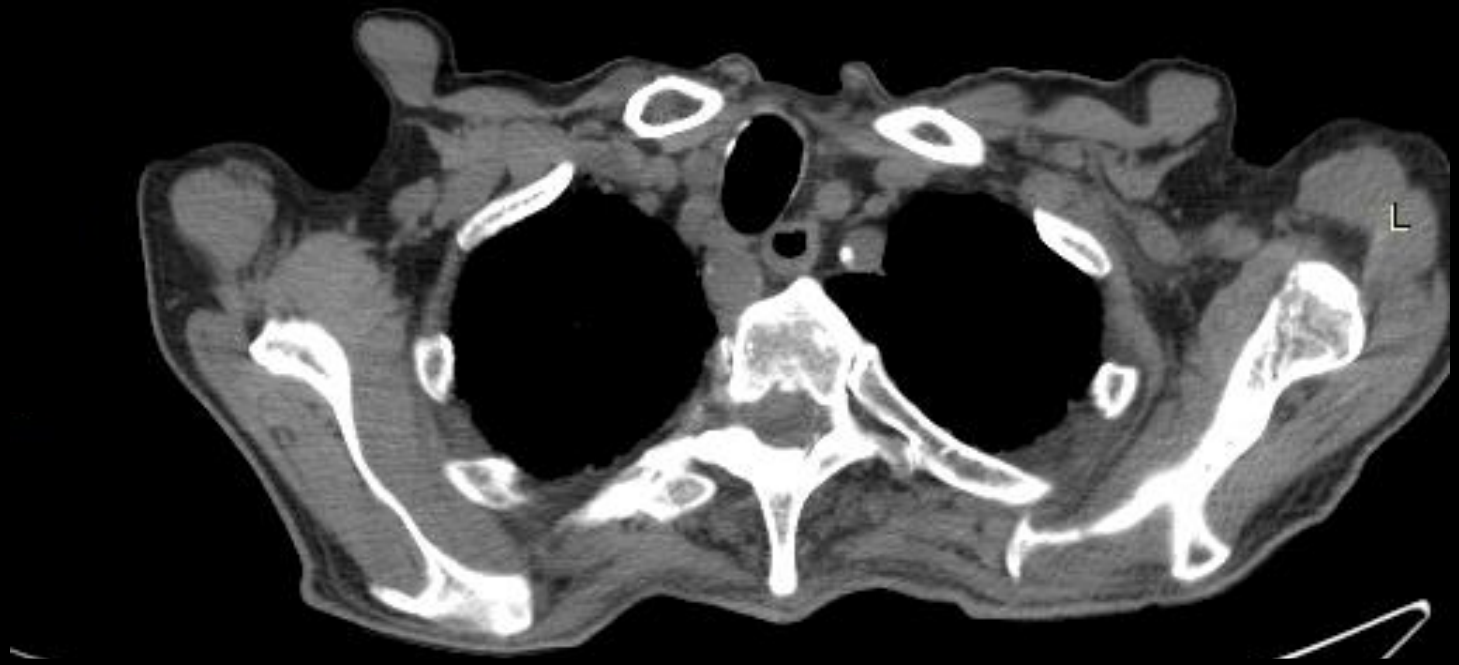
L

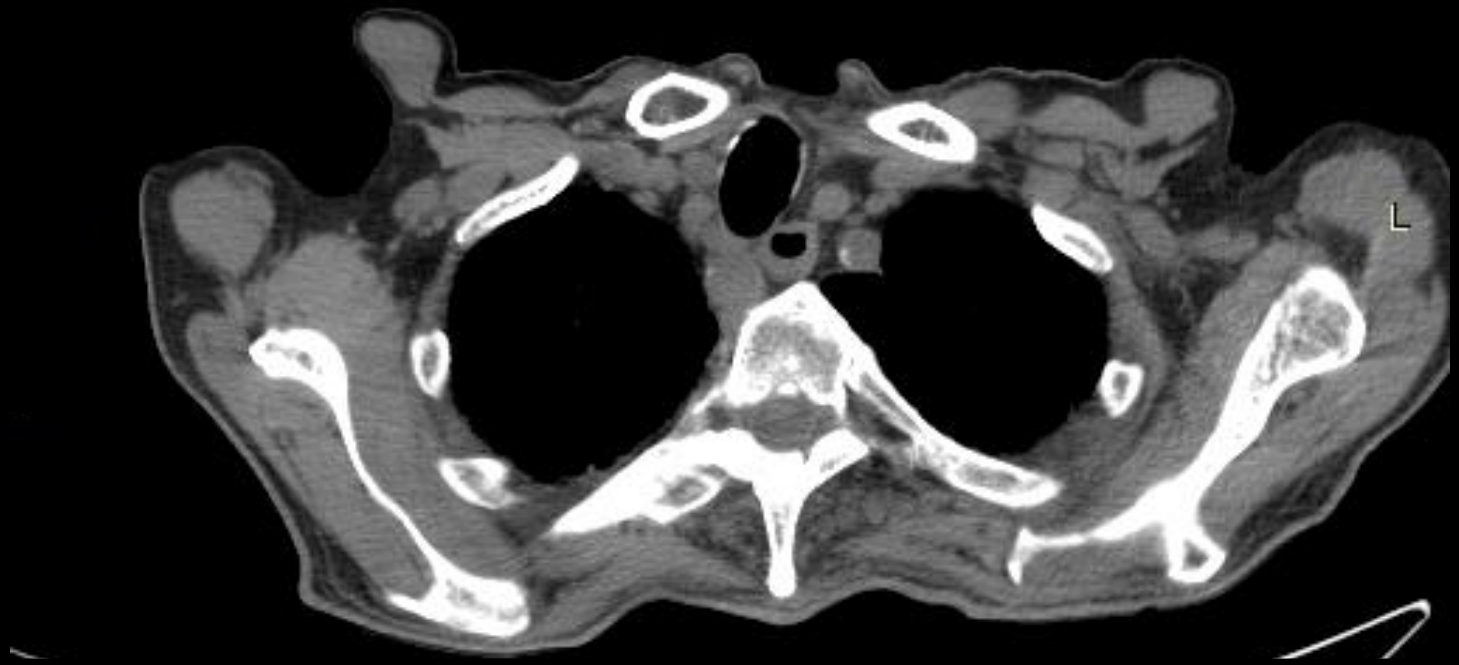
L

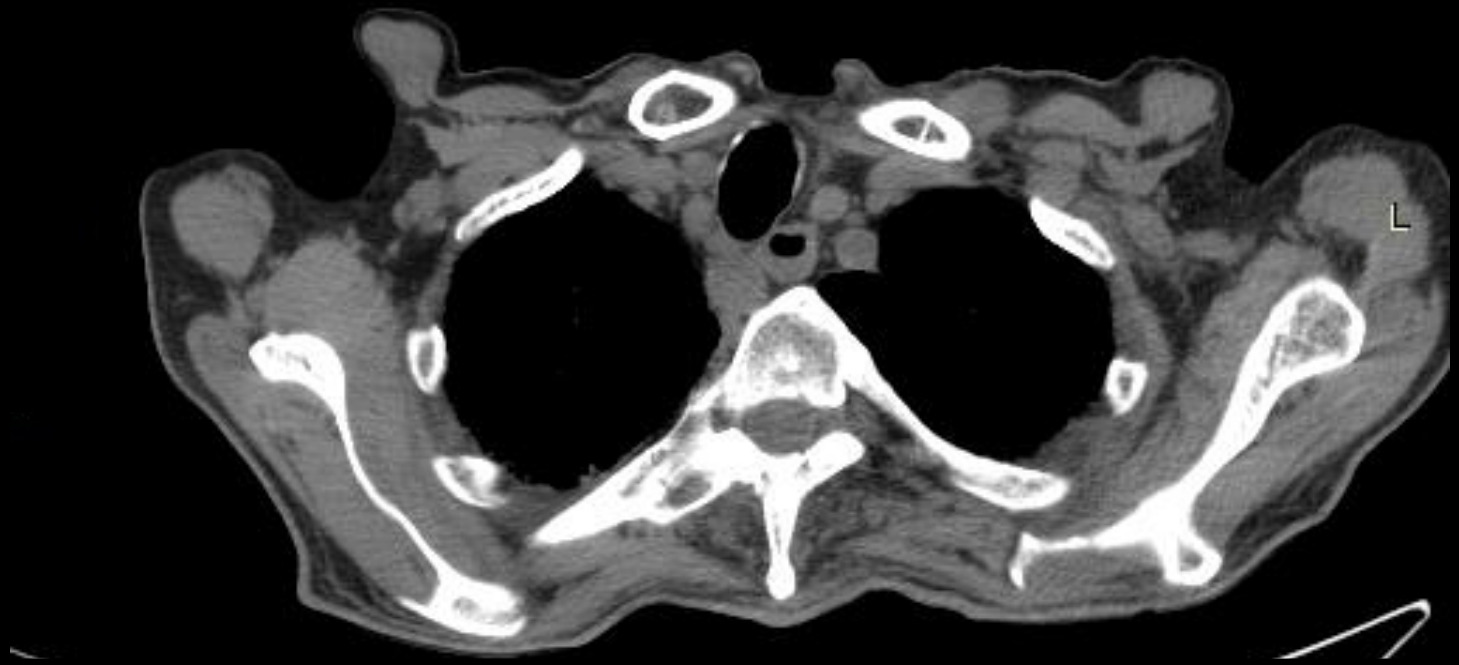
L

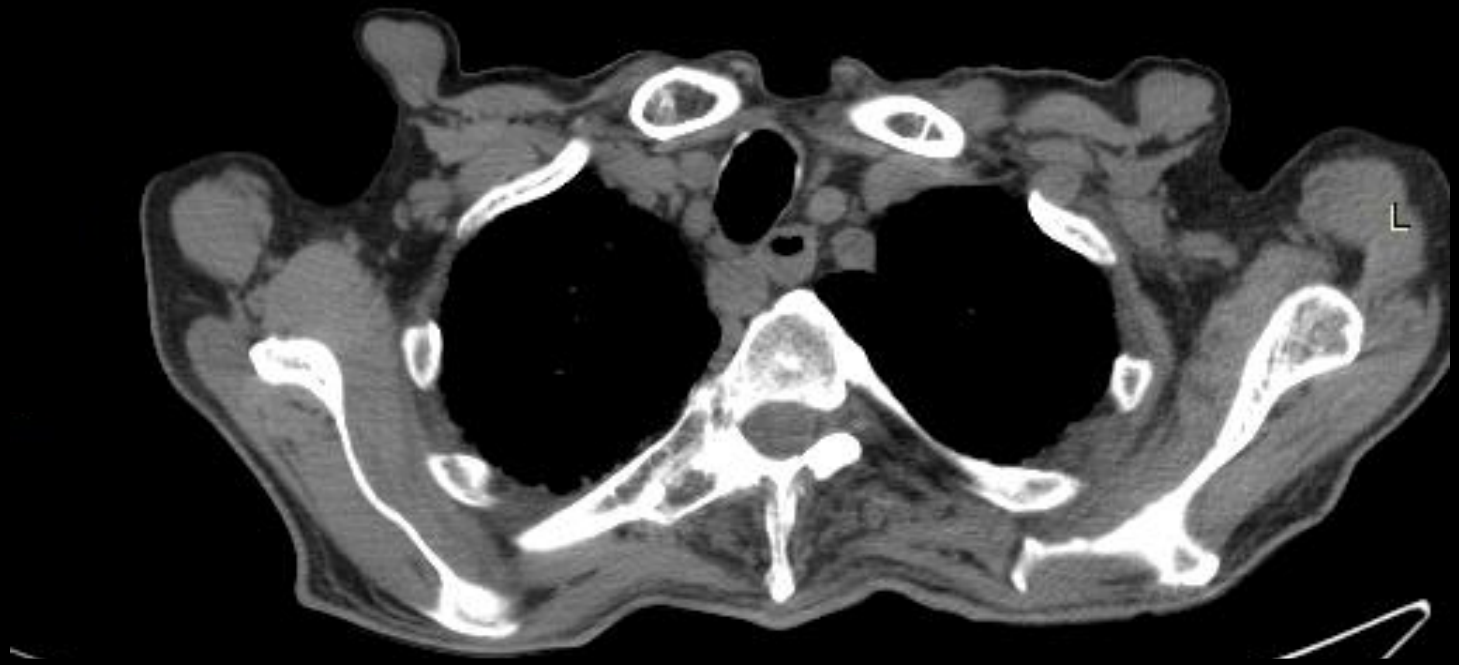
L

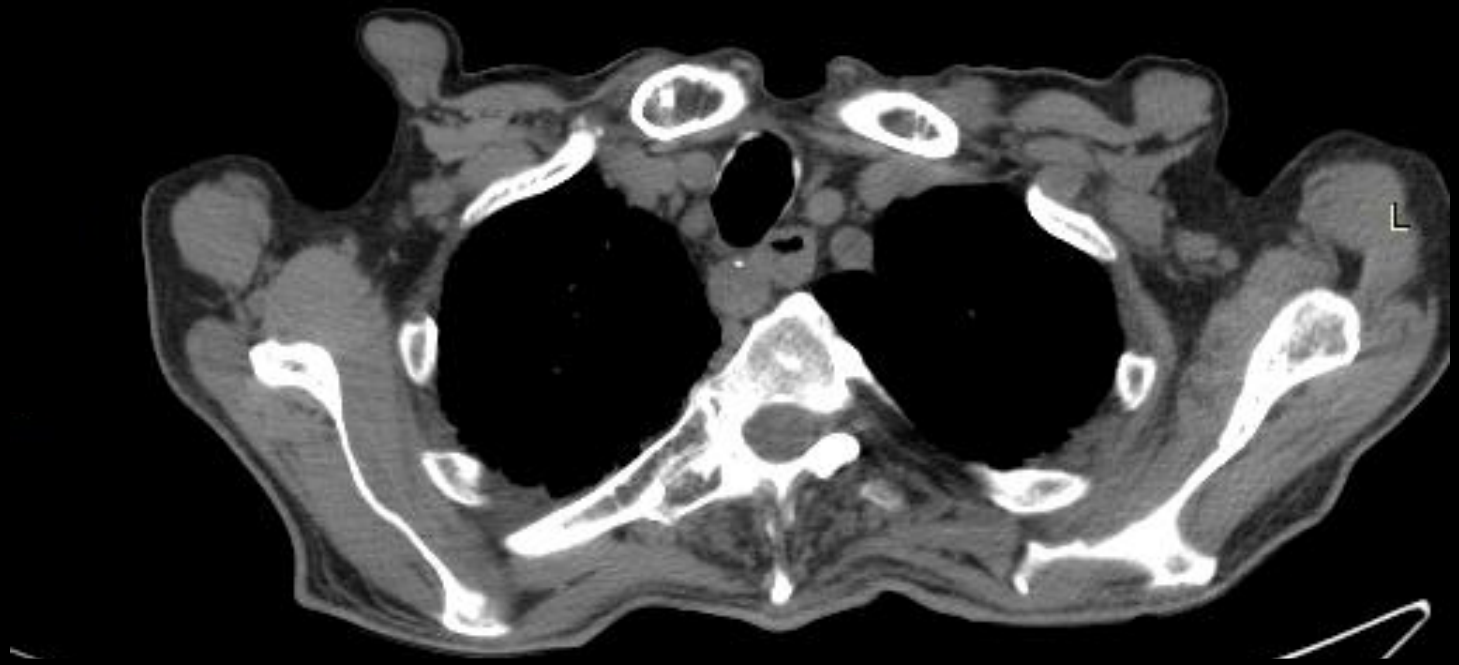
L

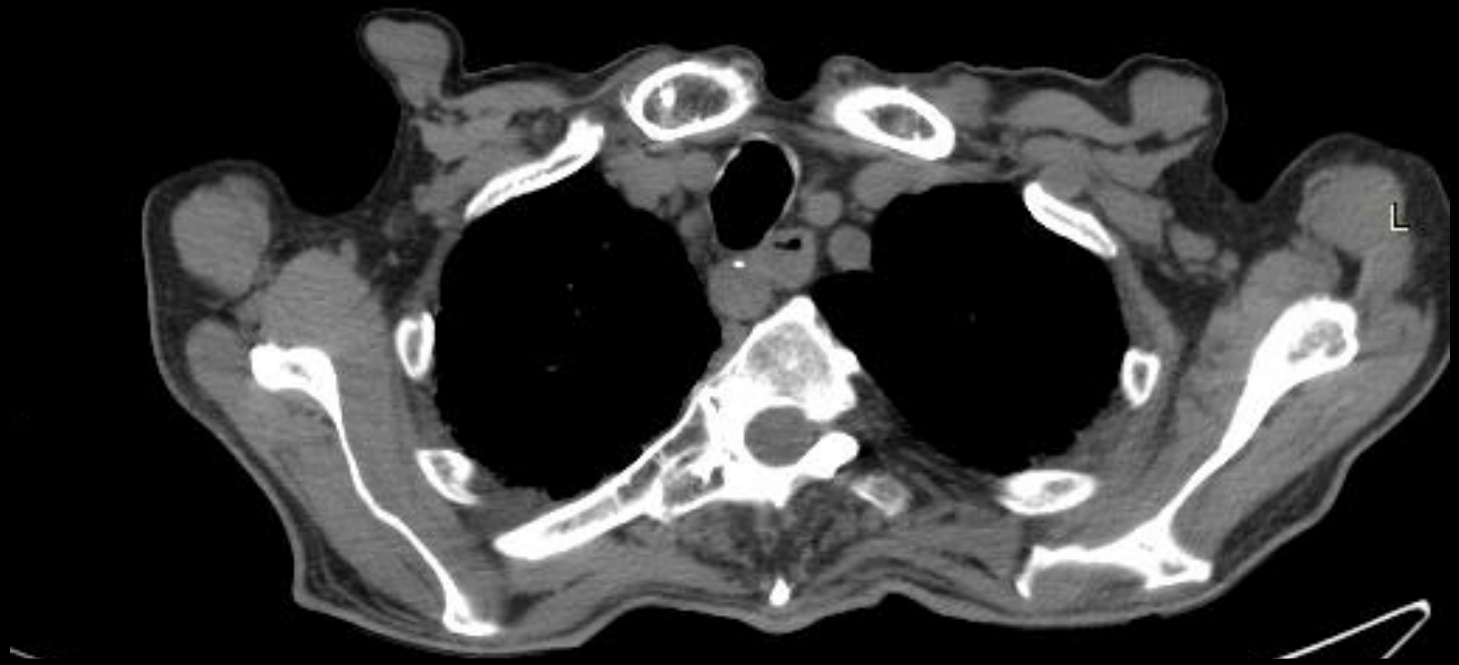
L

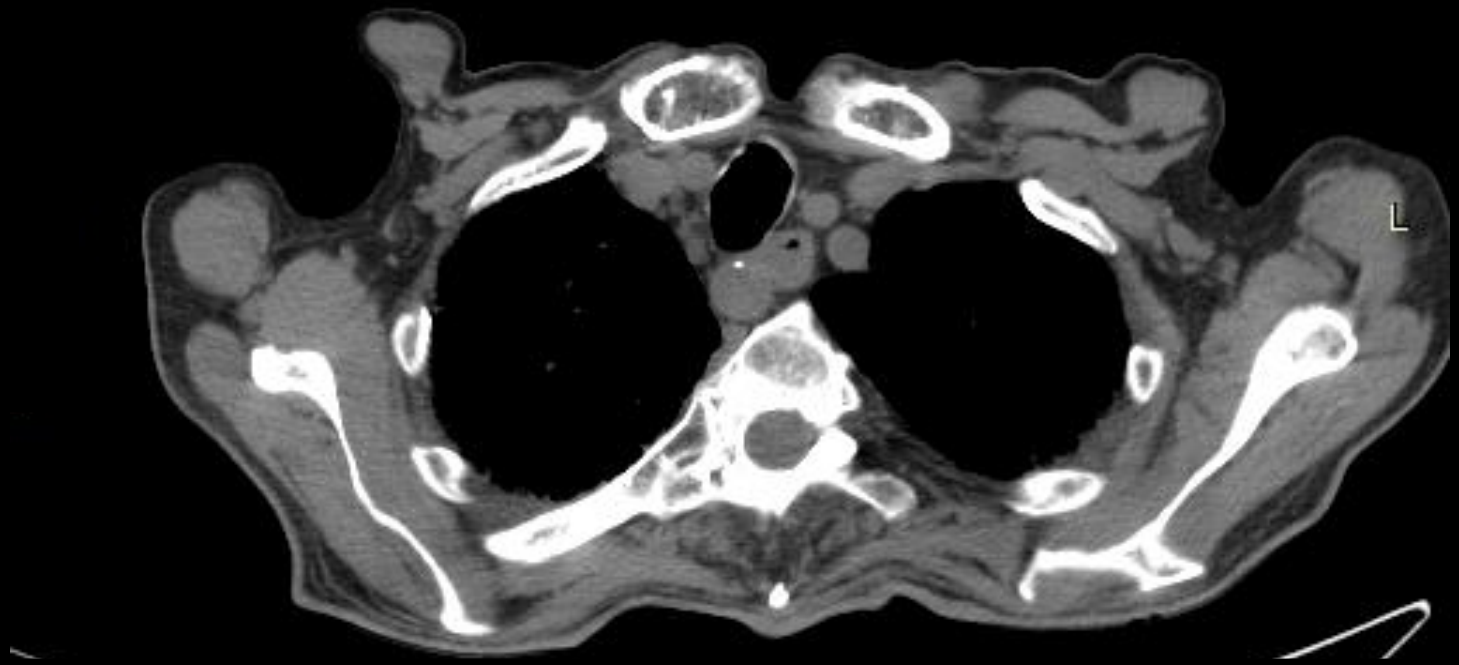
L

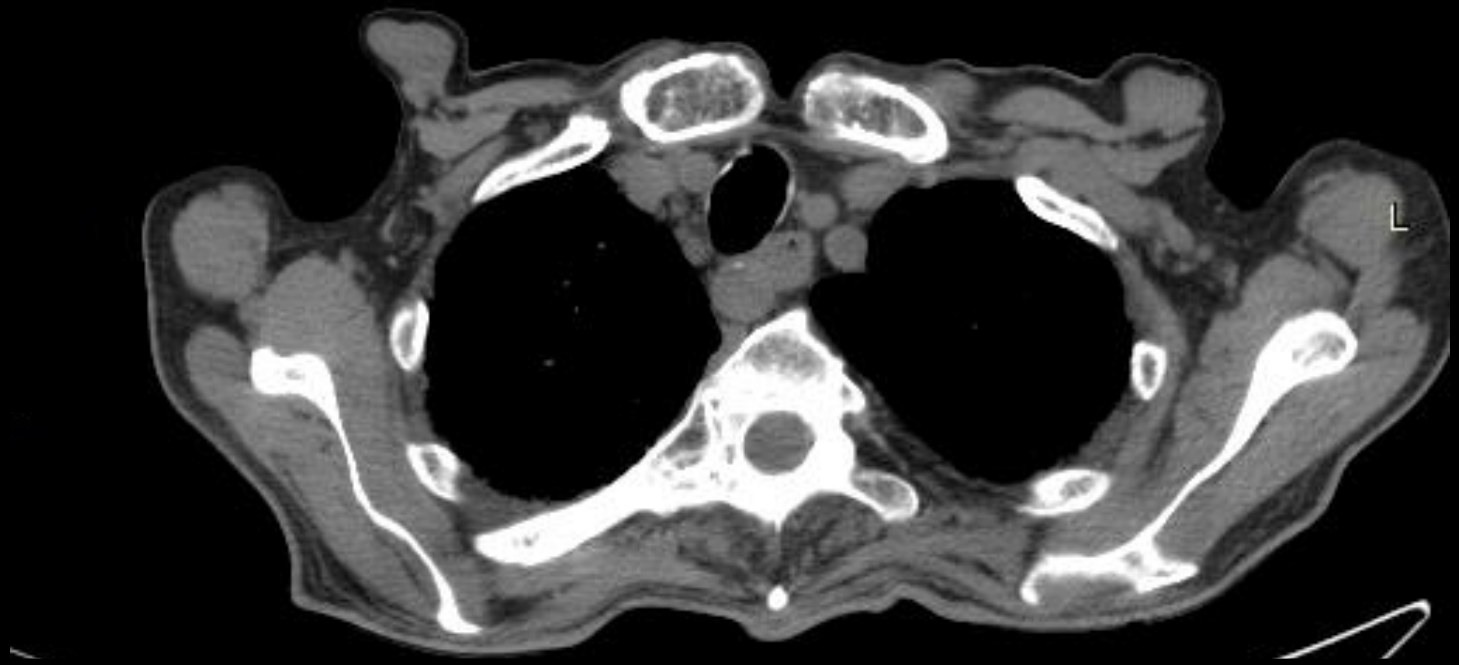
L

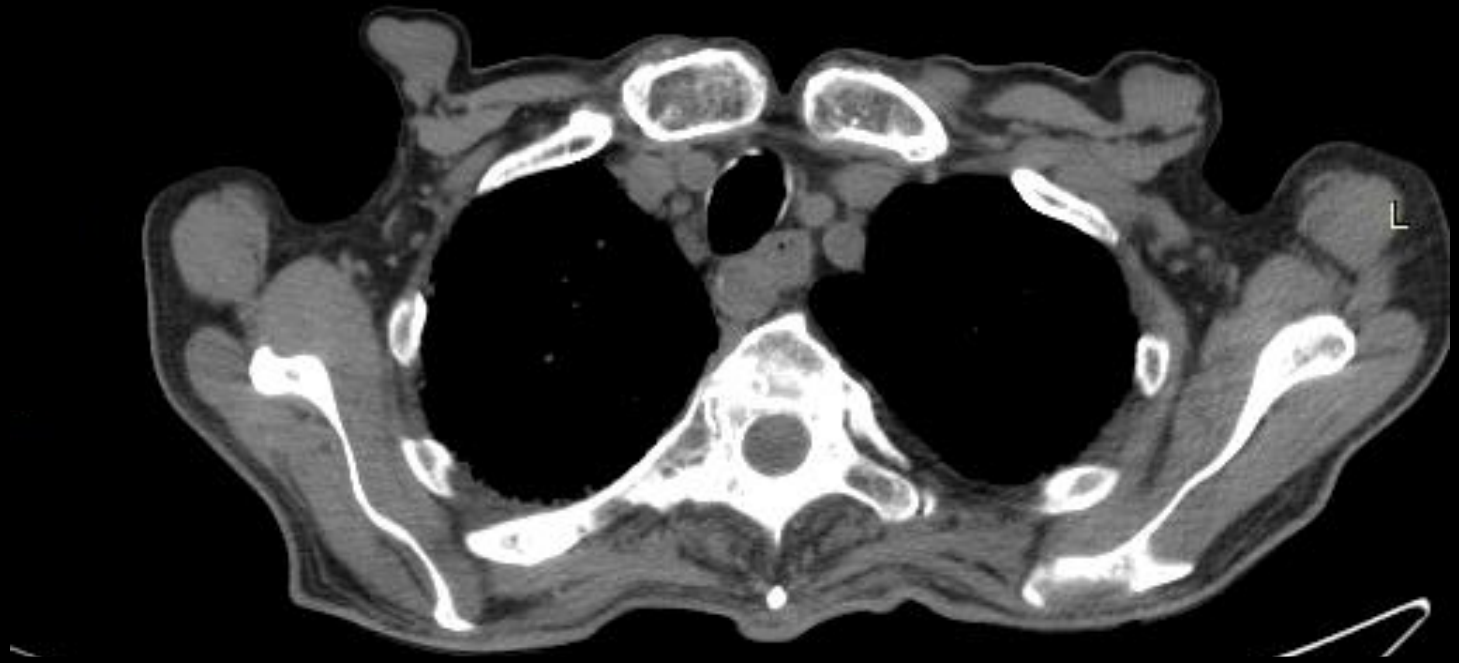
L

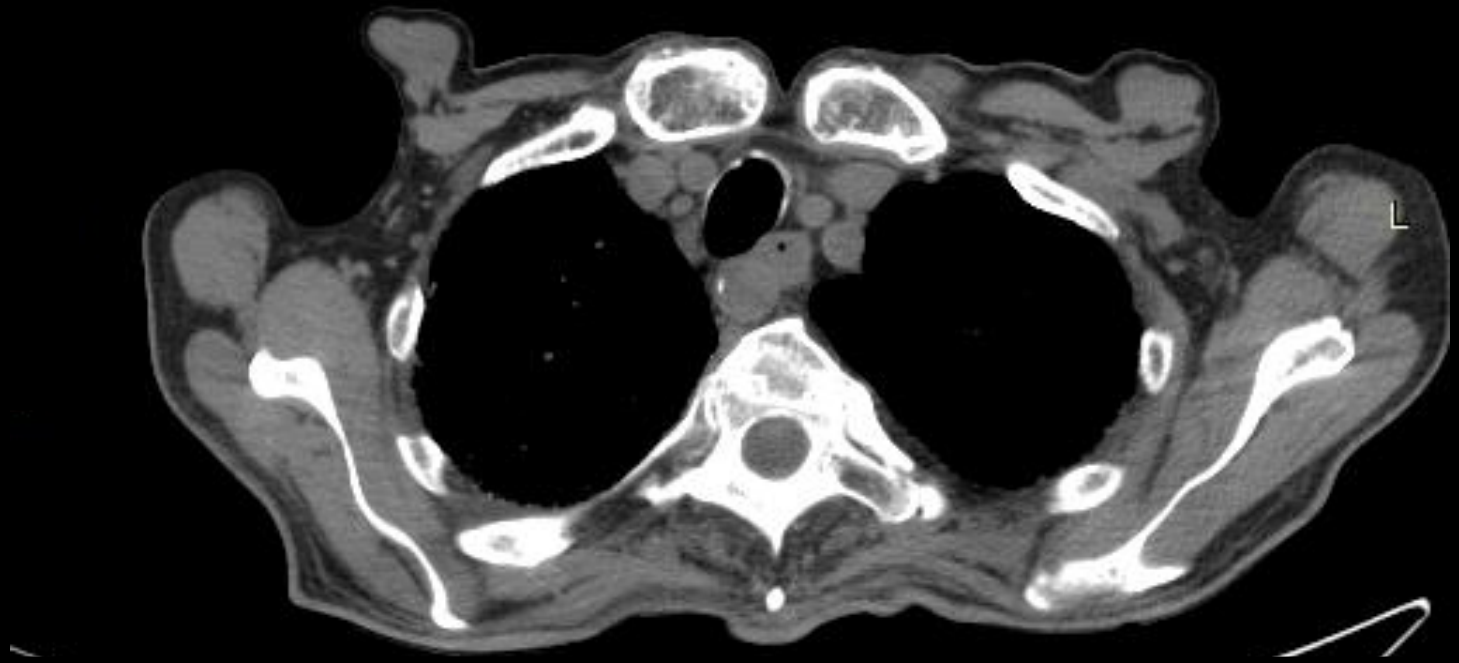
L

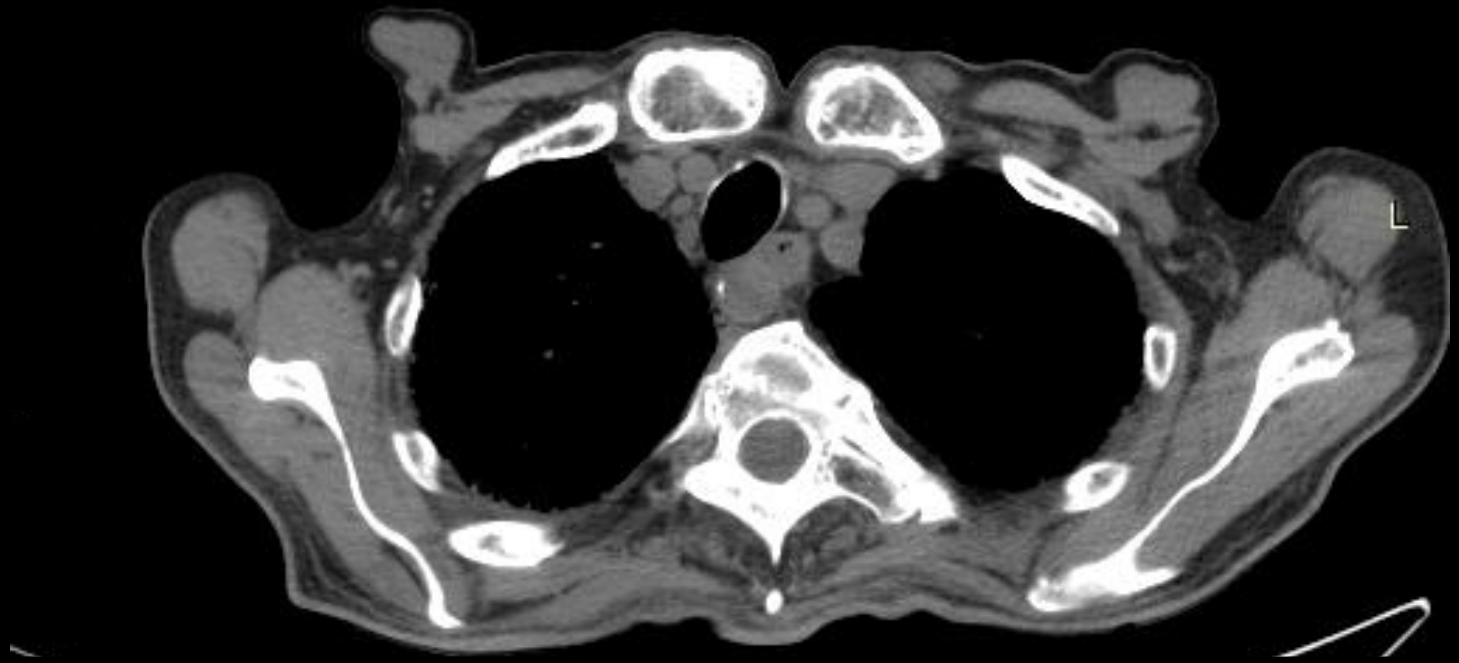
L

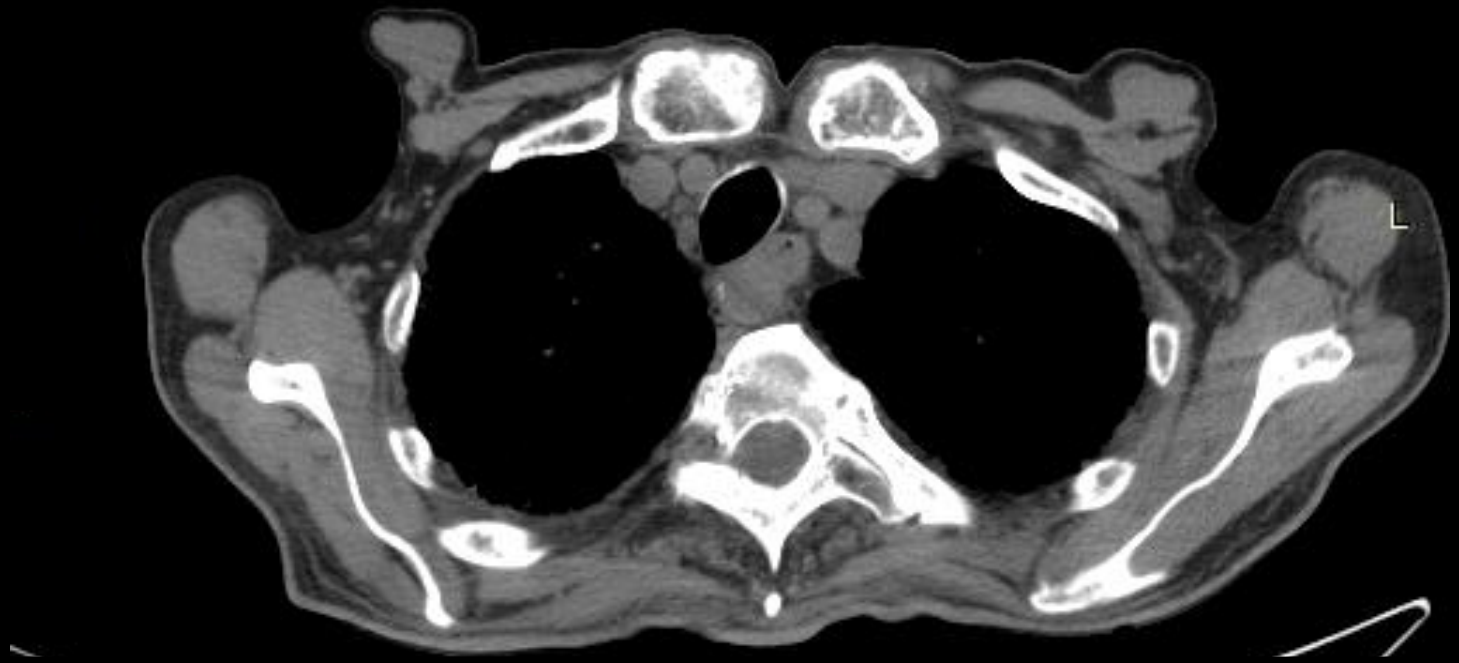
L

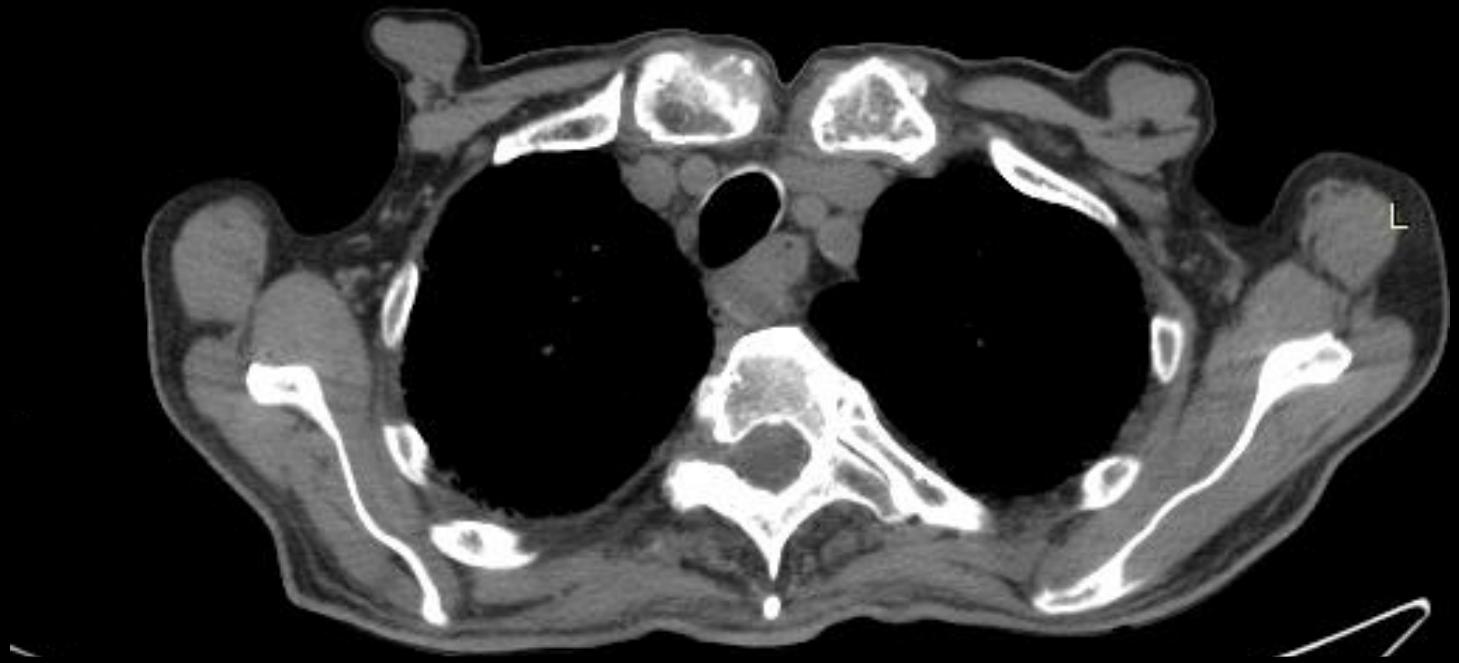
L

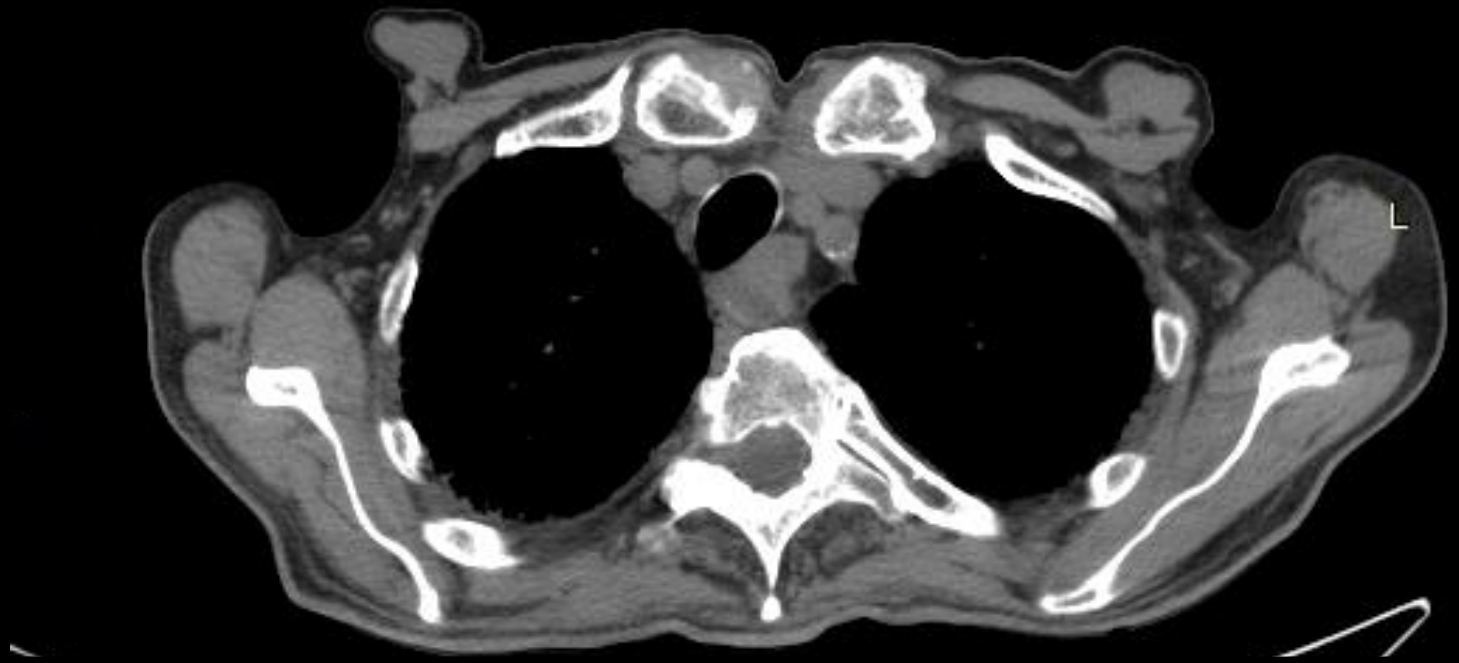
L

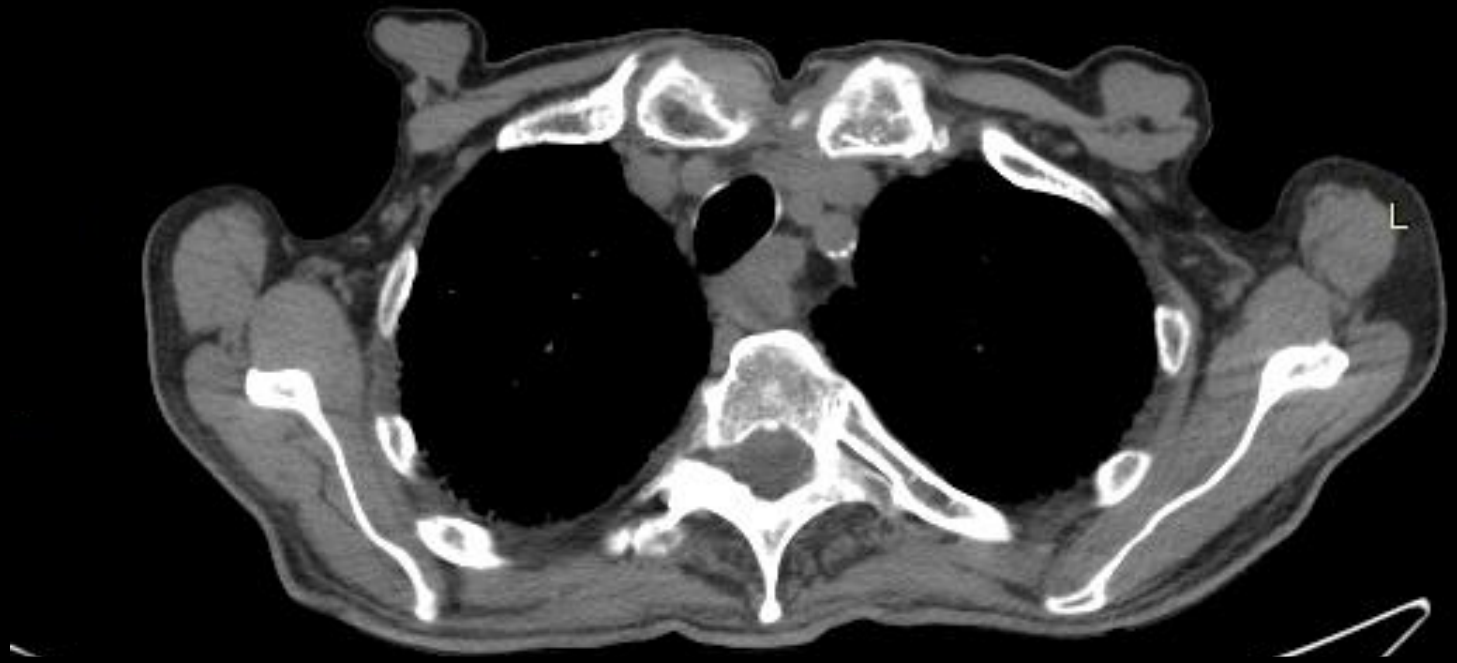
L

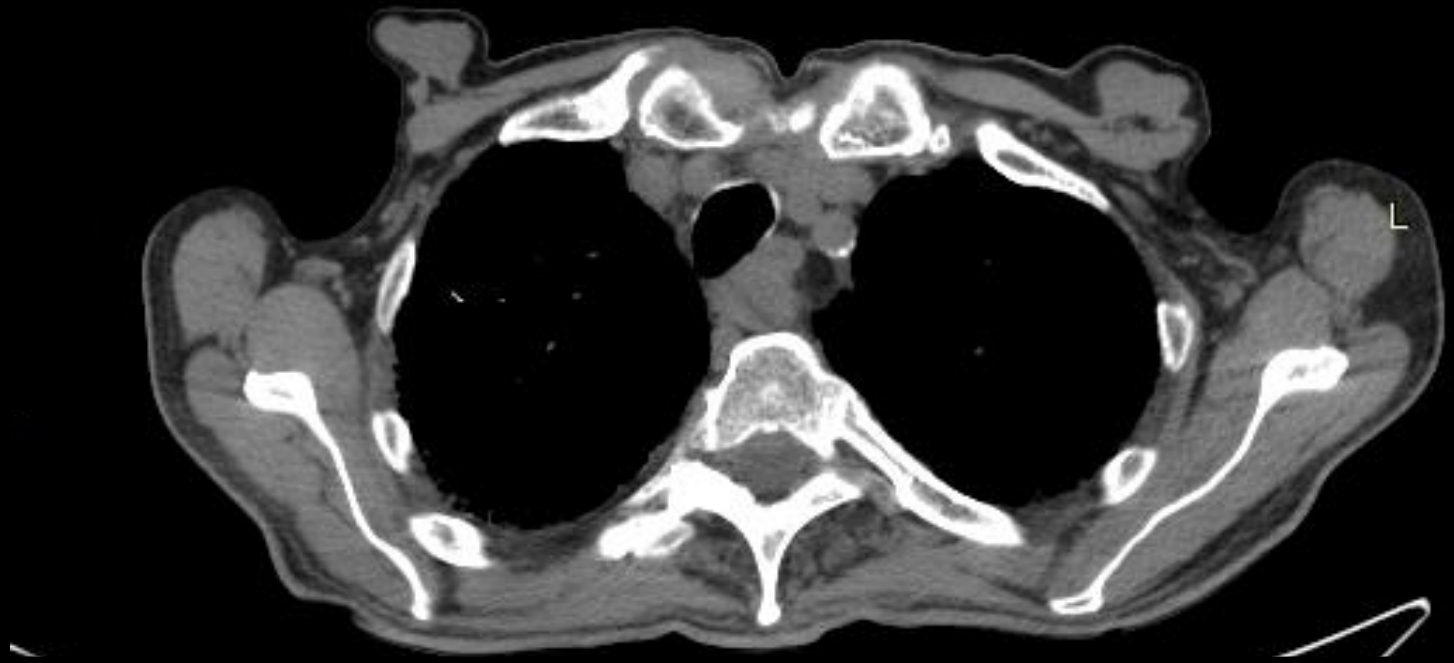
L

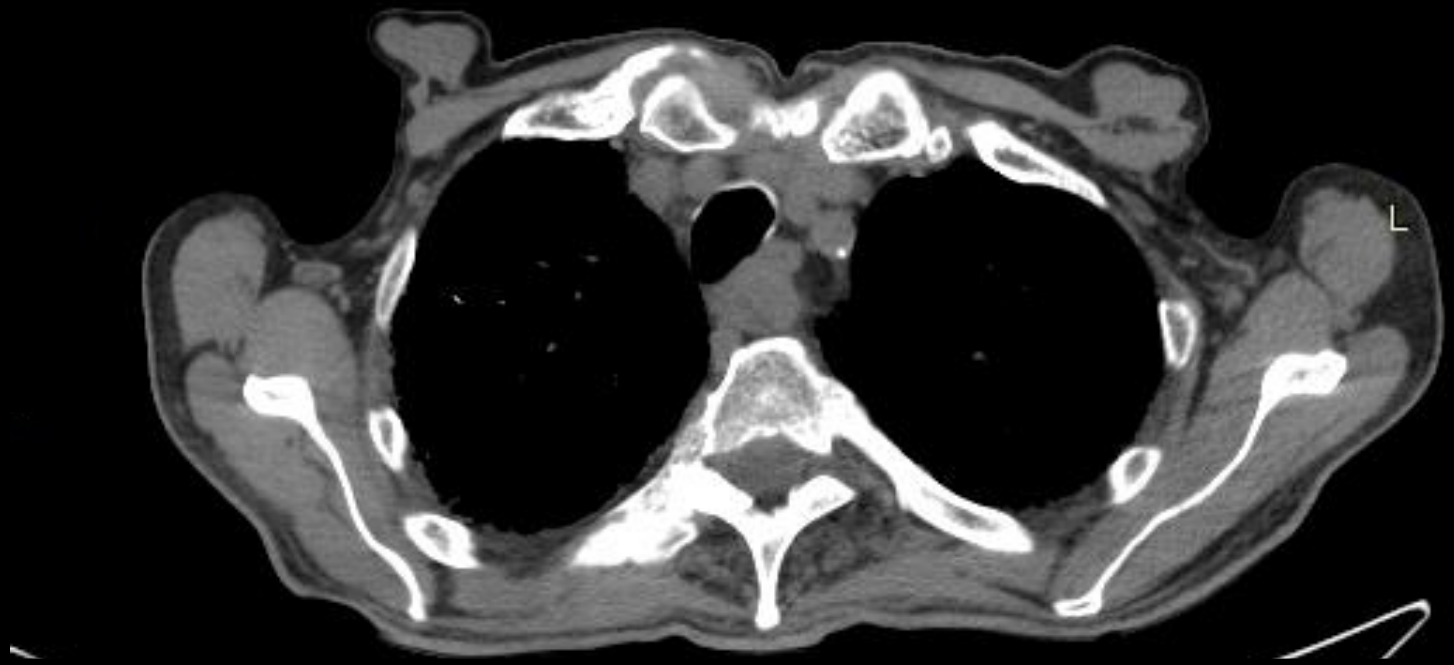
L

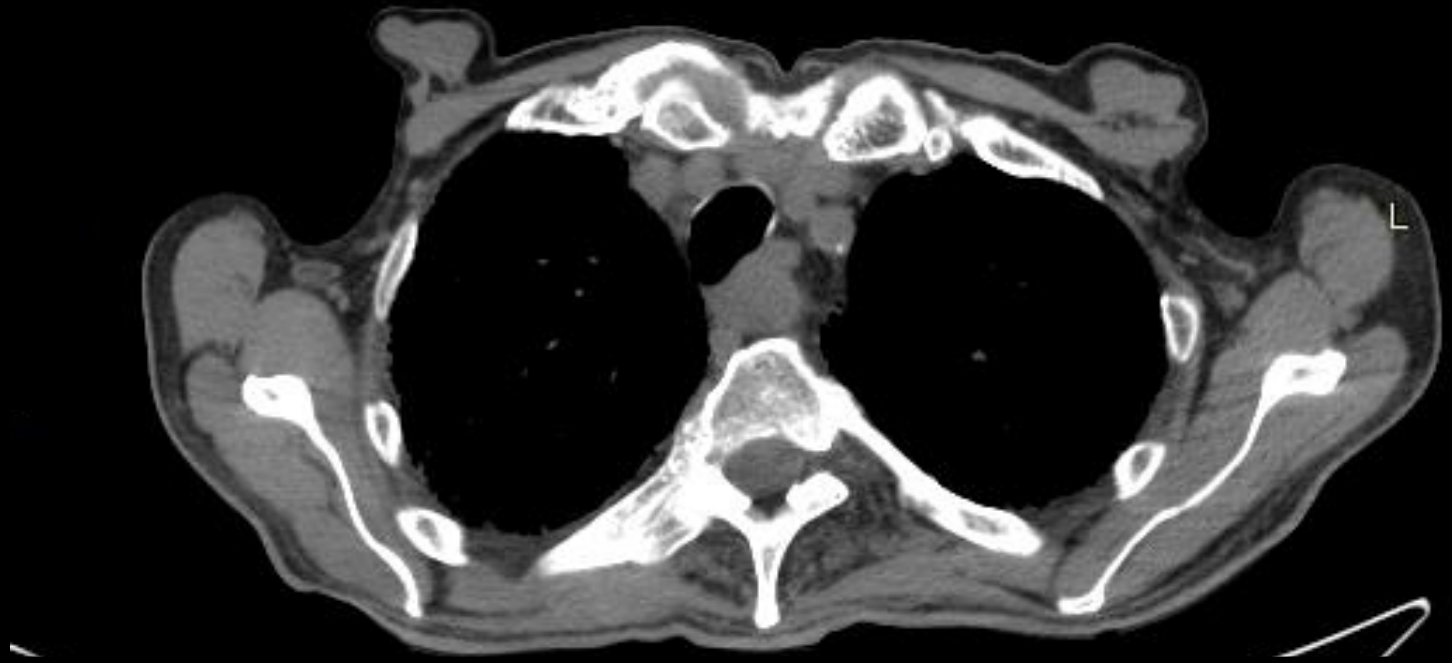
L

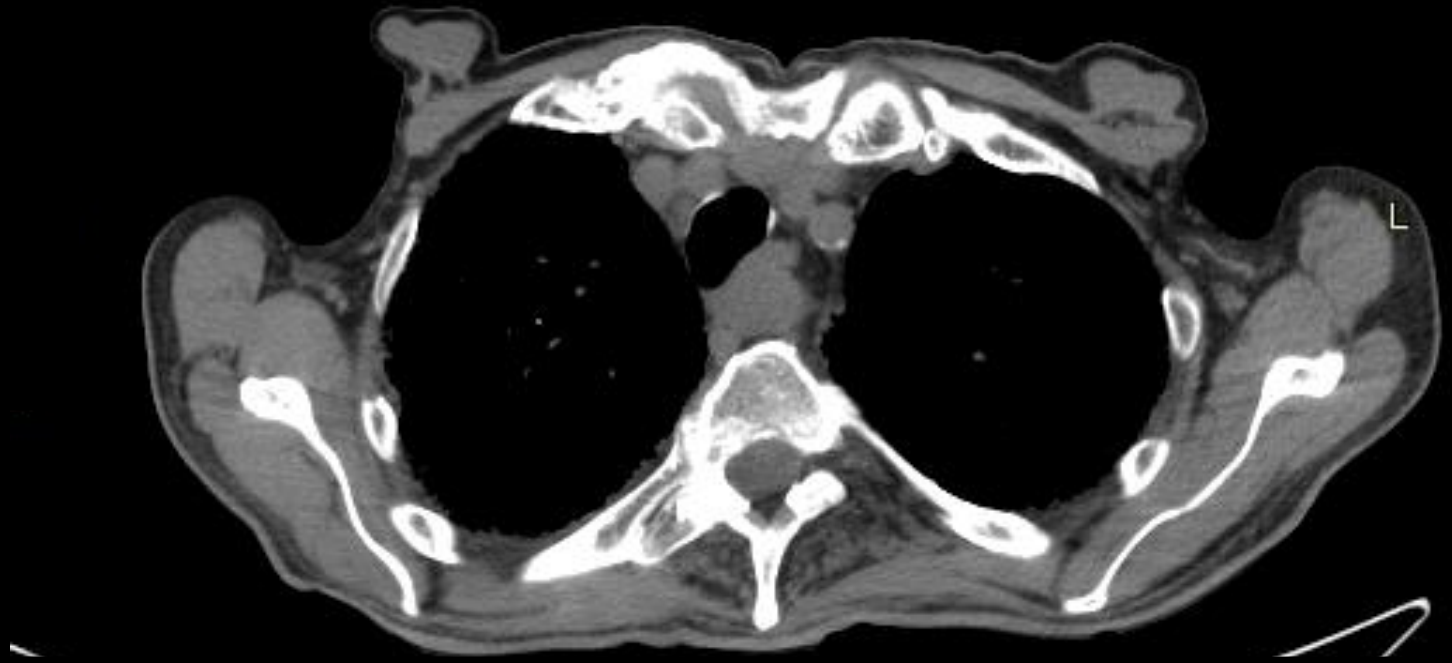
L

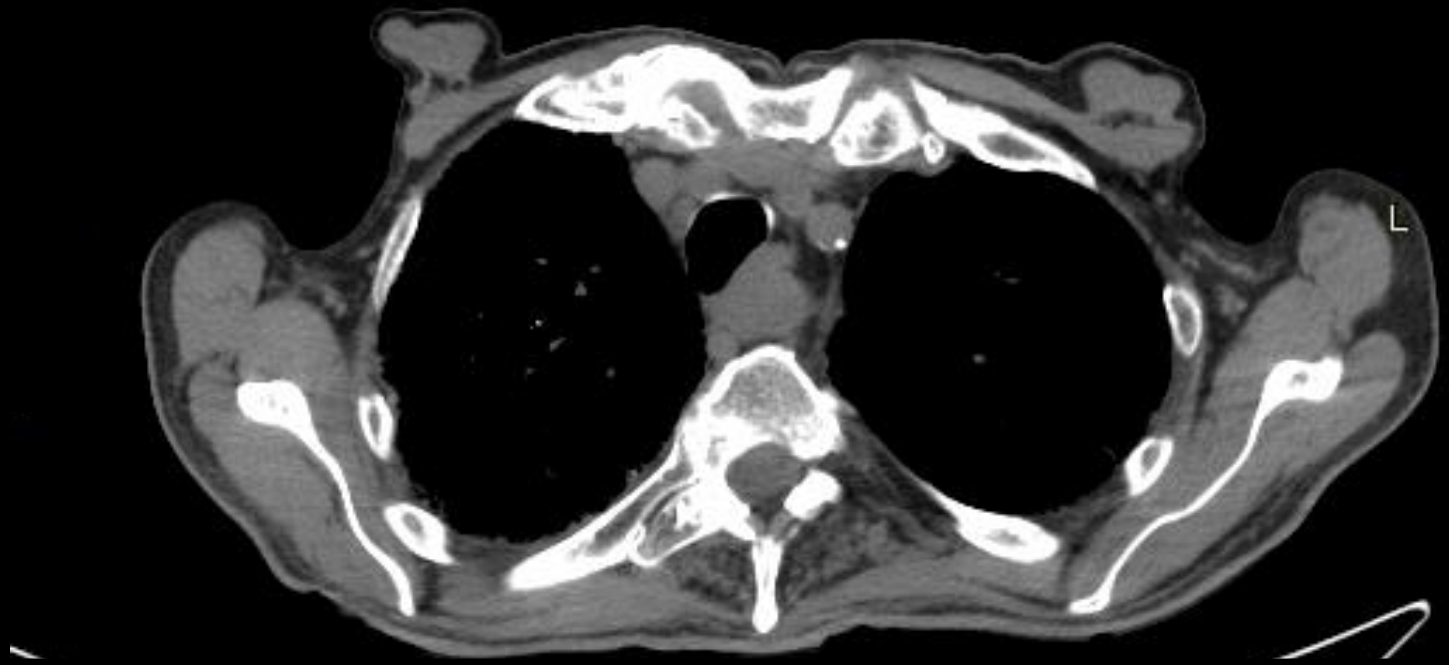
L

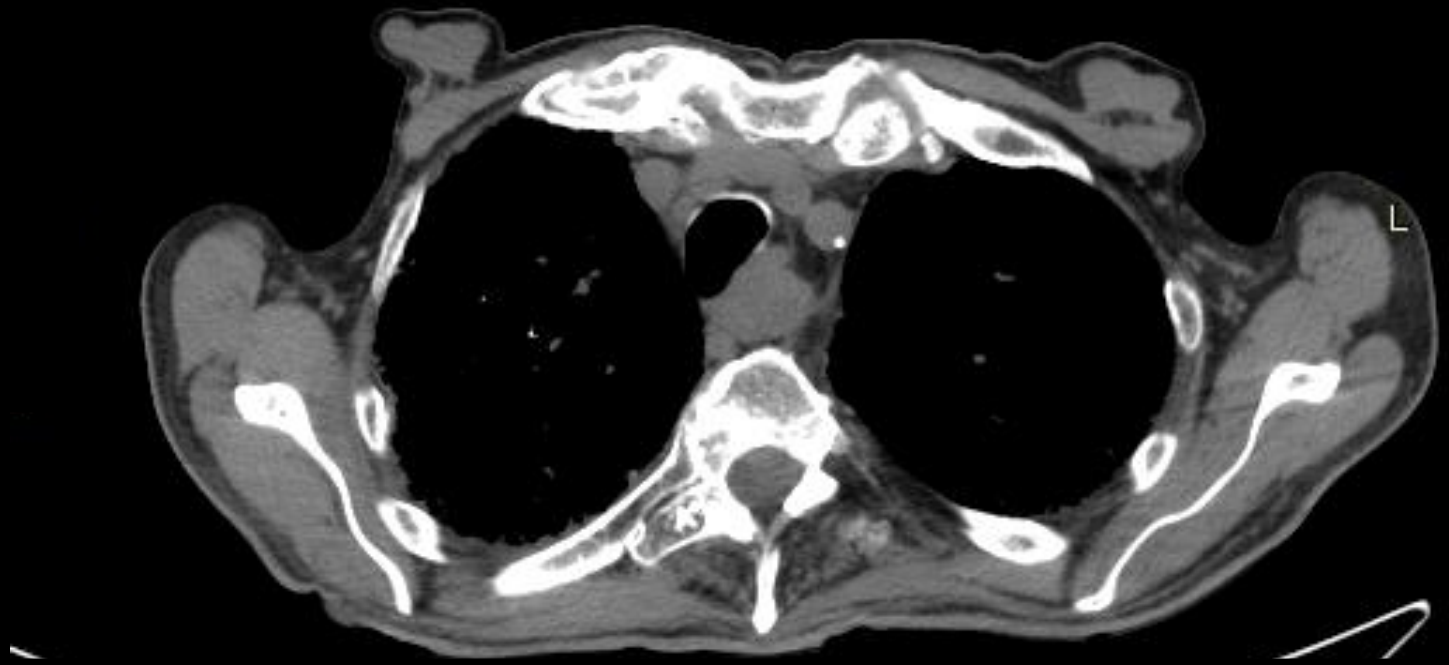
L

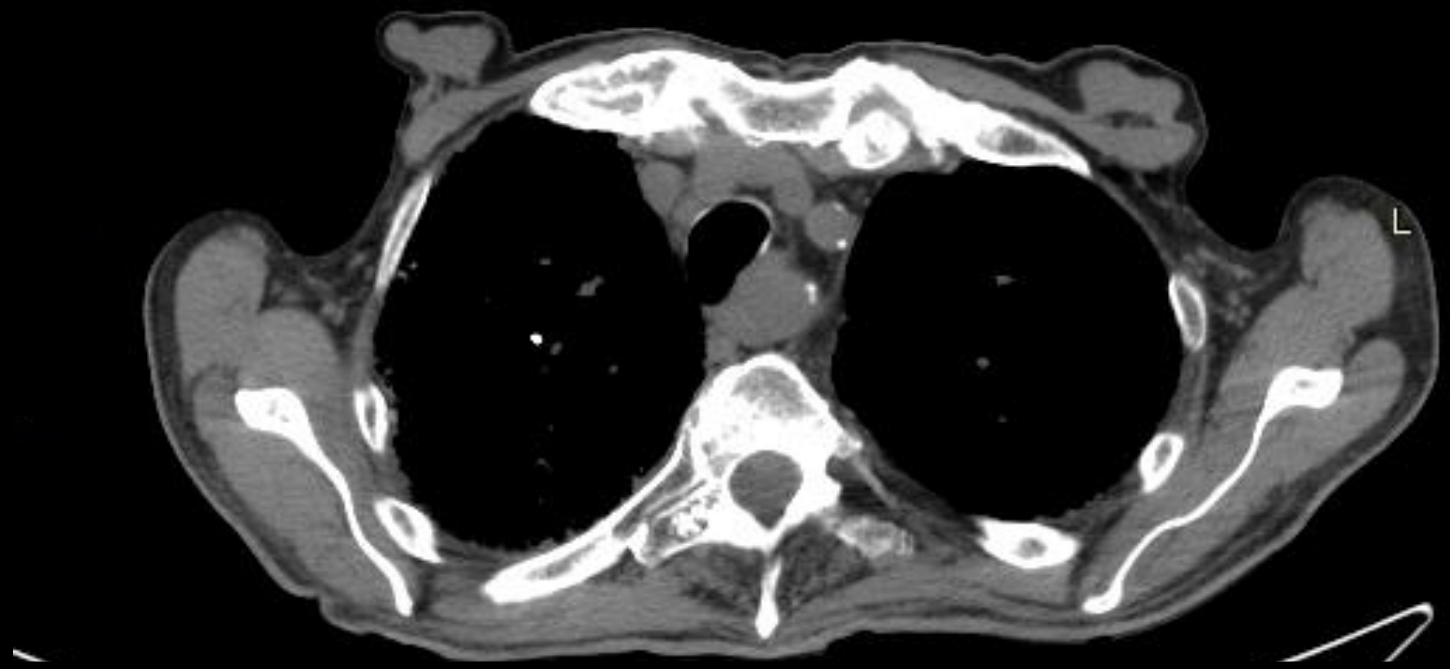
L

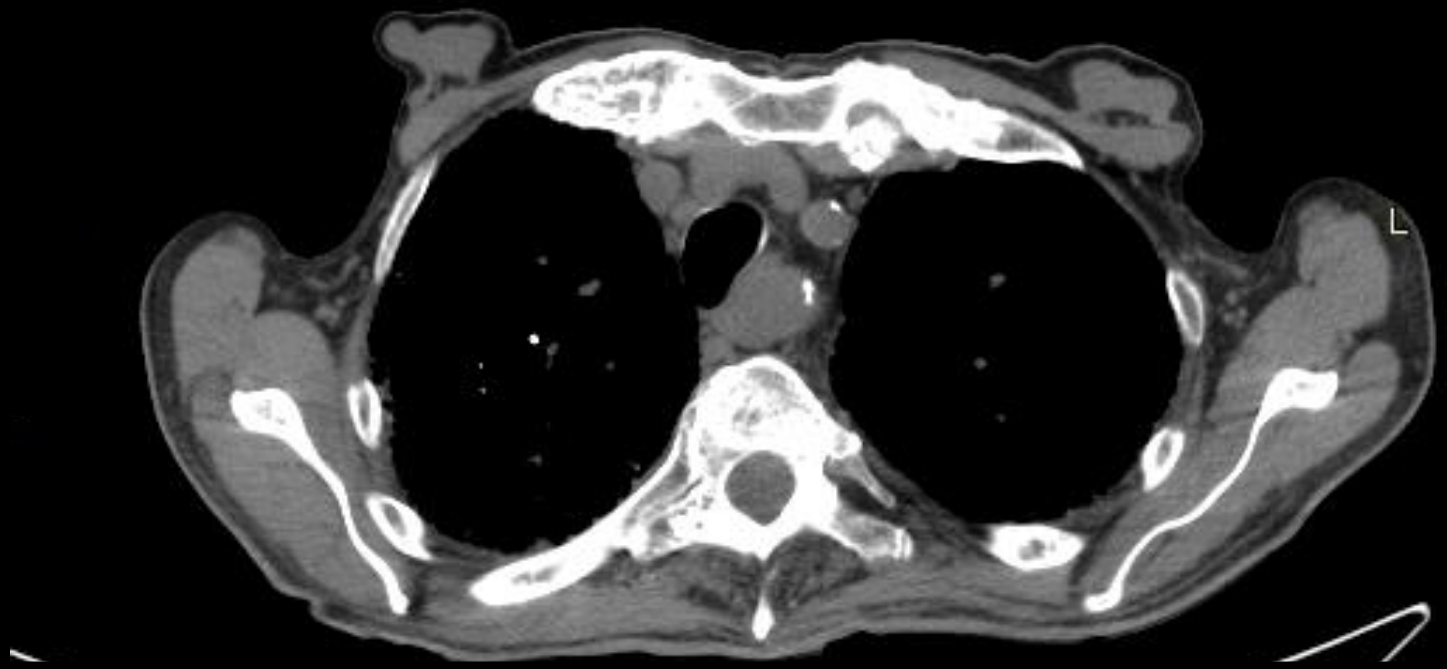
L

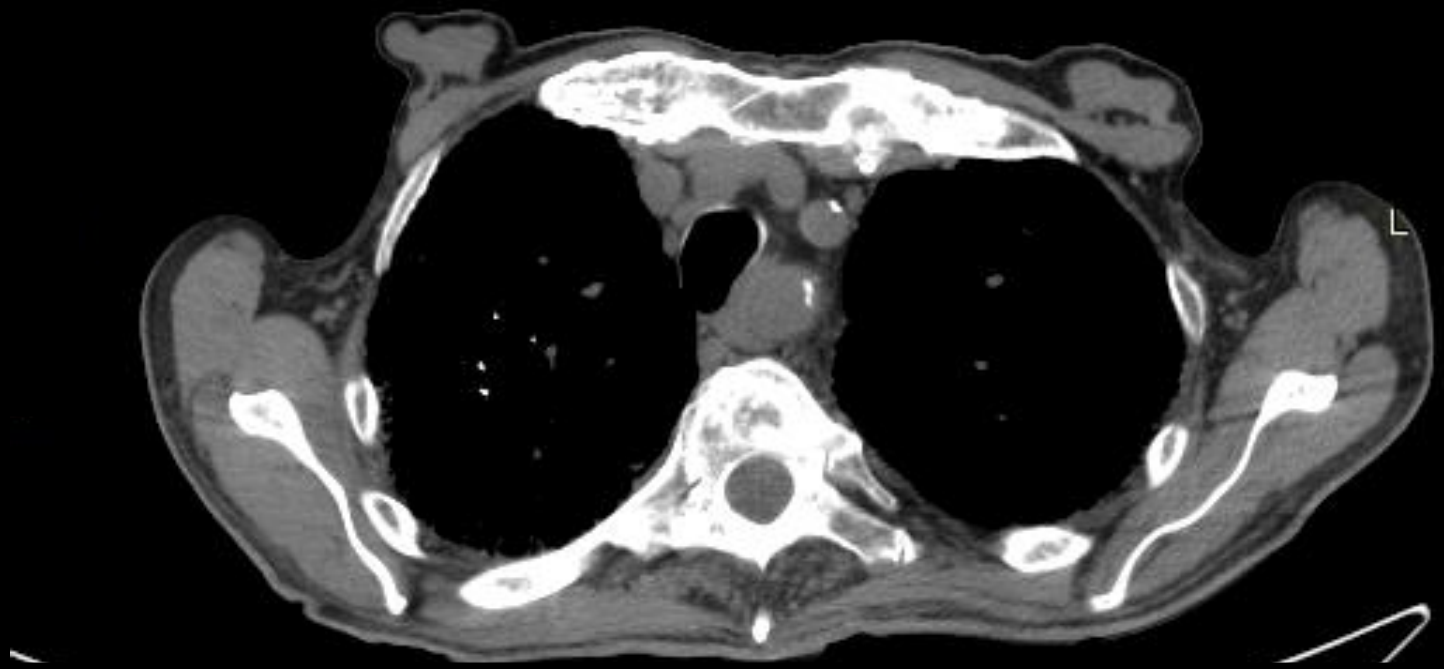
L

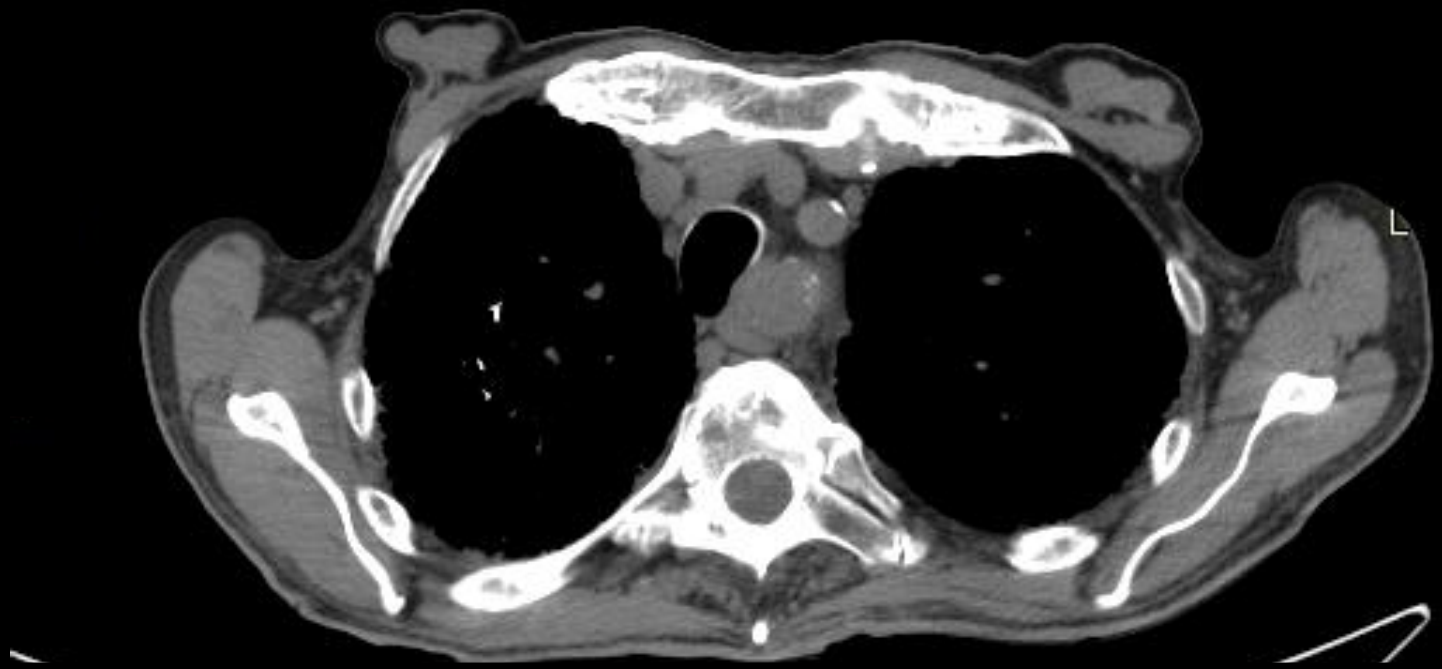
L

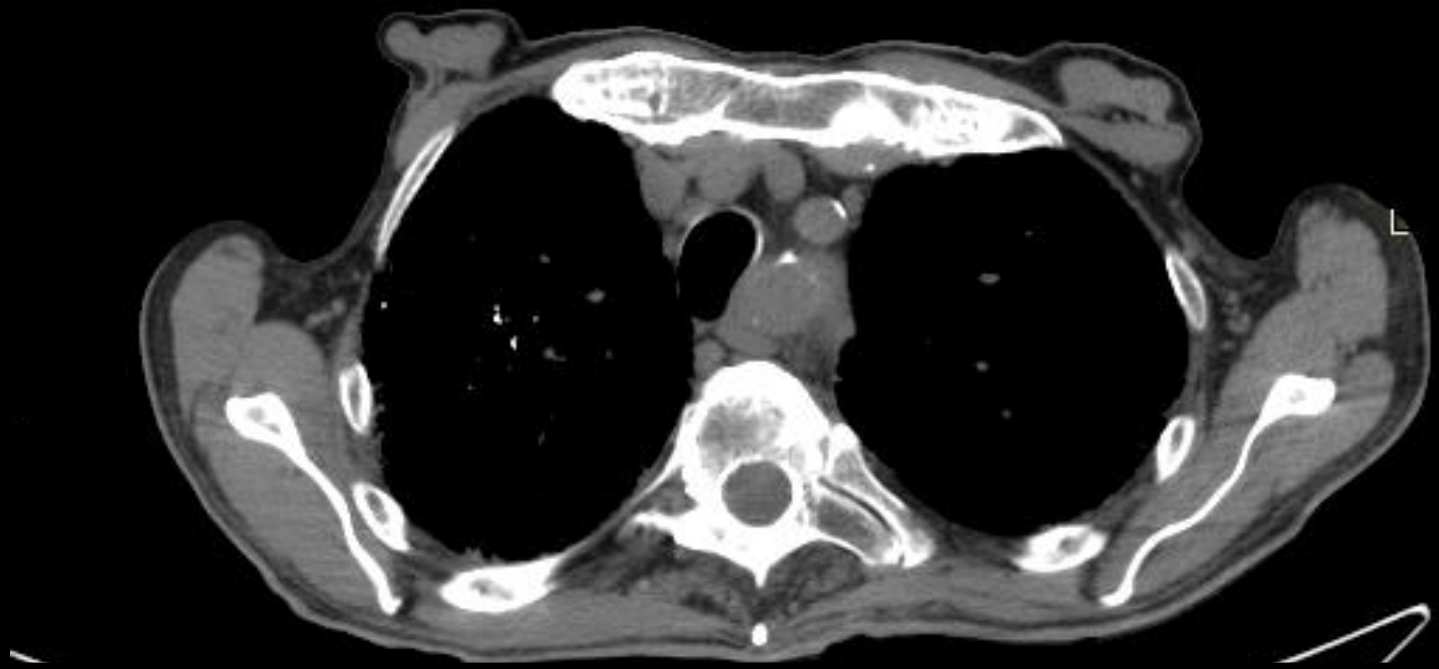
L

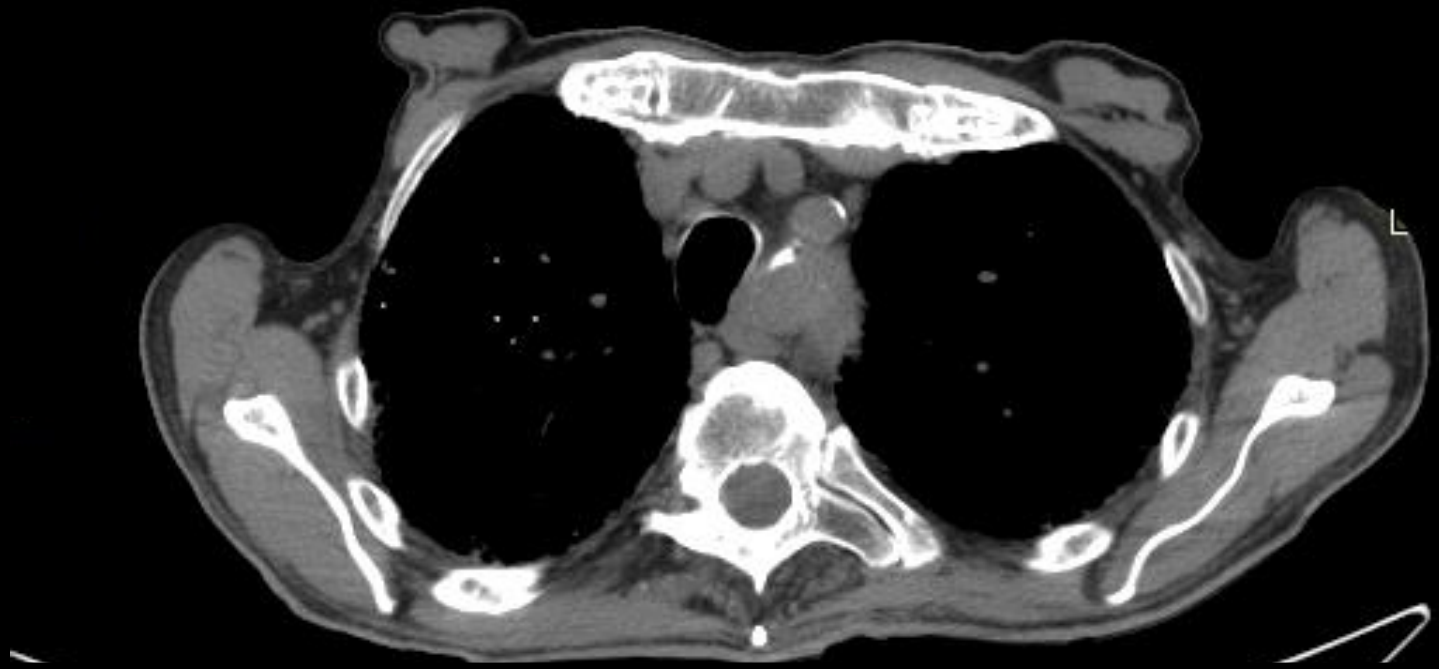
L

L

L

L

L

L

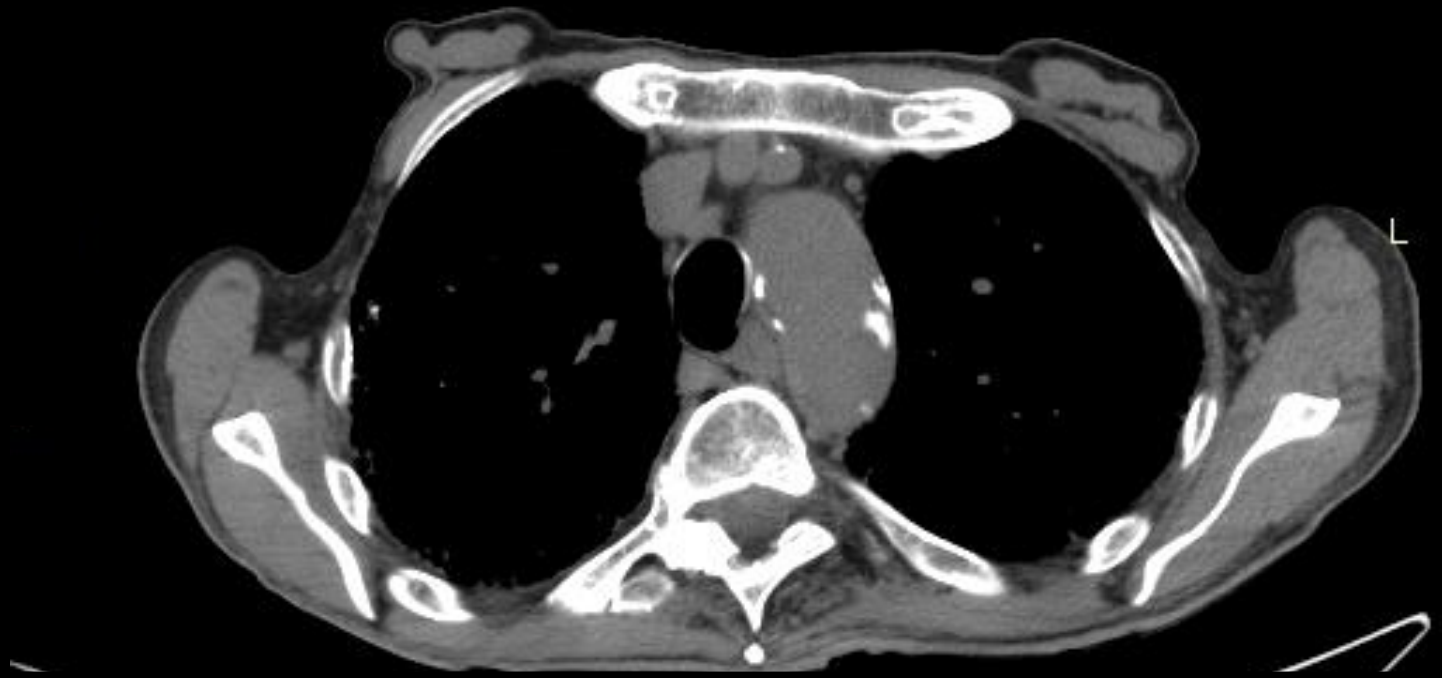
L

L

L

L

L

L

L

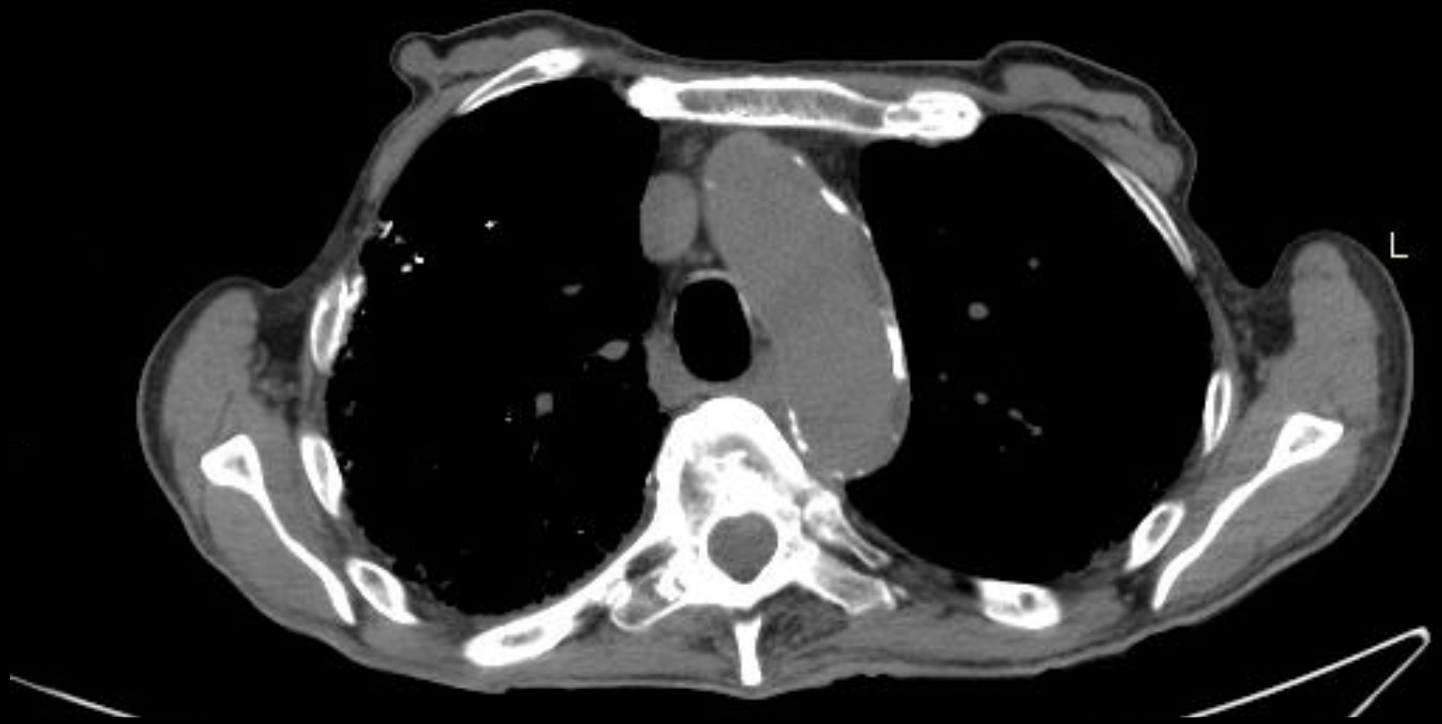
L

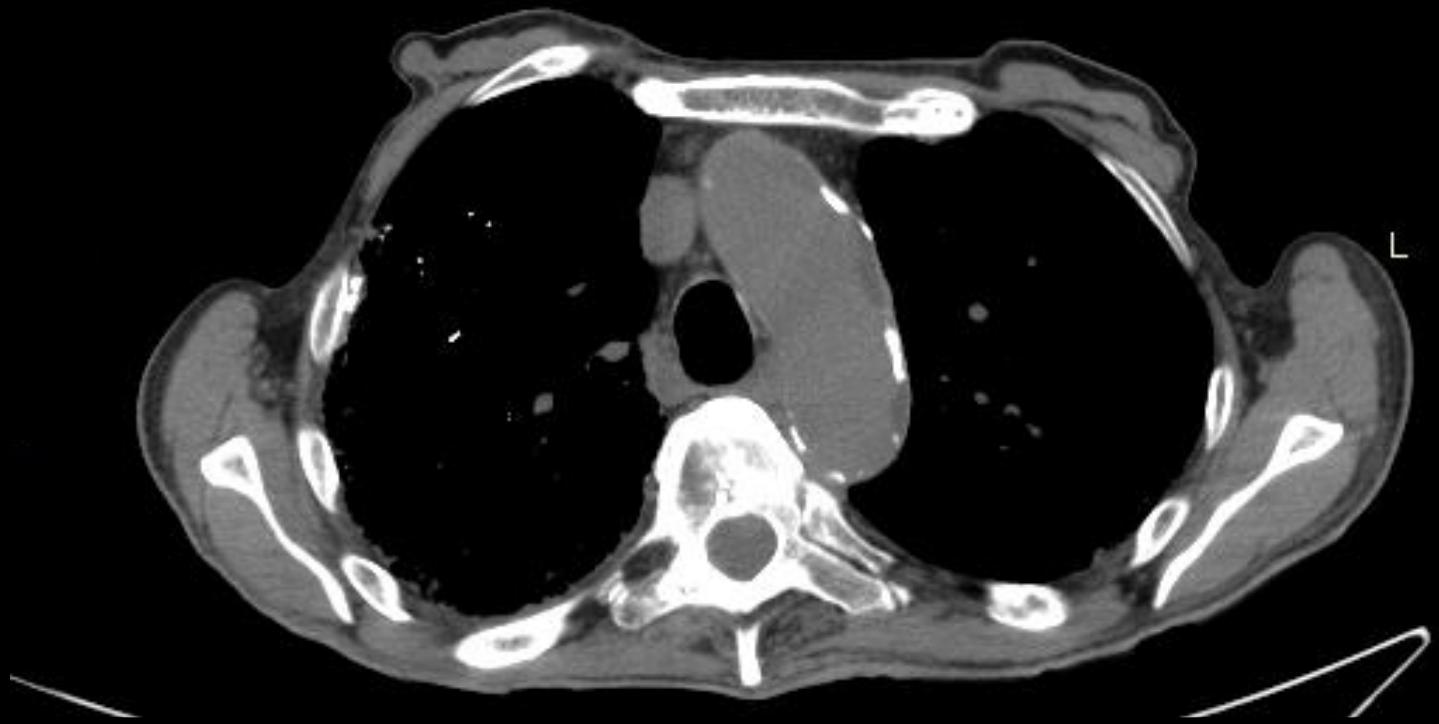
L

L

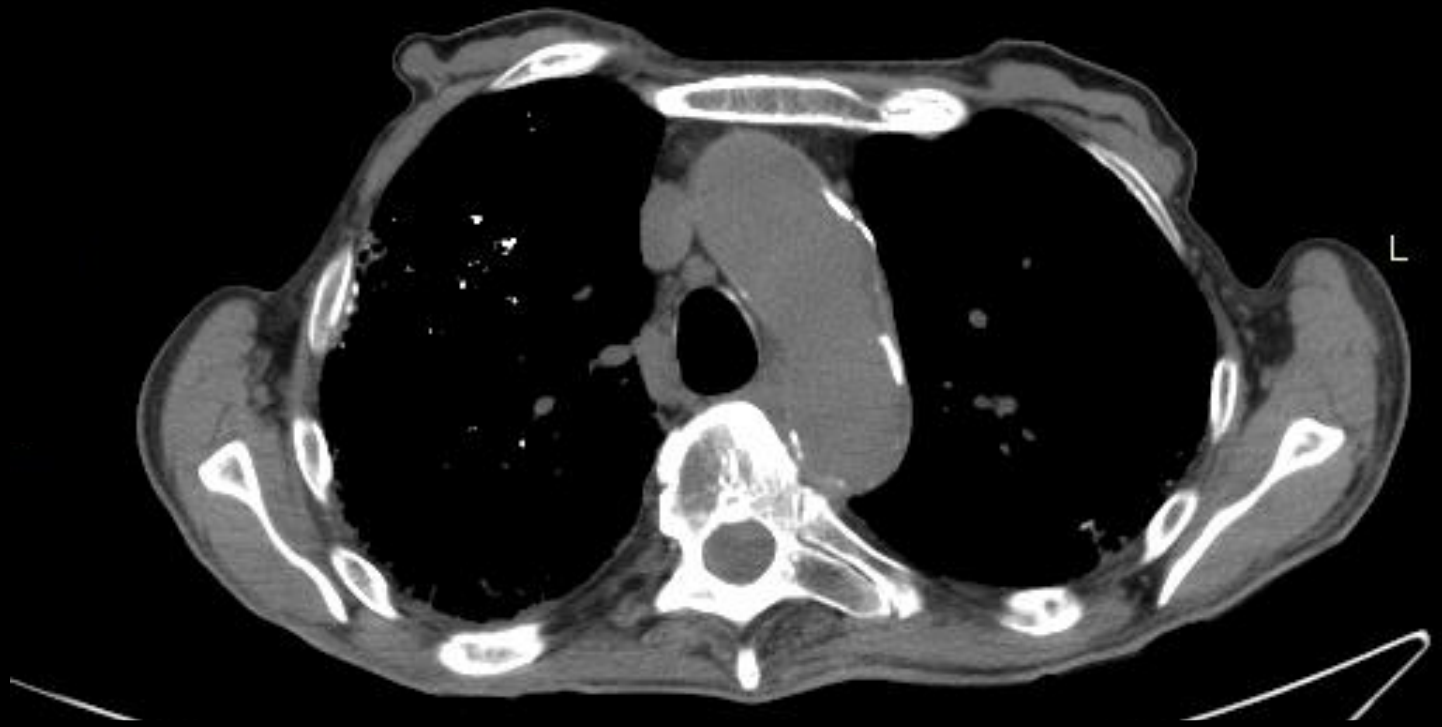
L

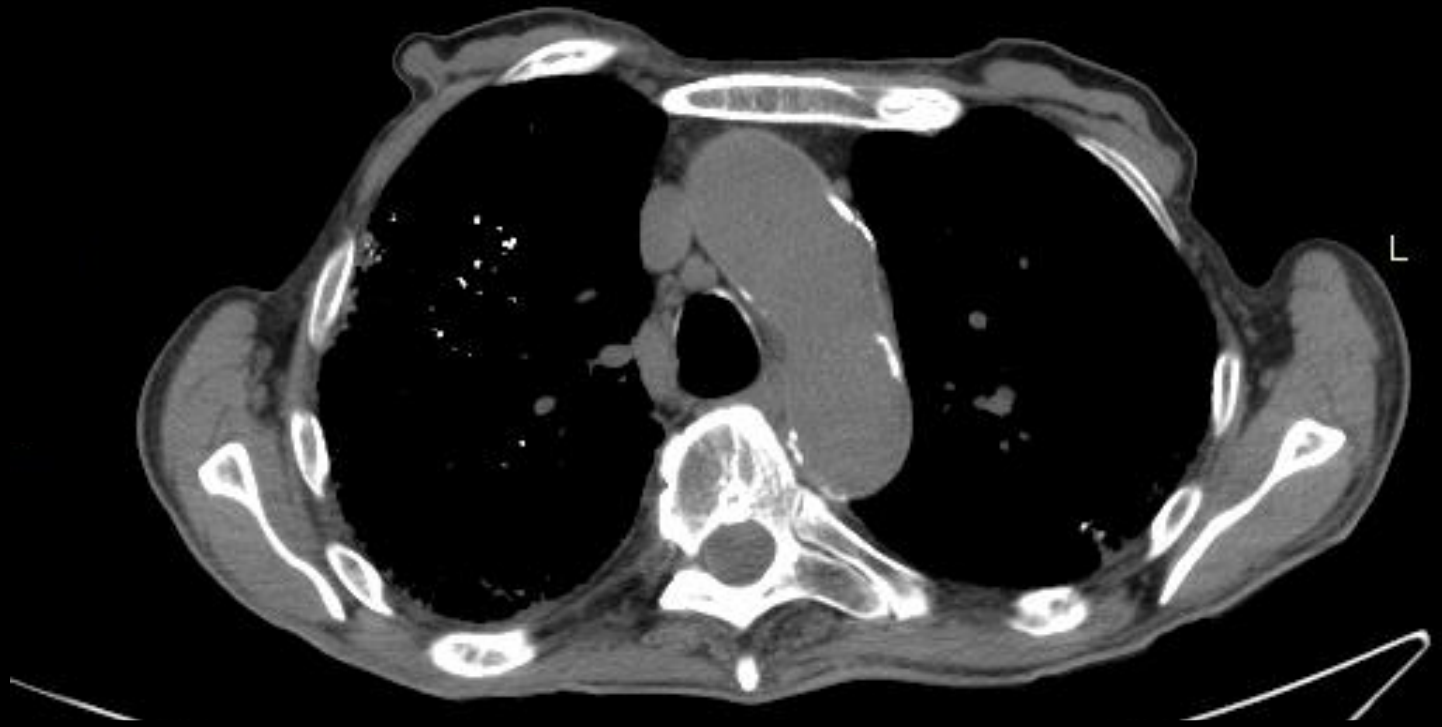
L

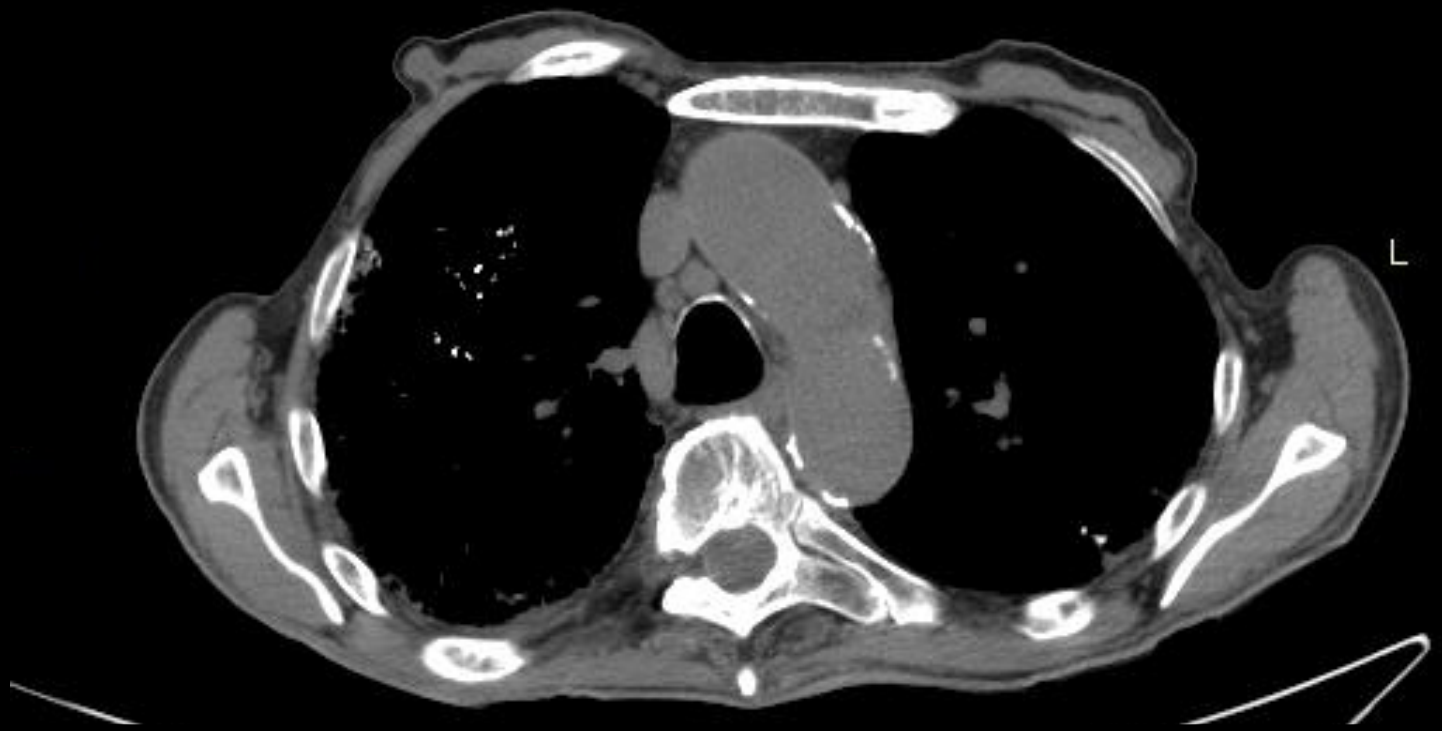
L

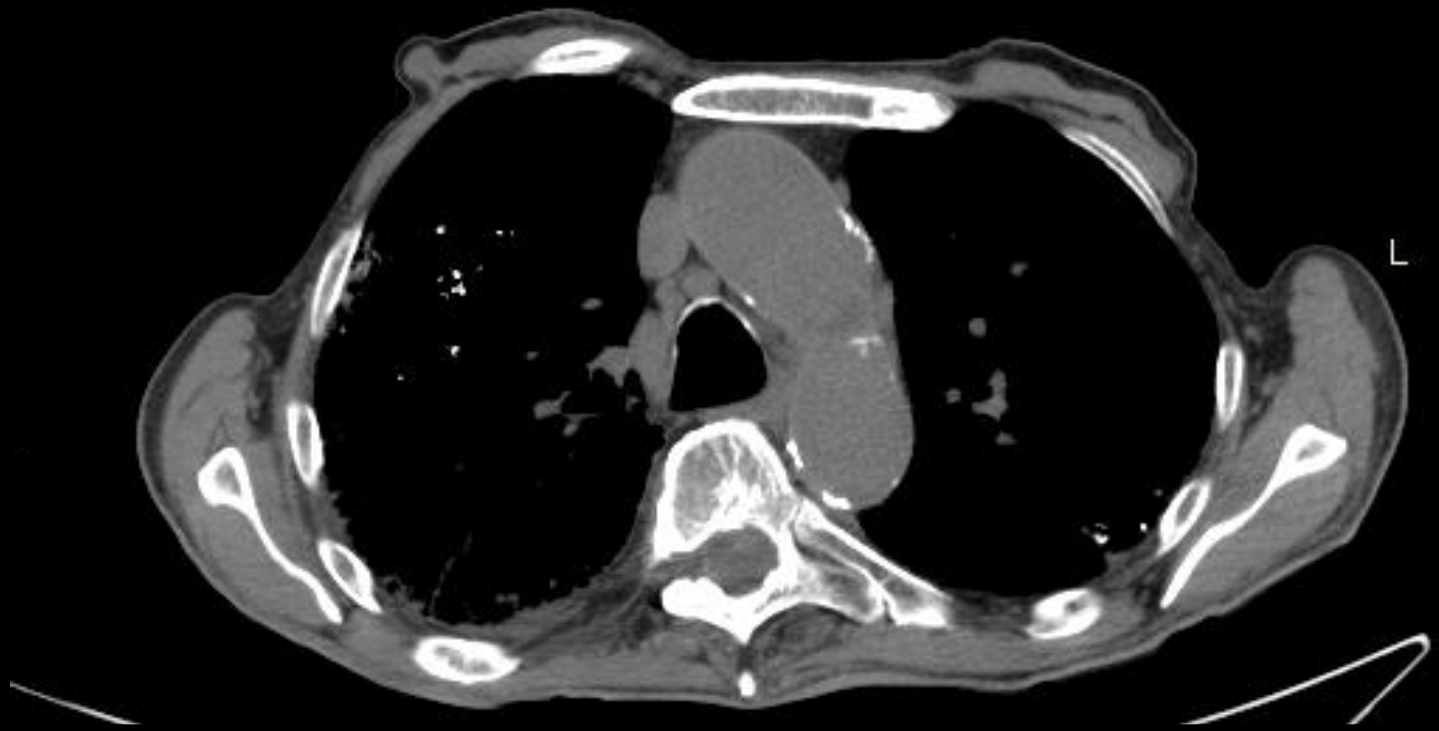
L

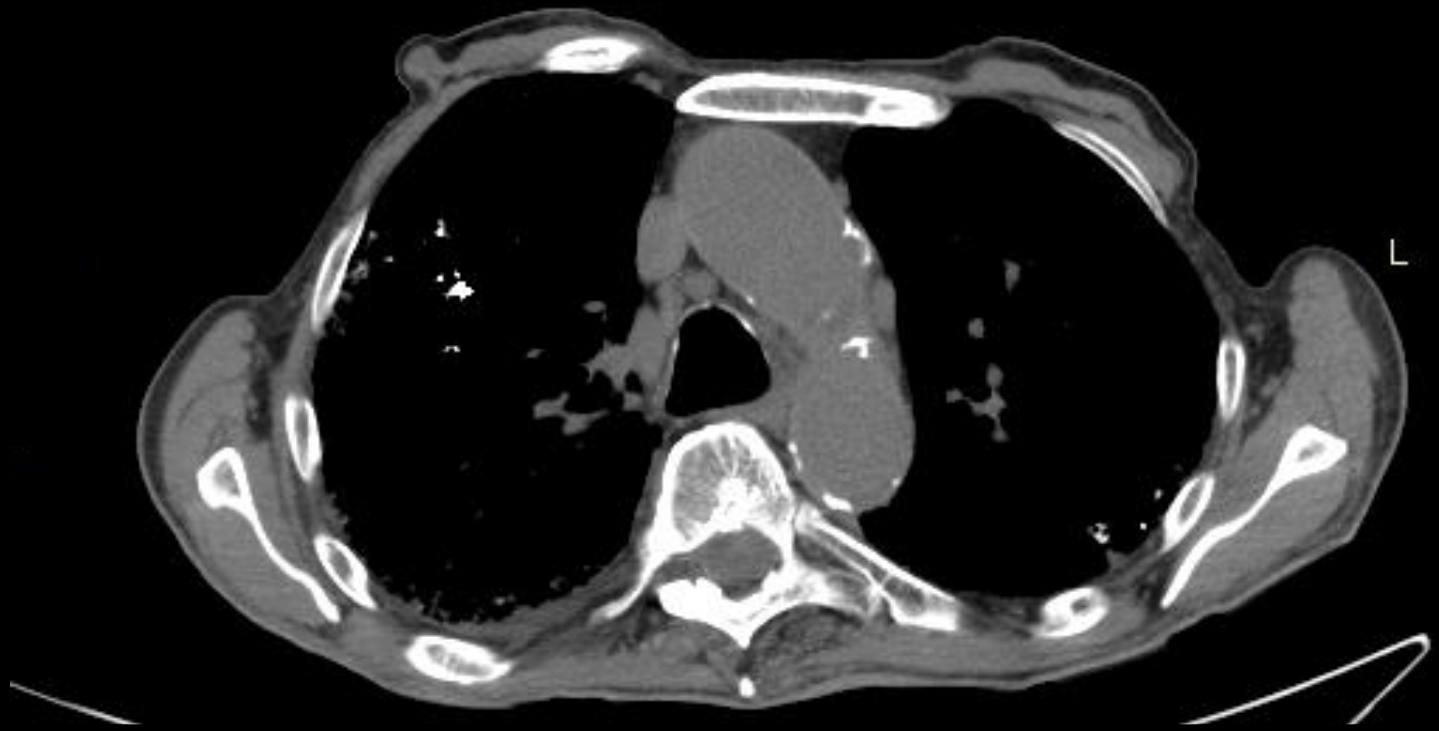
L

L

L

L

L

L

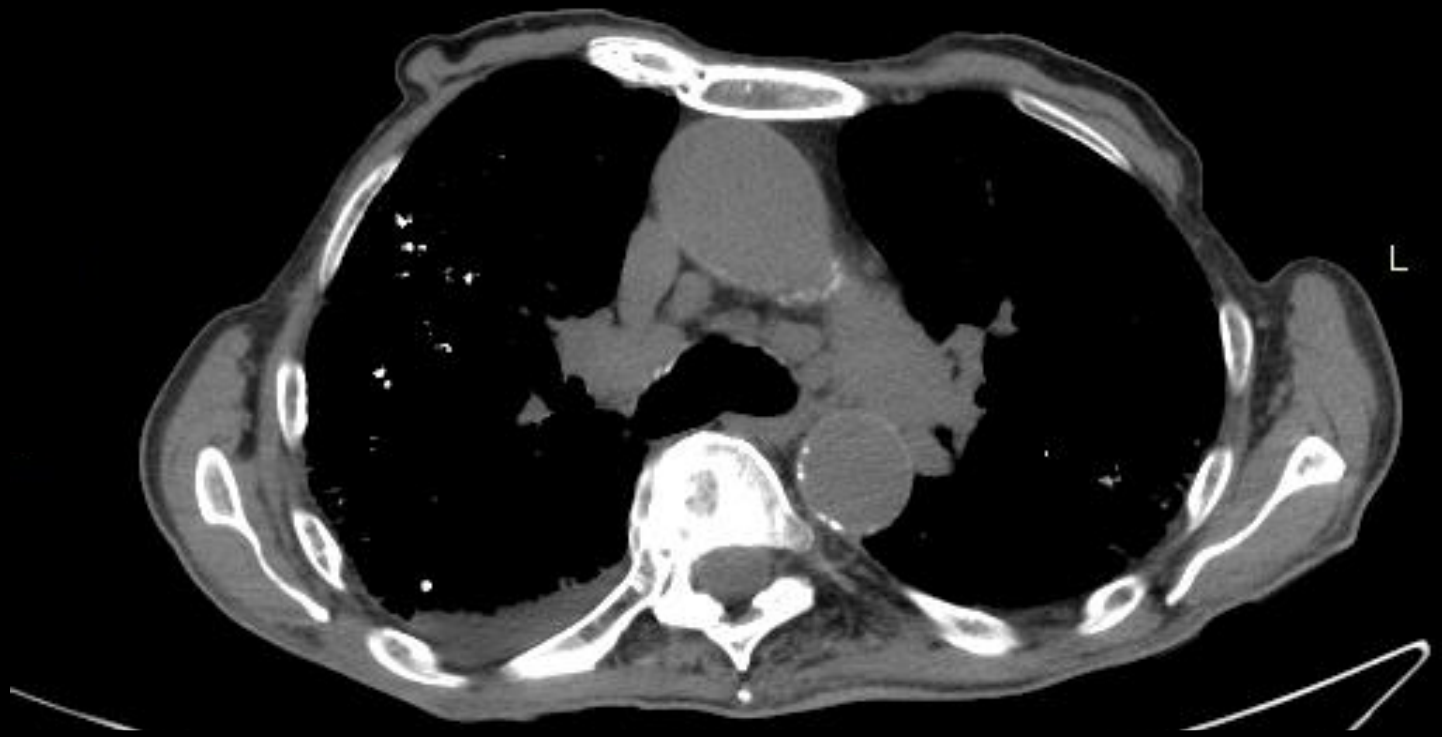
L

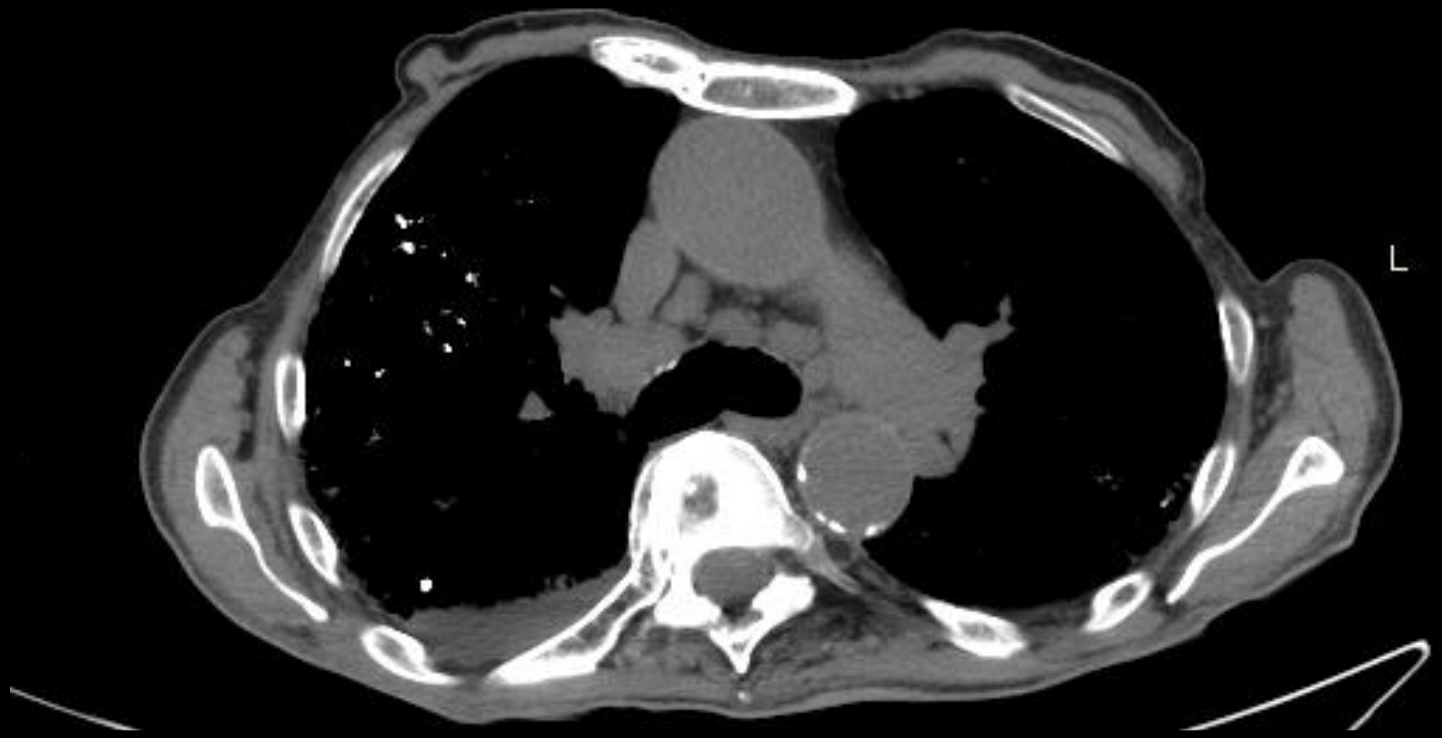
L

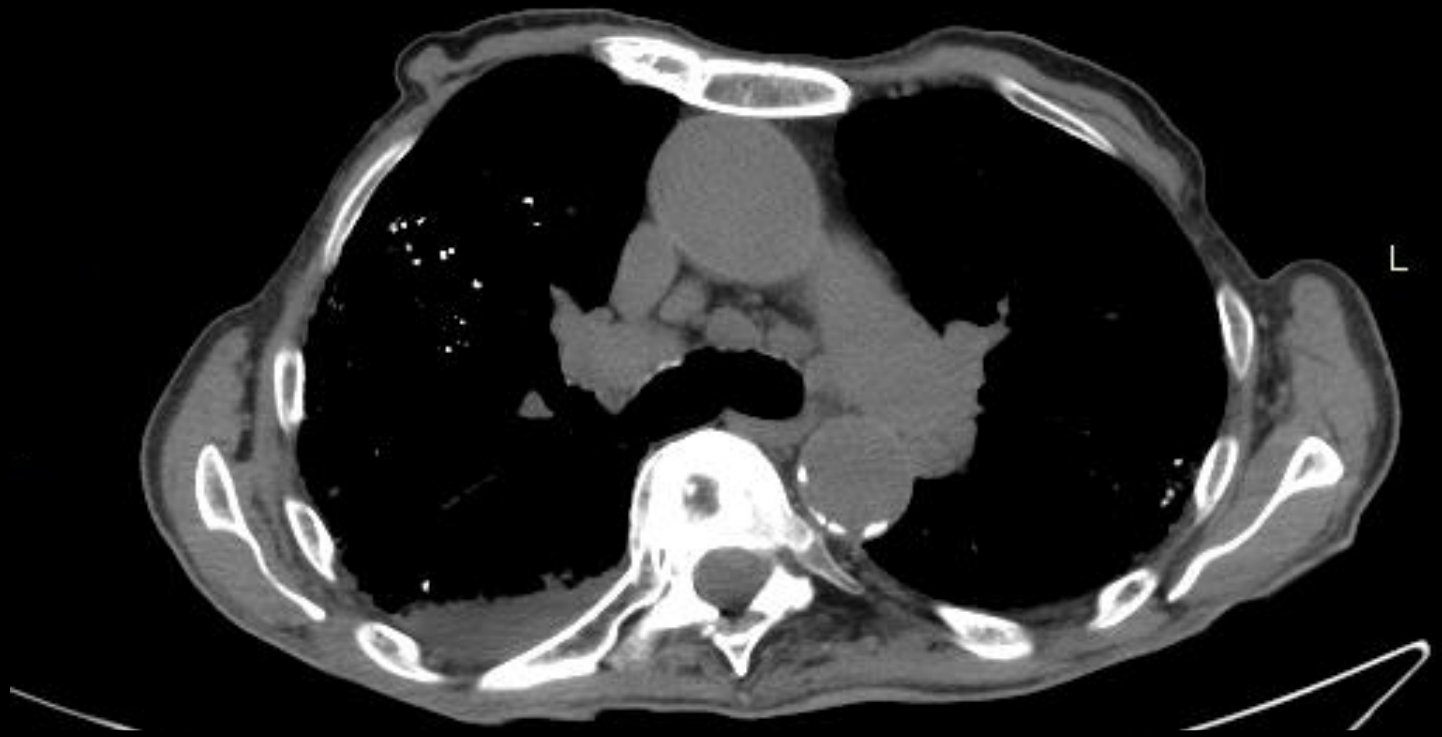
L

L

L

L

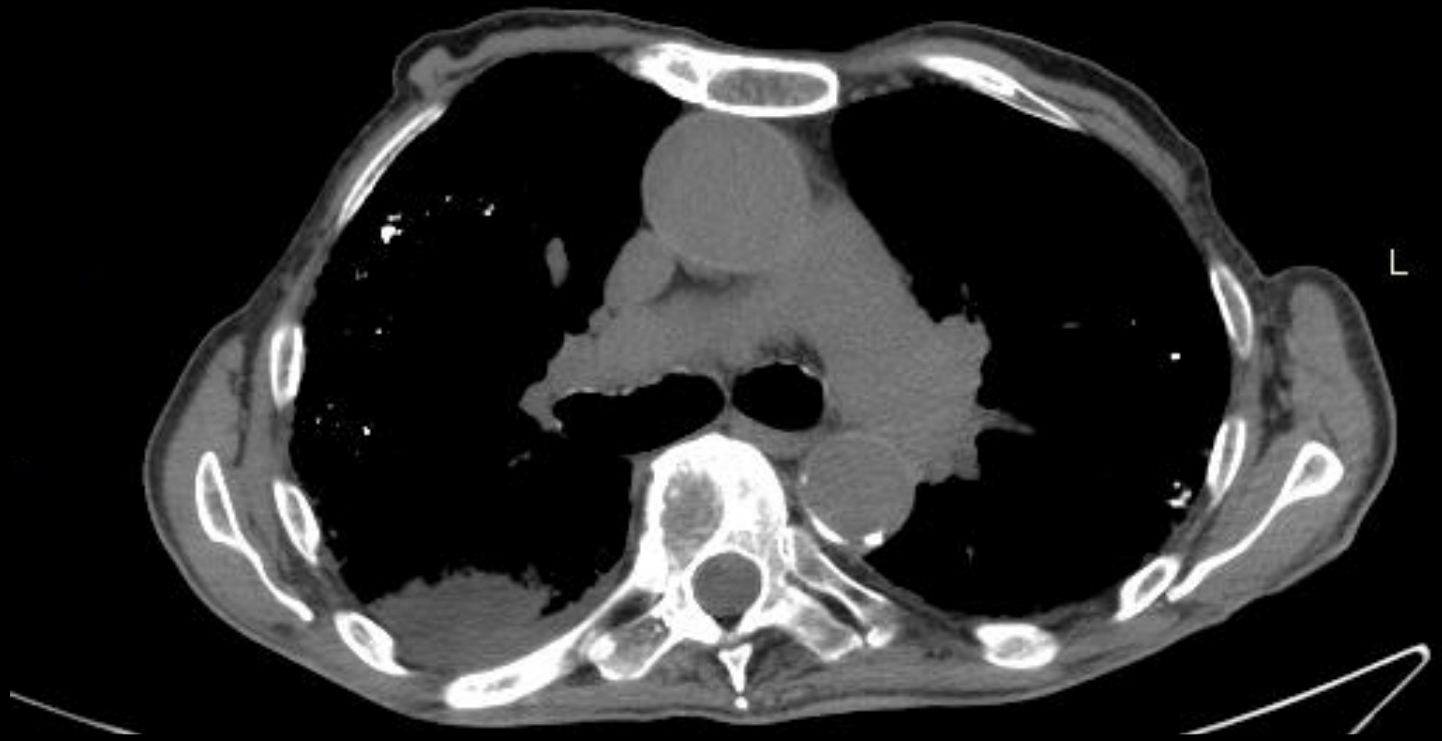
L

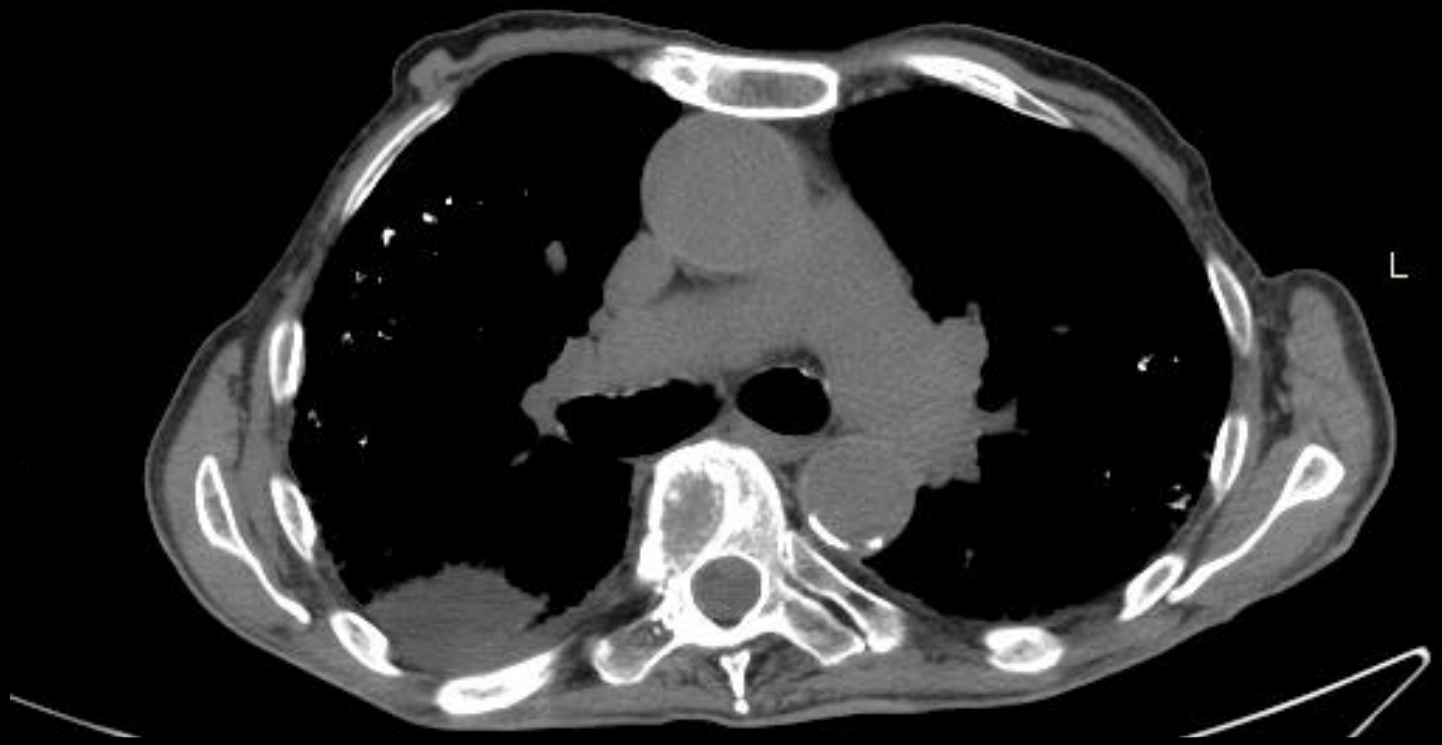
L

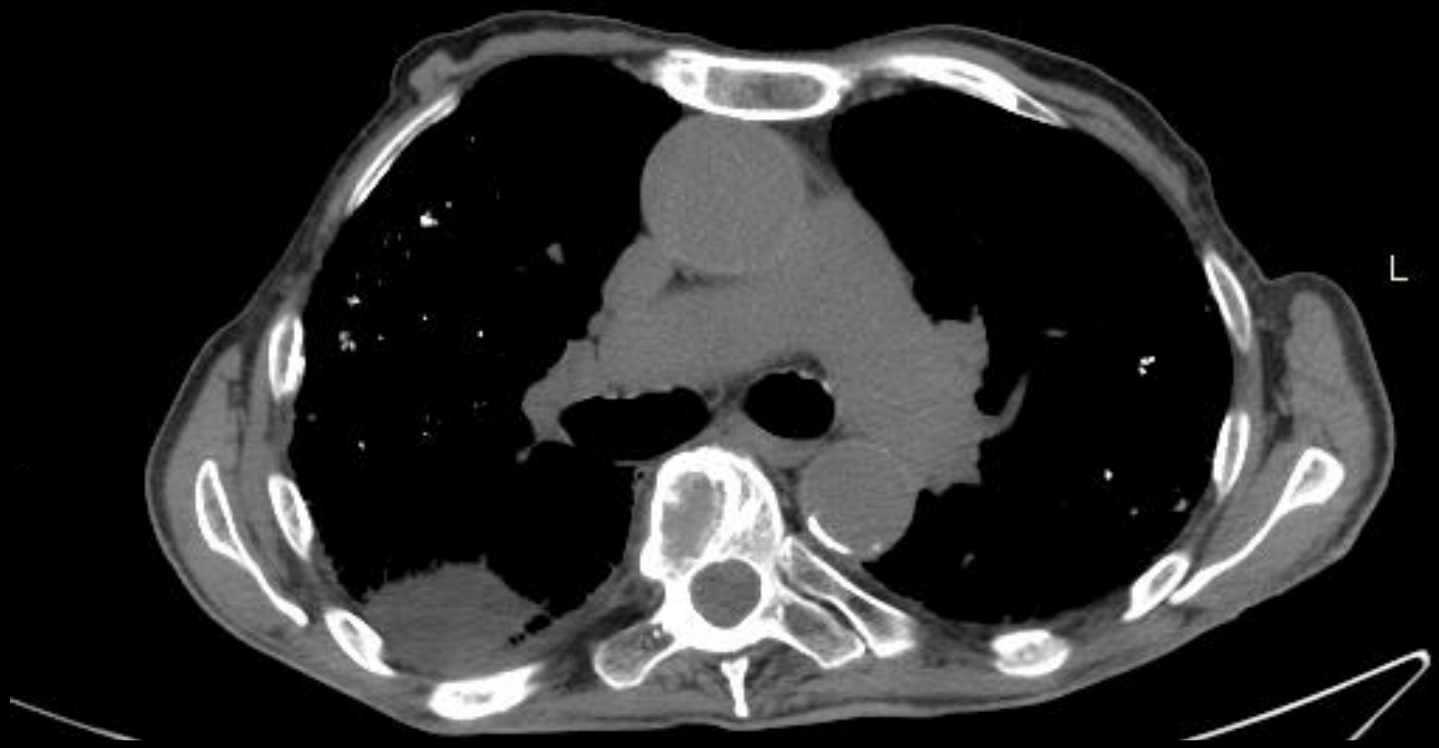
L

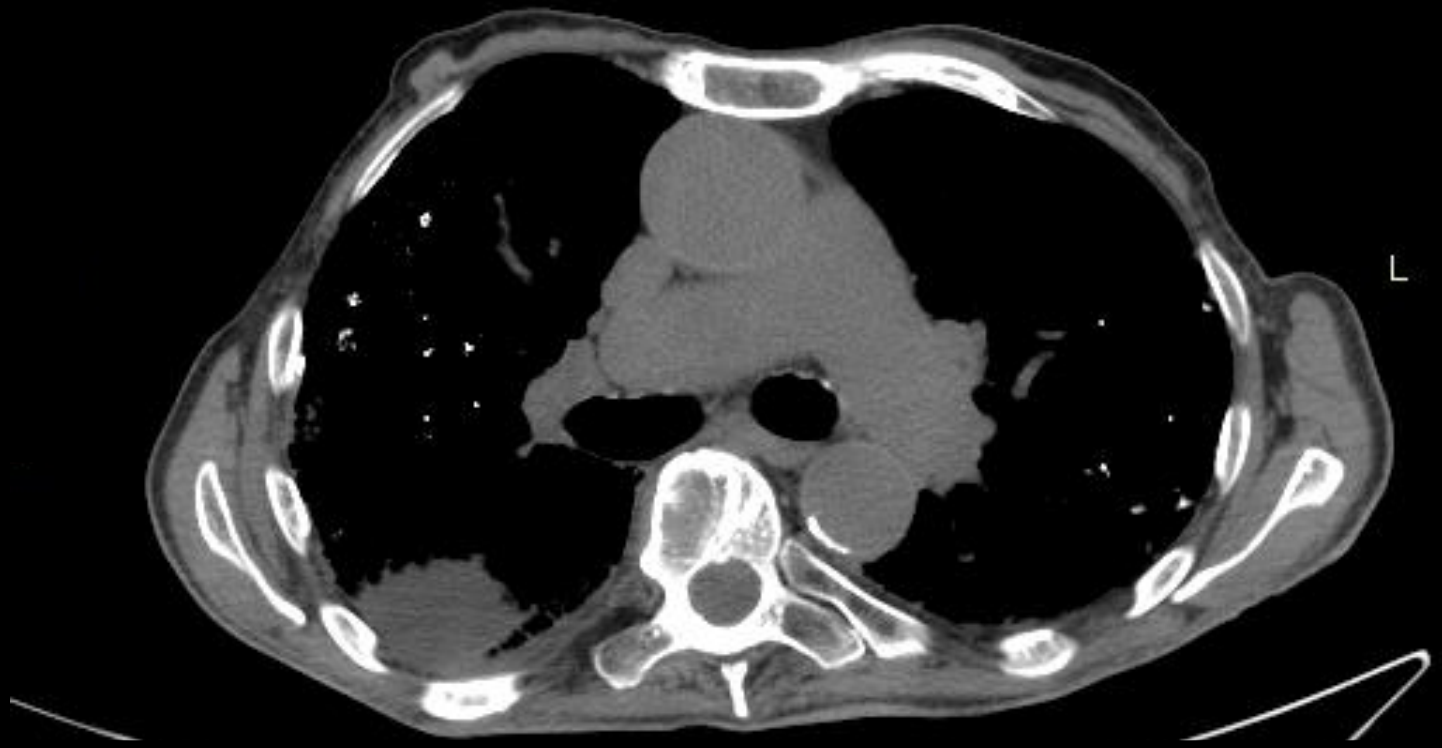
L

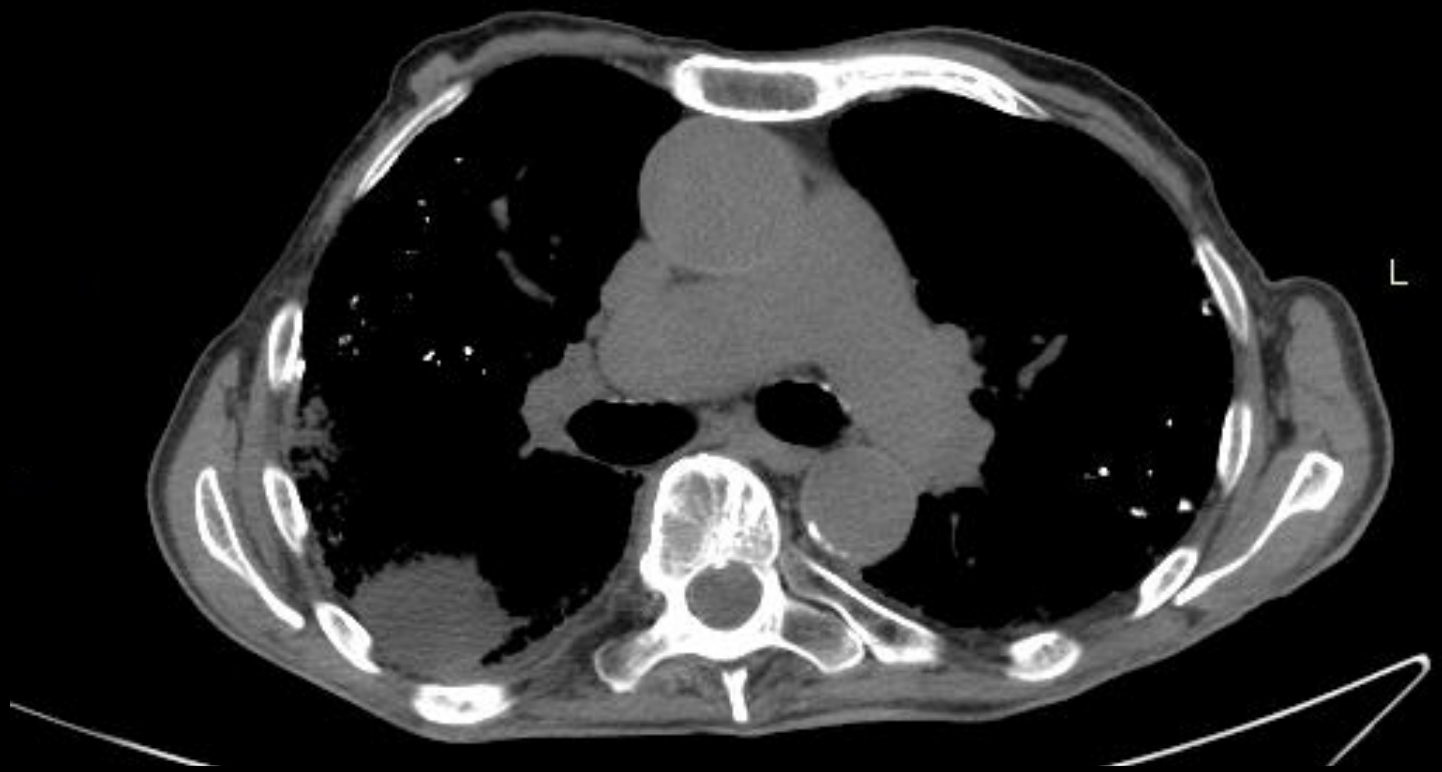
L

L

L

L

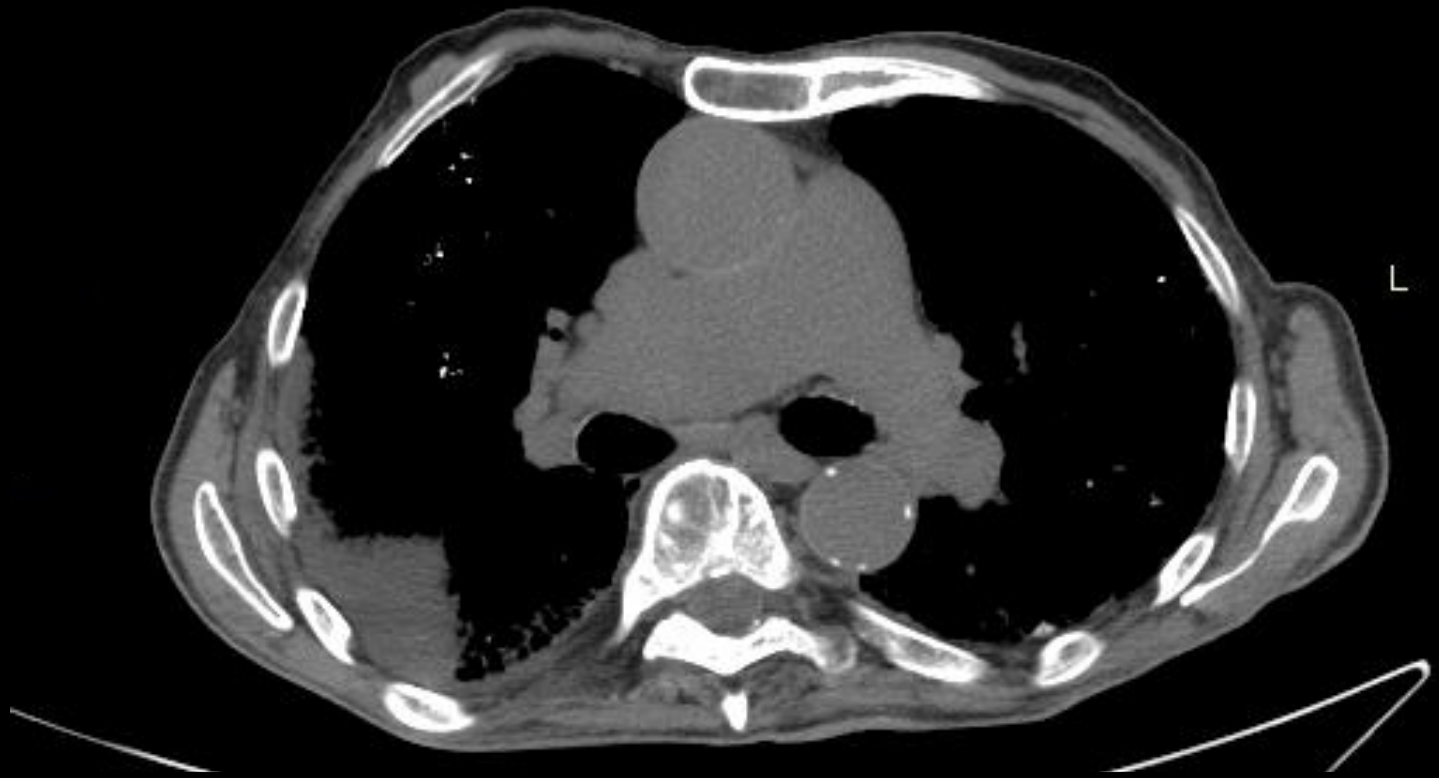
L

L

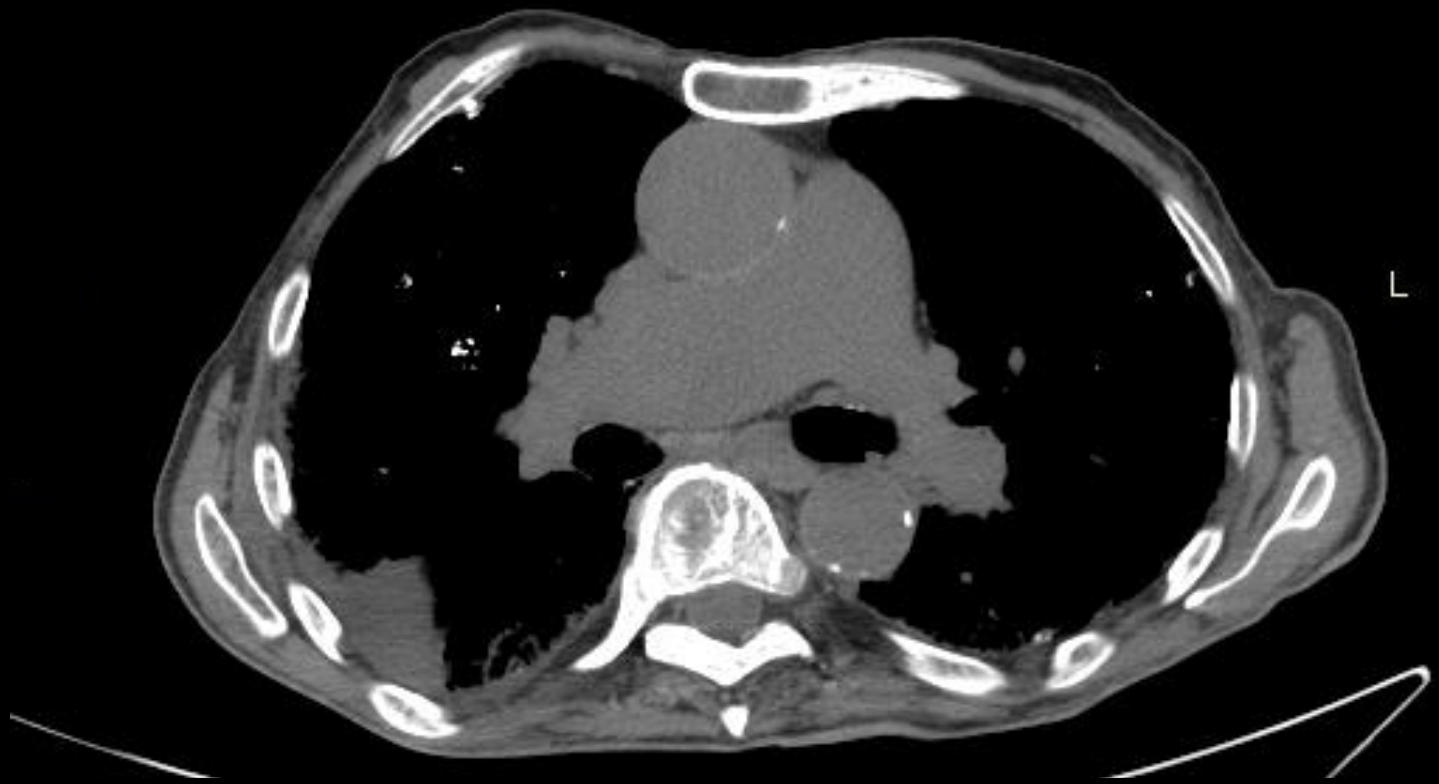
L

L

L

L

L

L

L

L

L

L

L

L

L

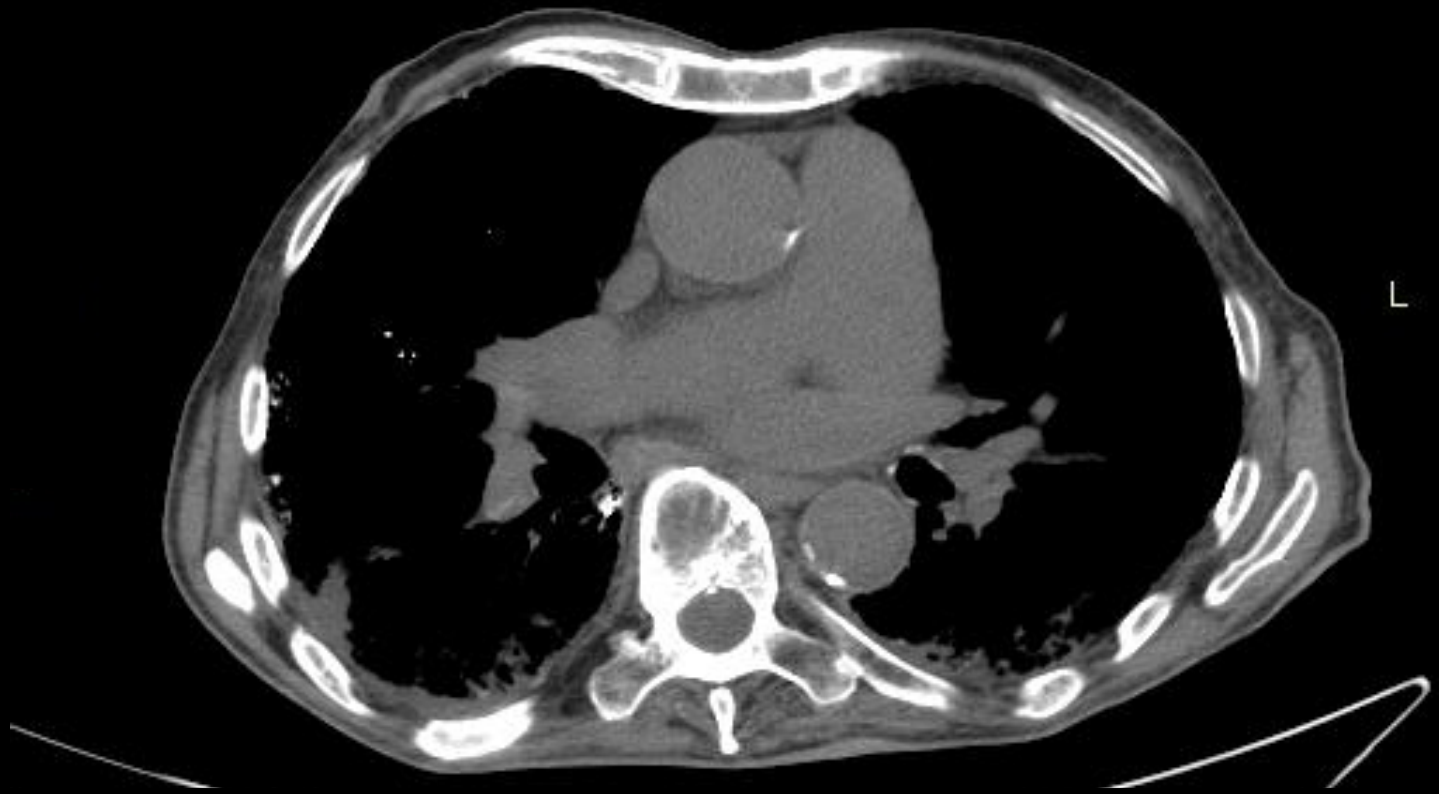
L

L

L

L

L

L

L

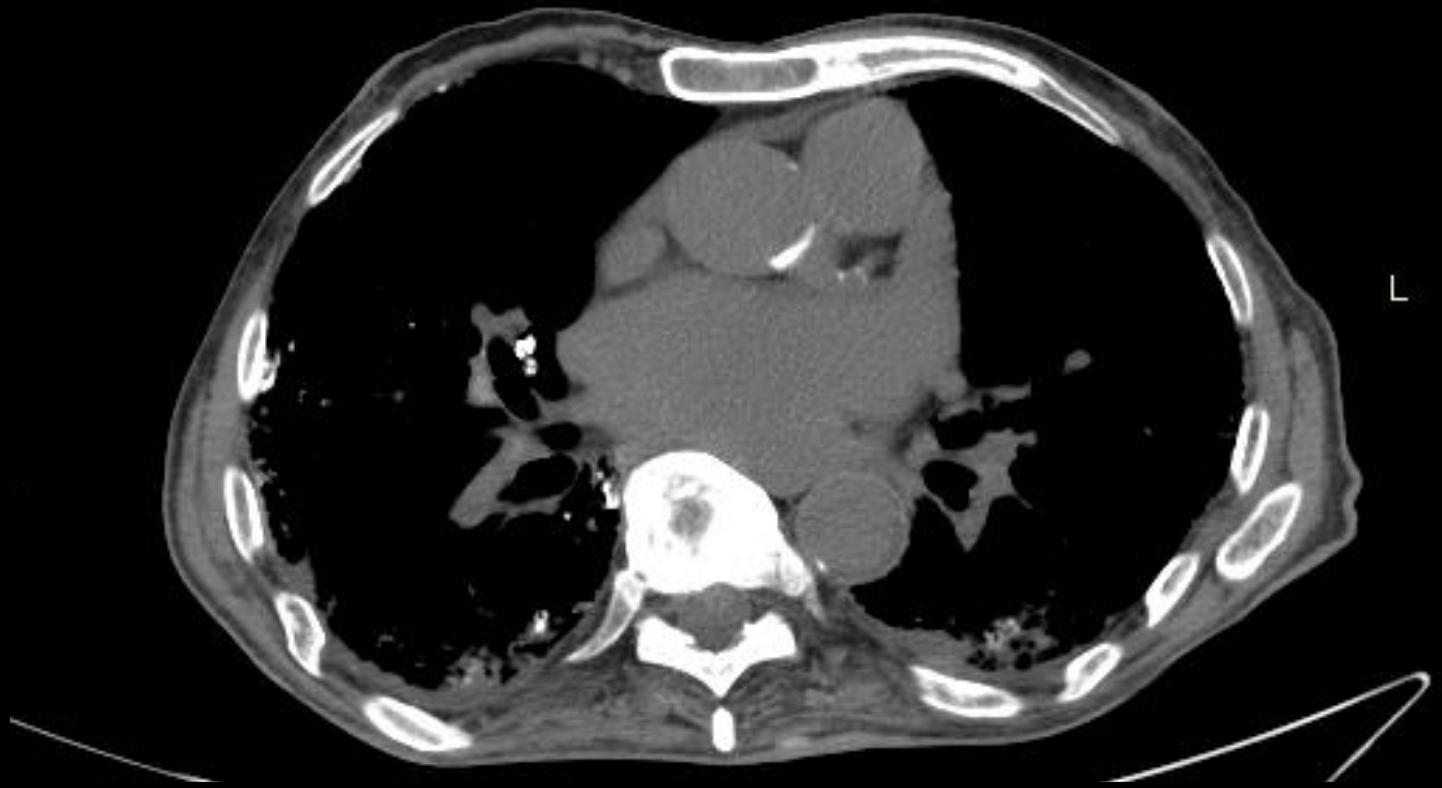
L

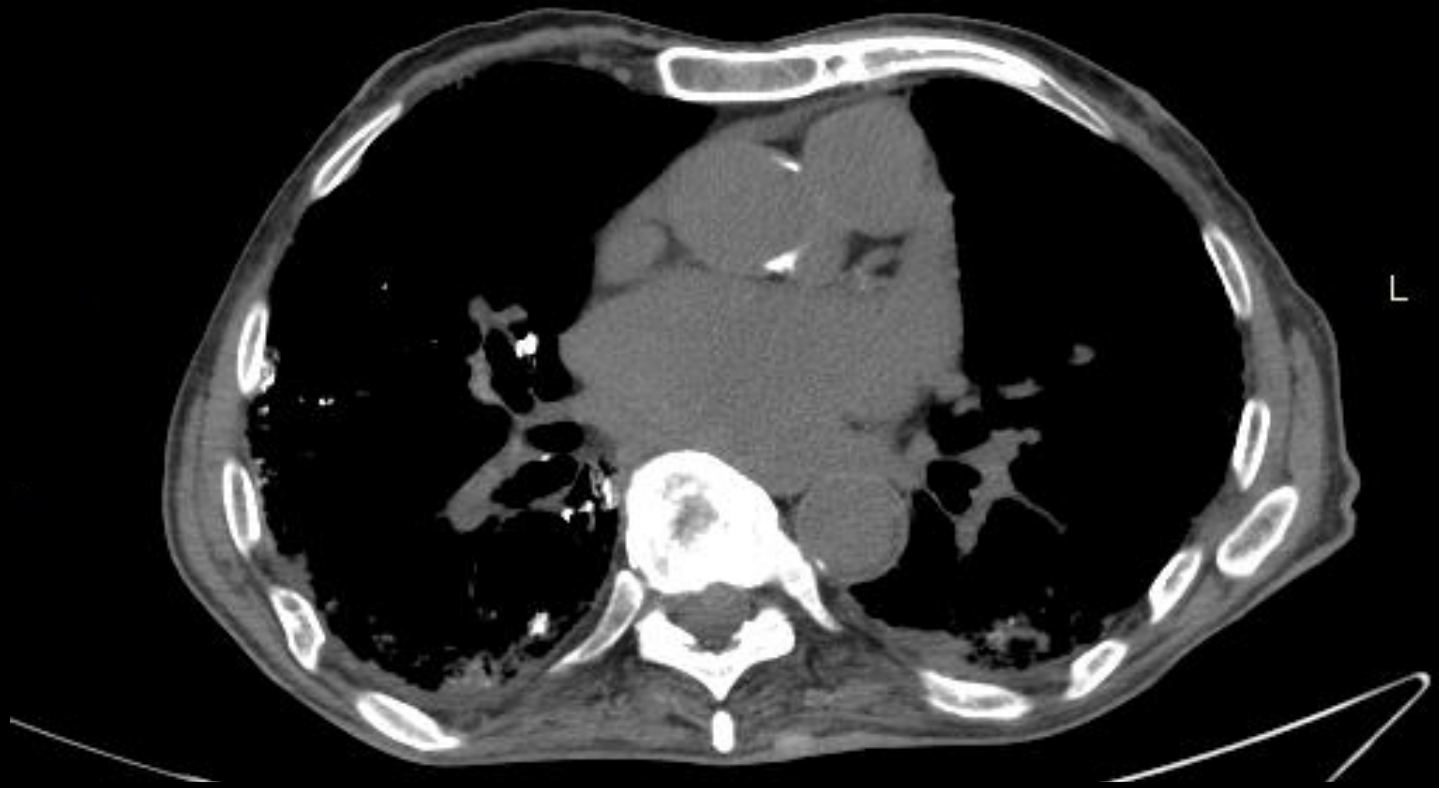
L

L

L

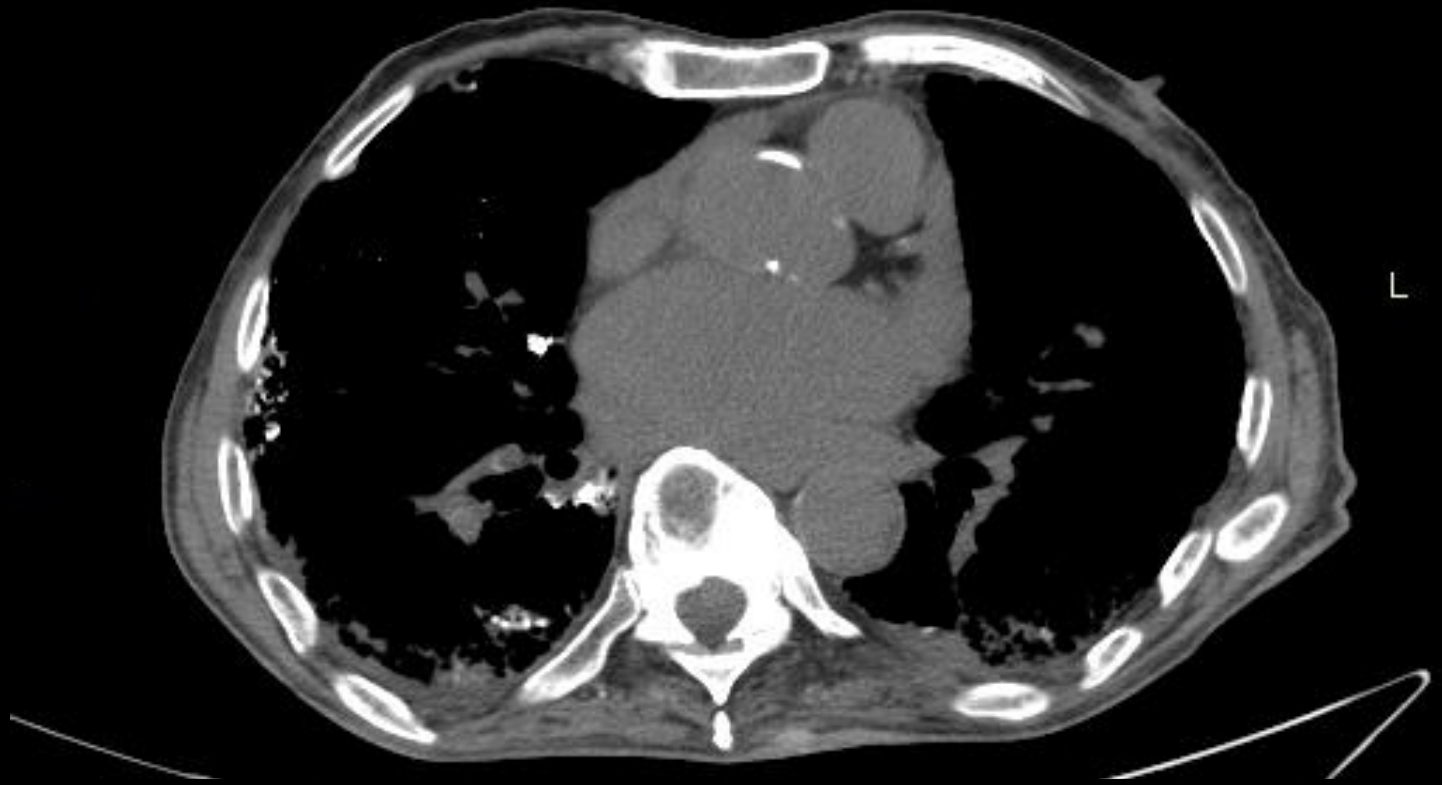
L

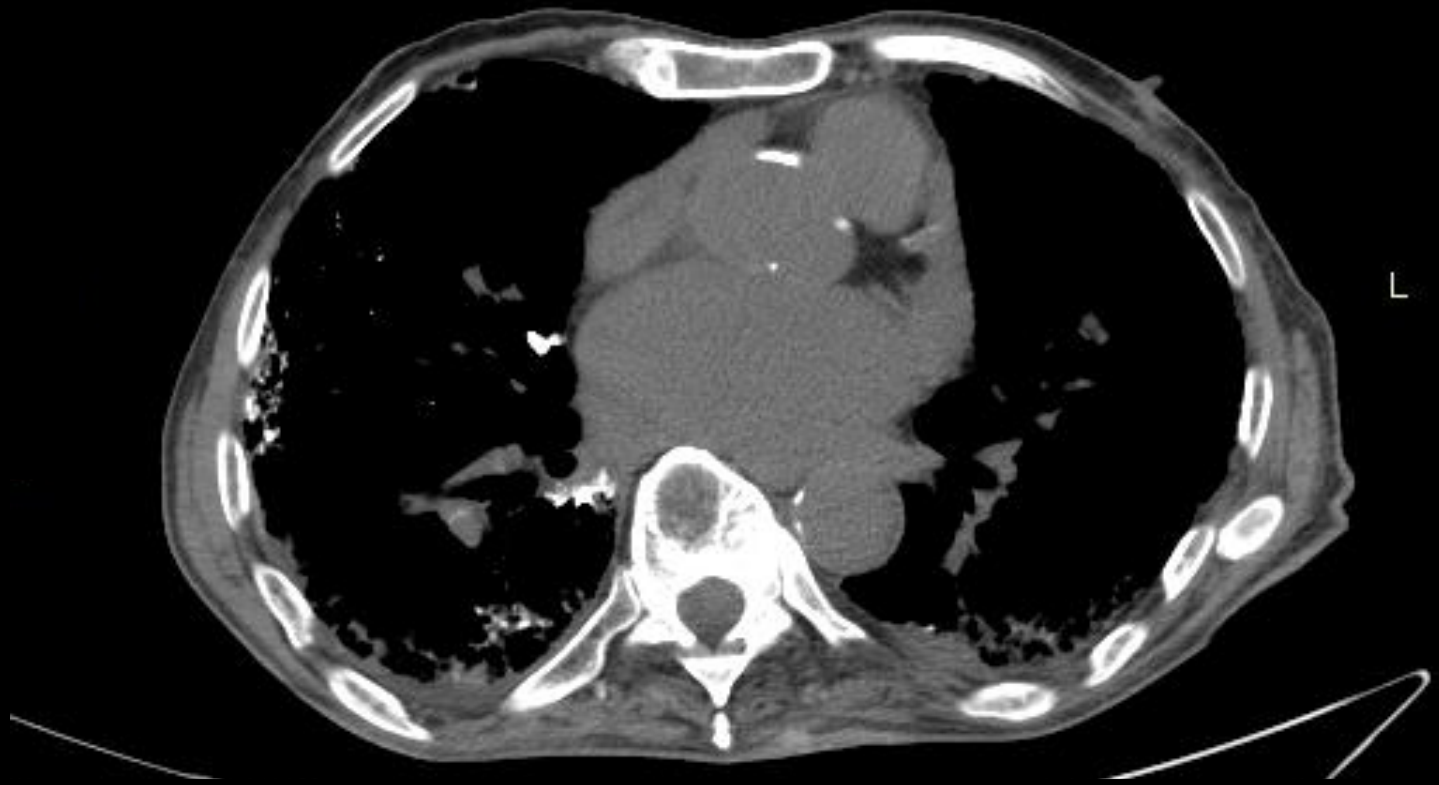
L

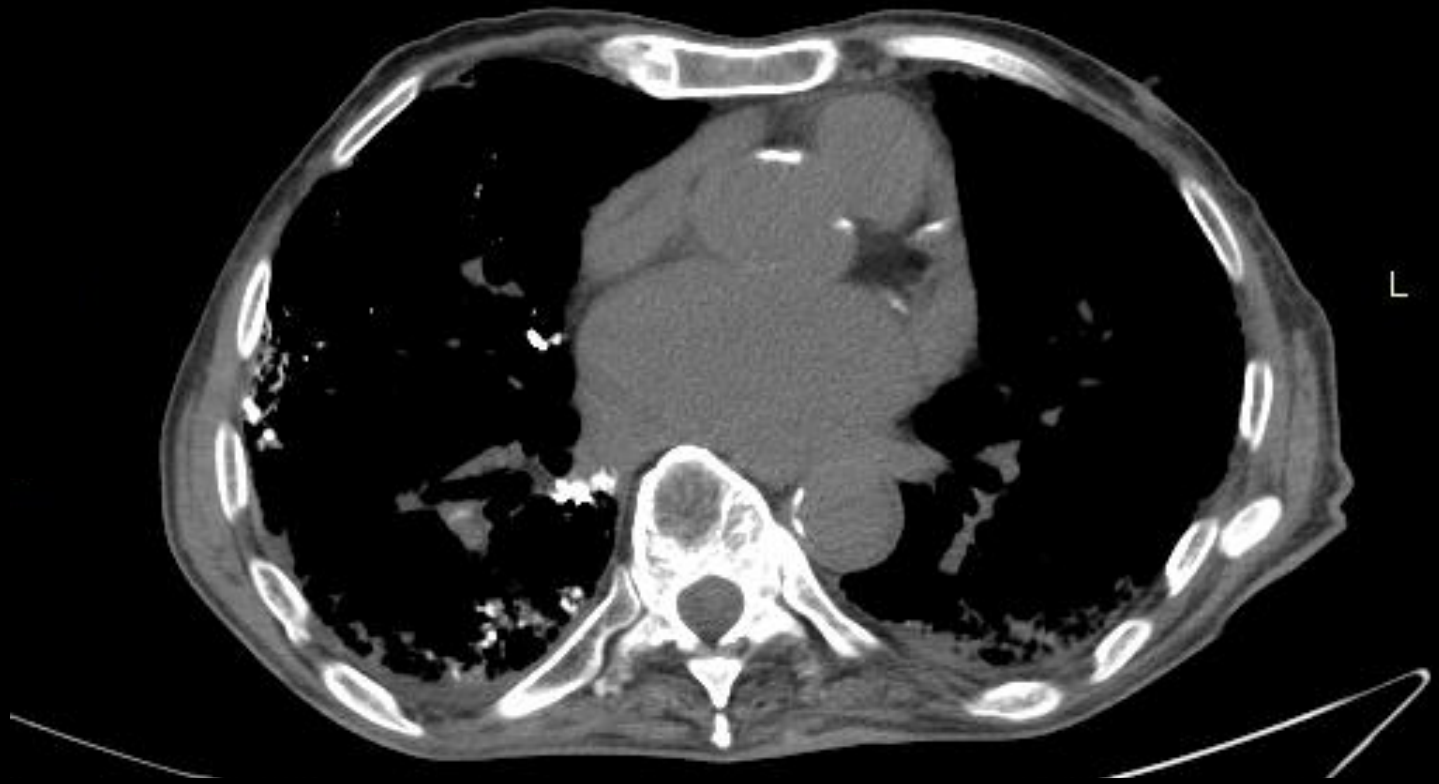
L

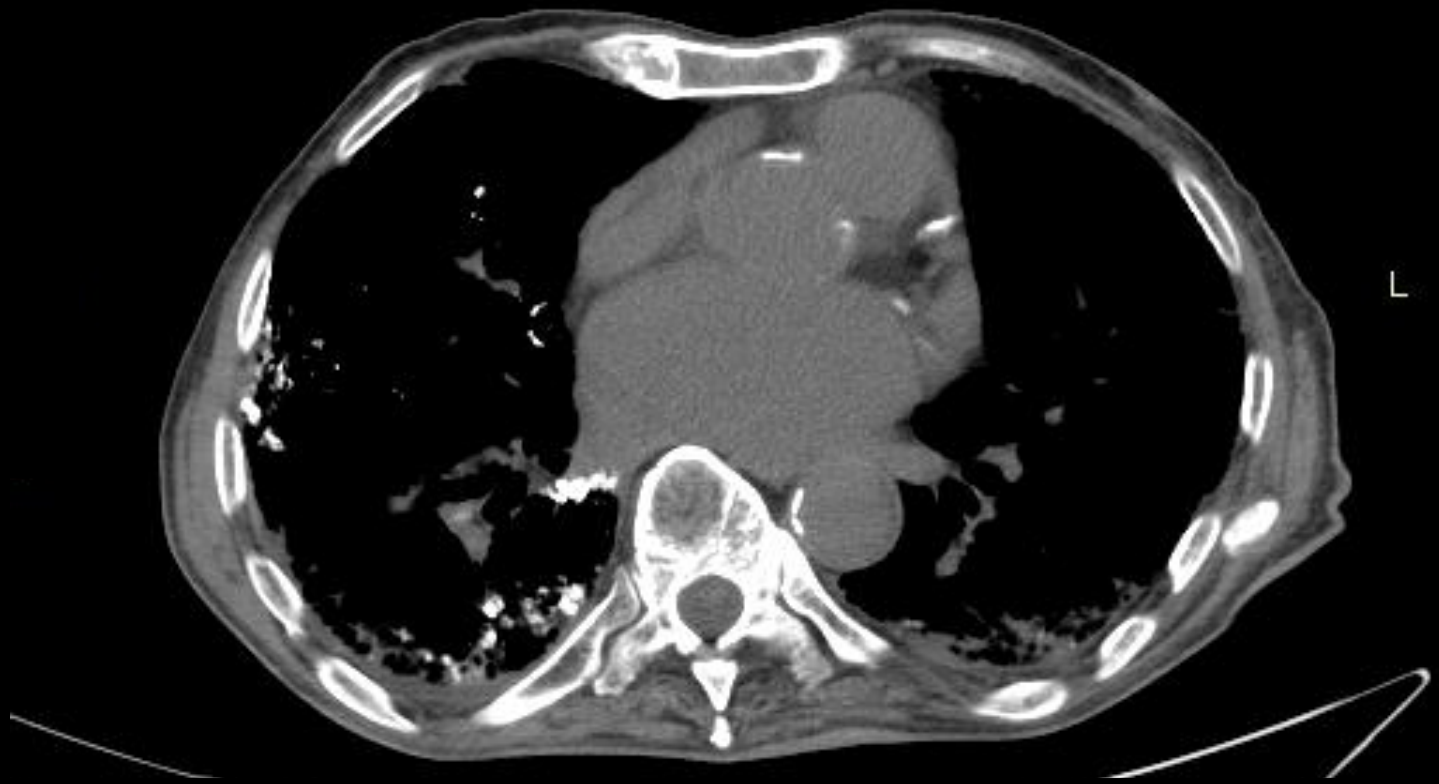
L

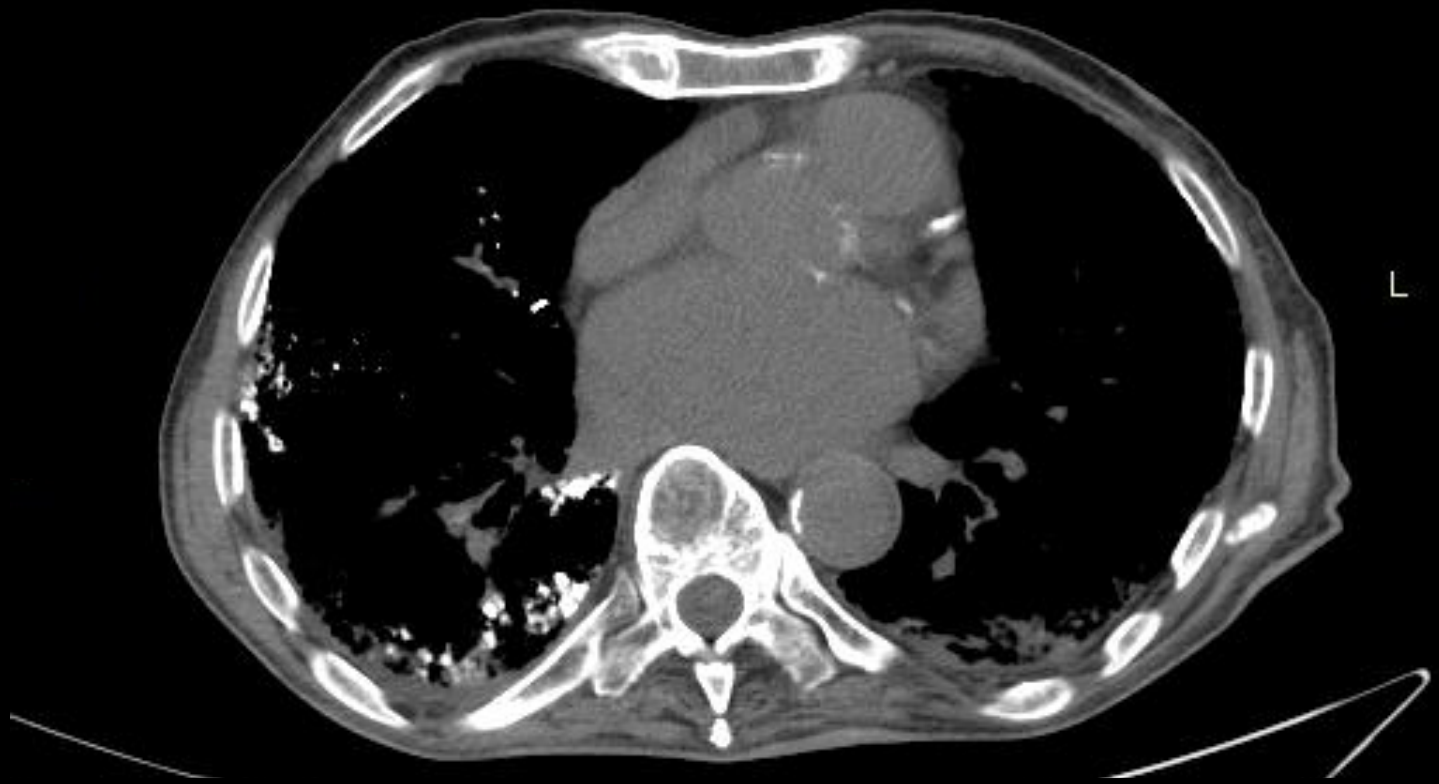
L

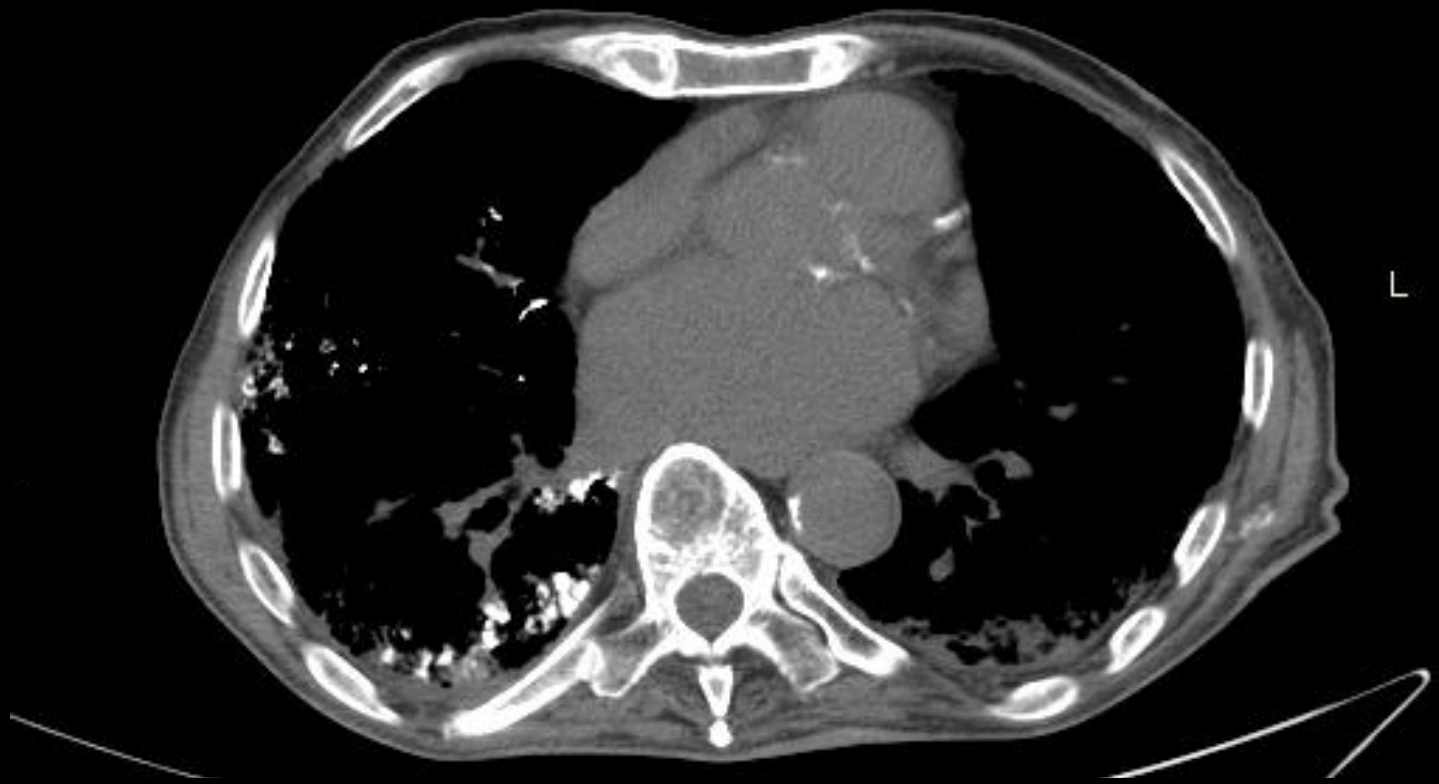
L

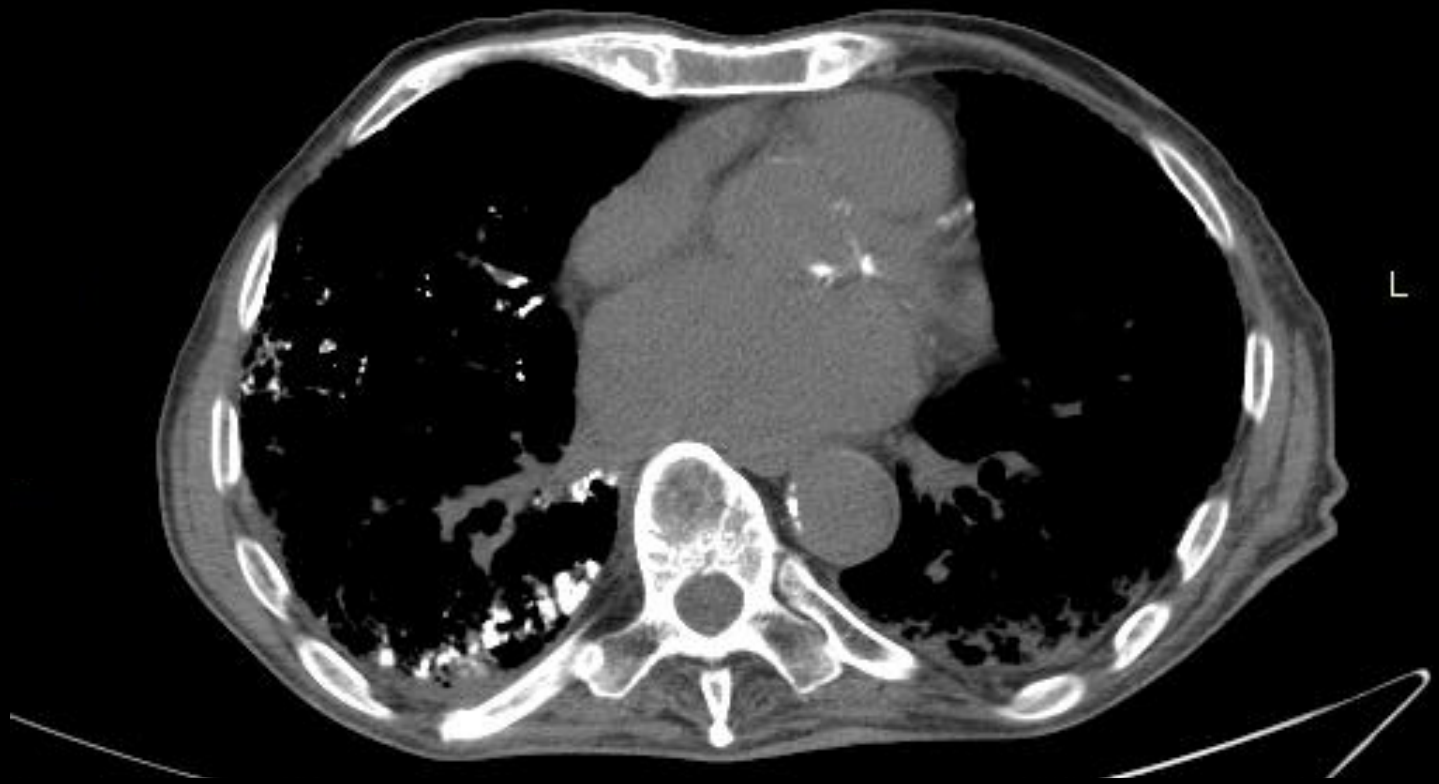
L

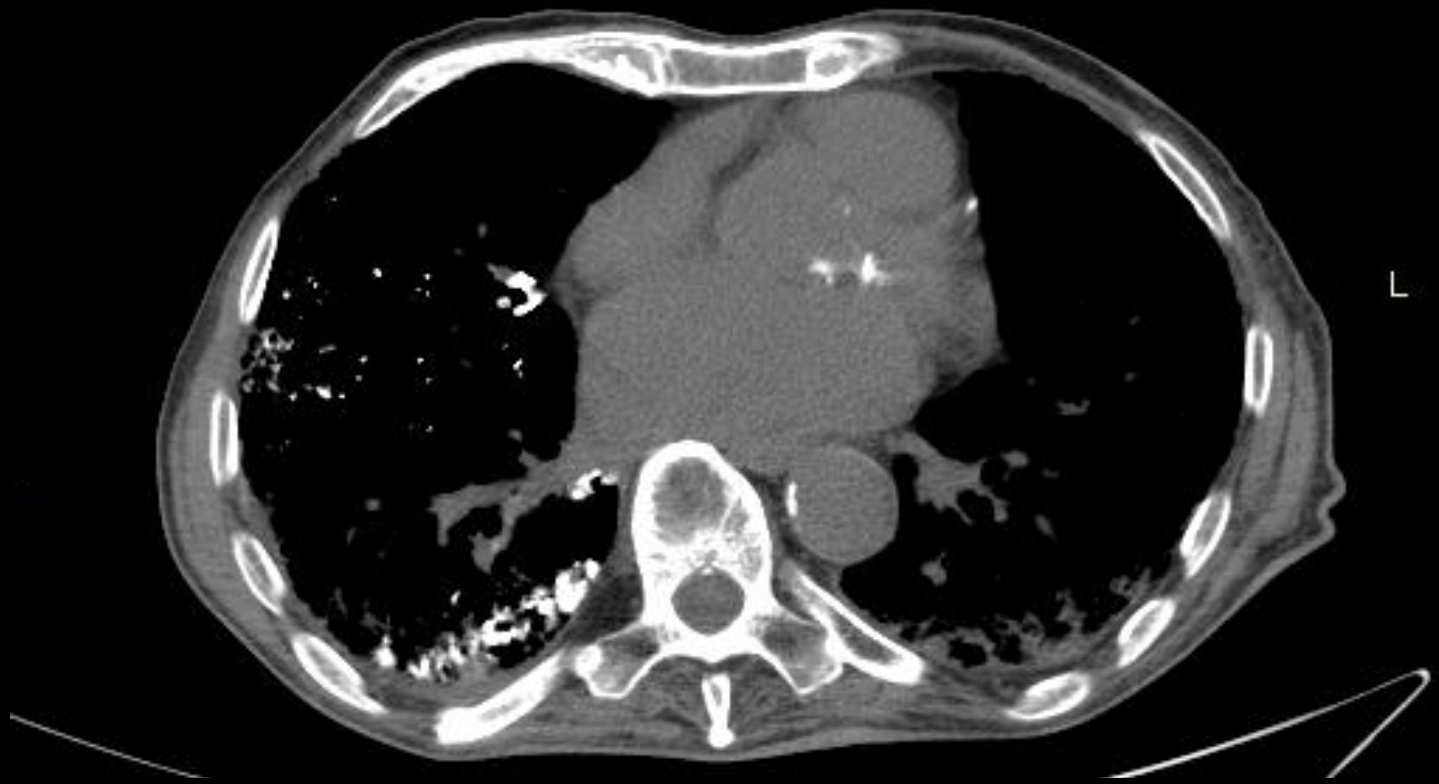
L

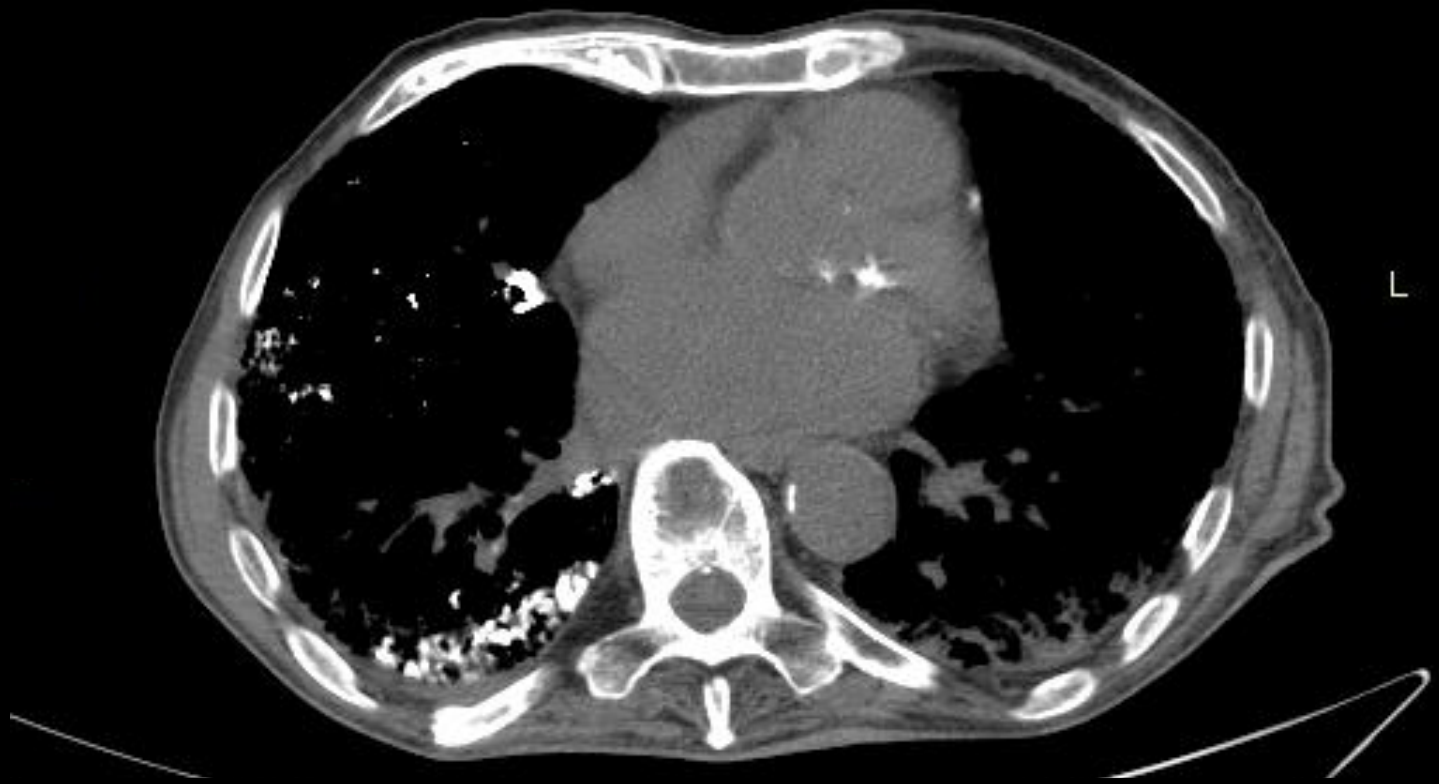
L

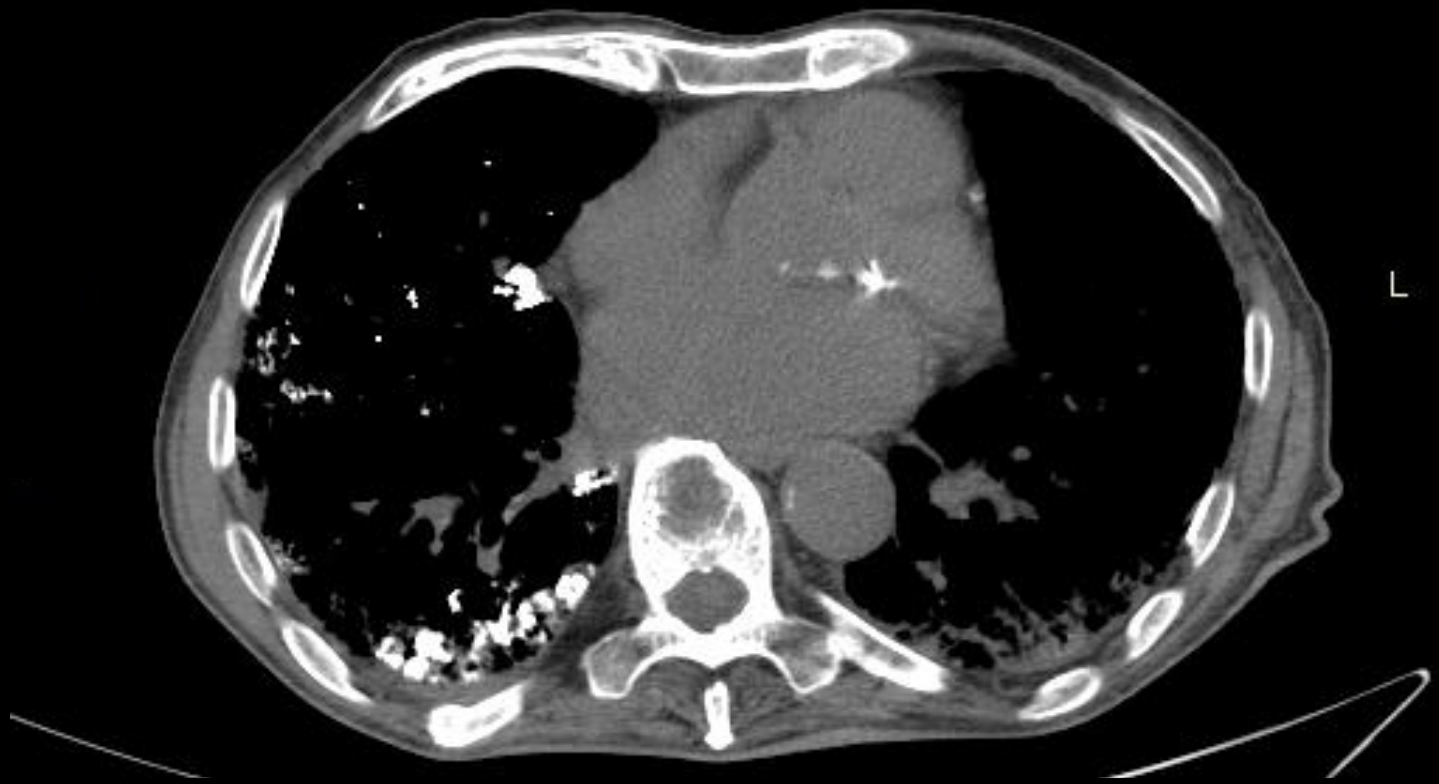
L

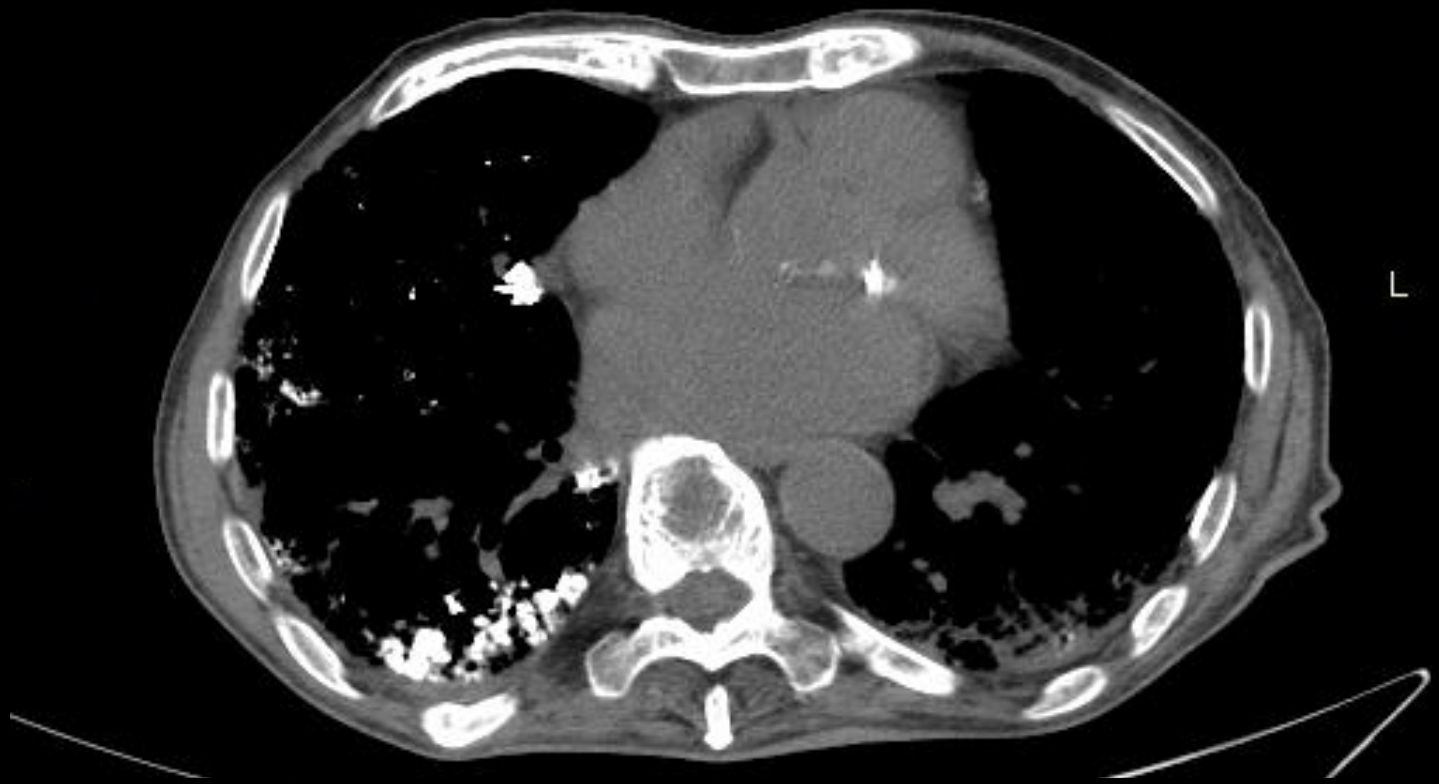
L

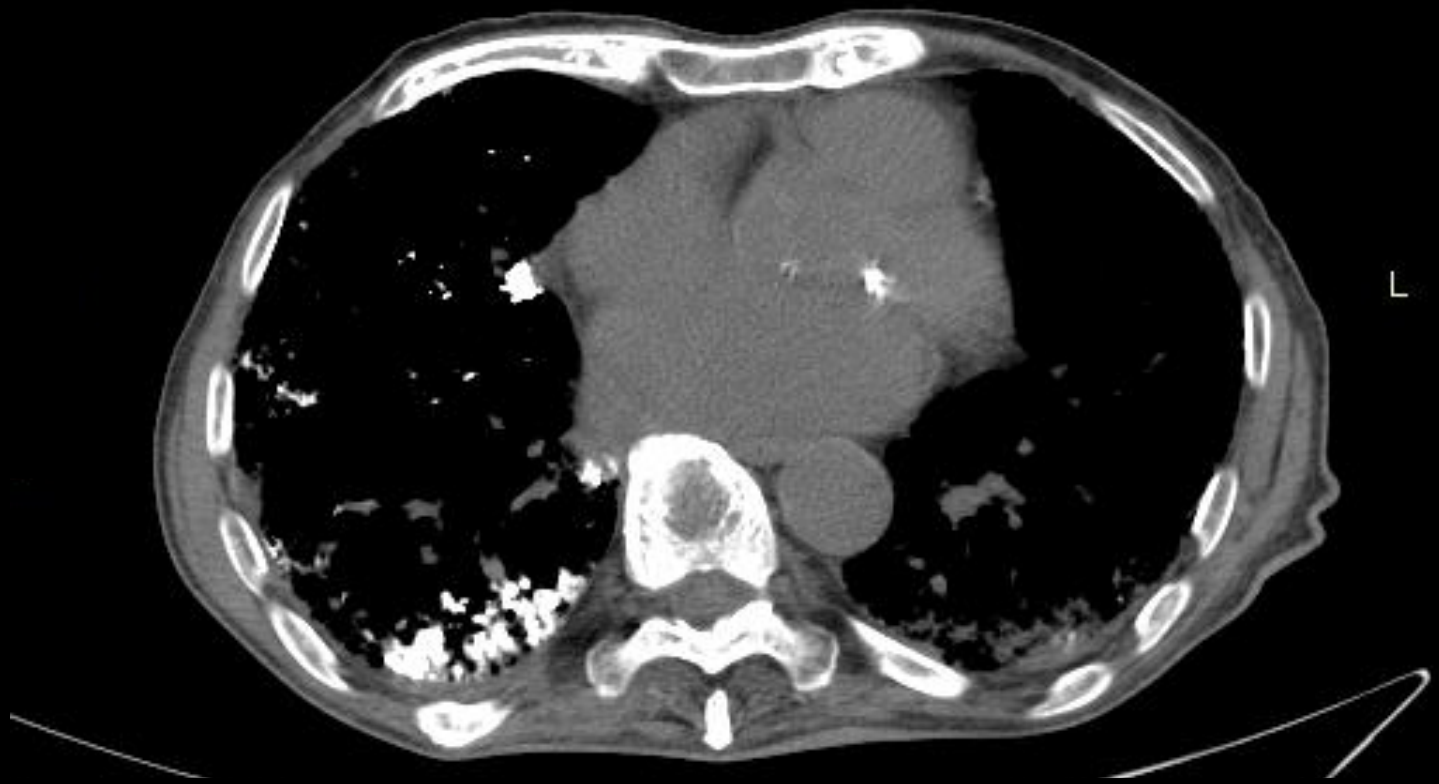
L

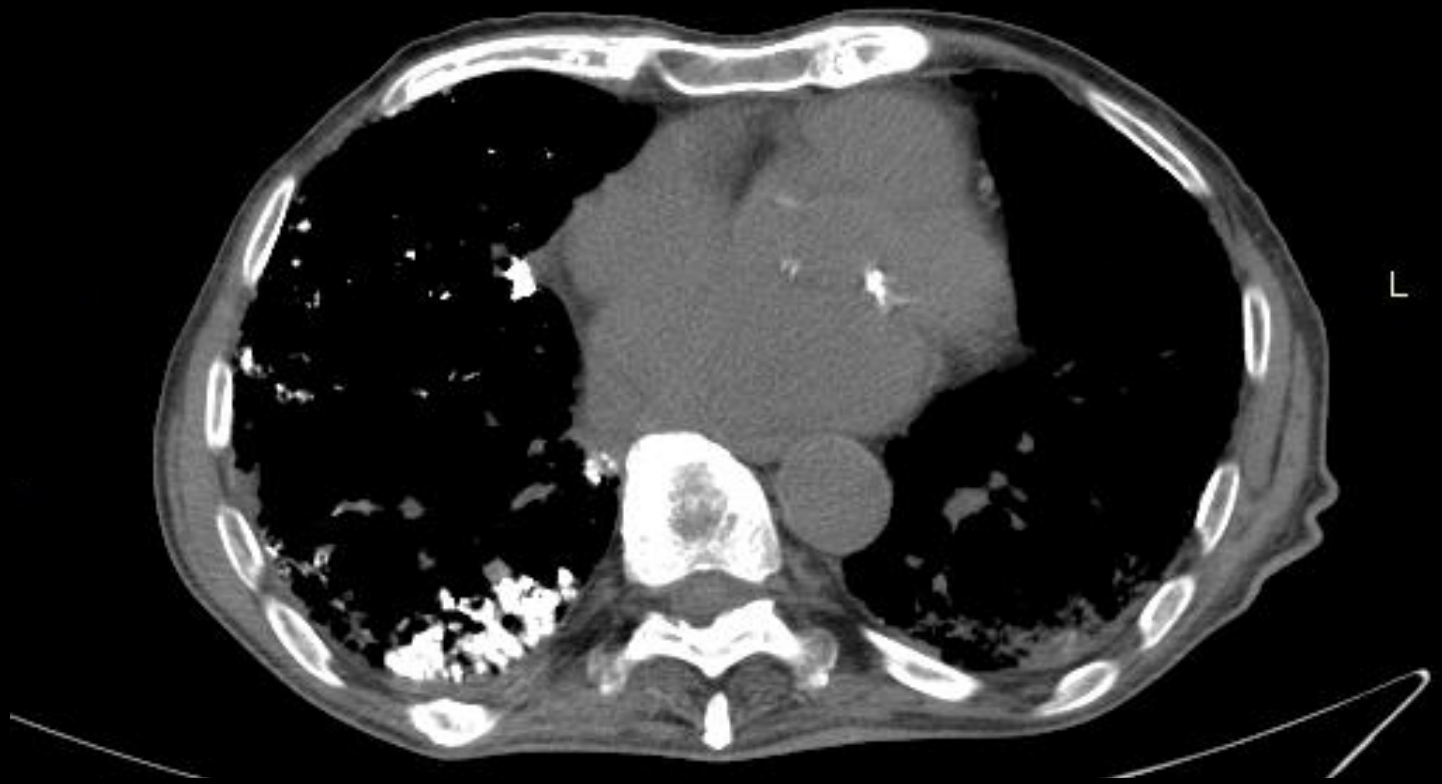
L

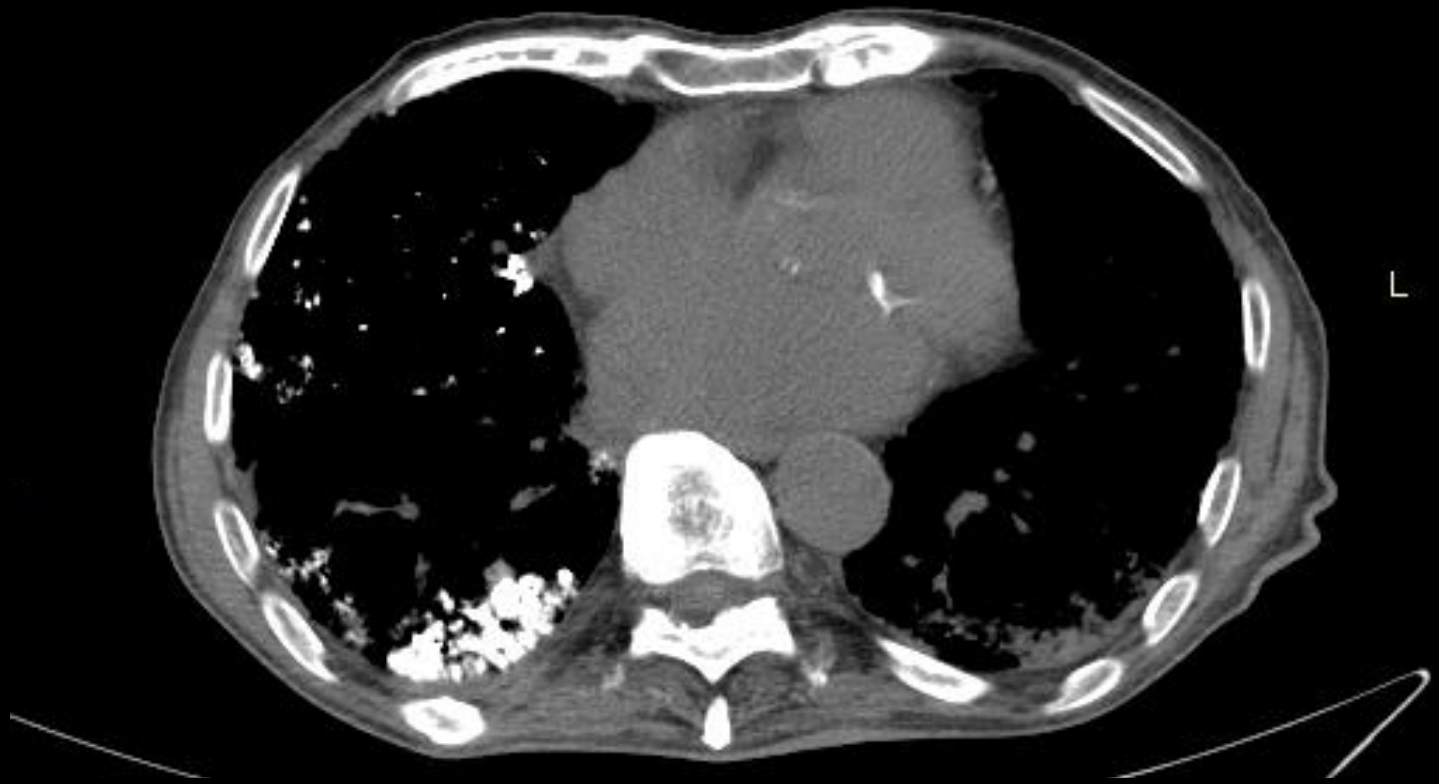
L

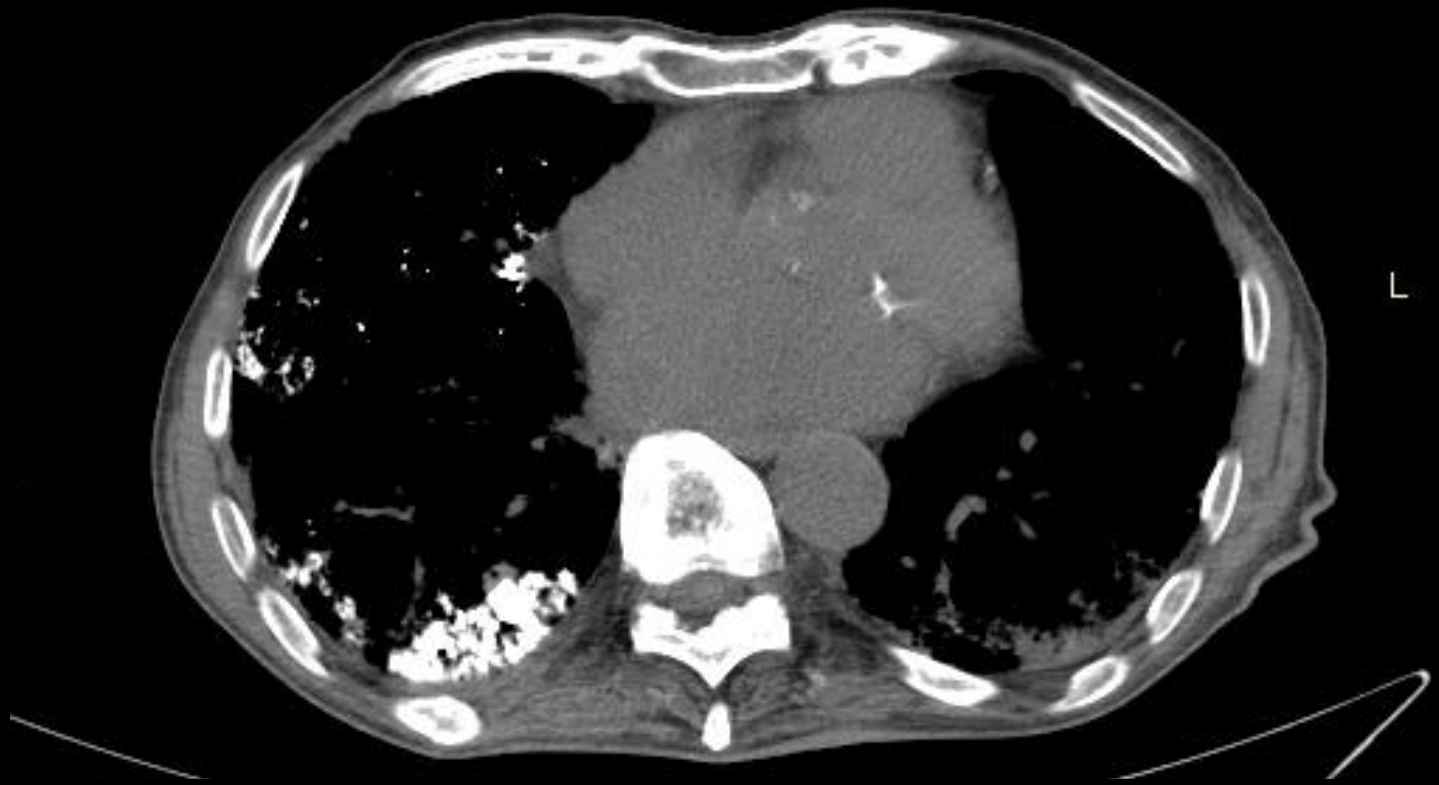
L

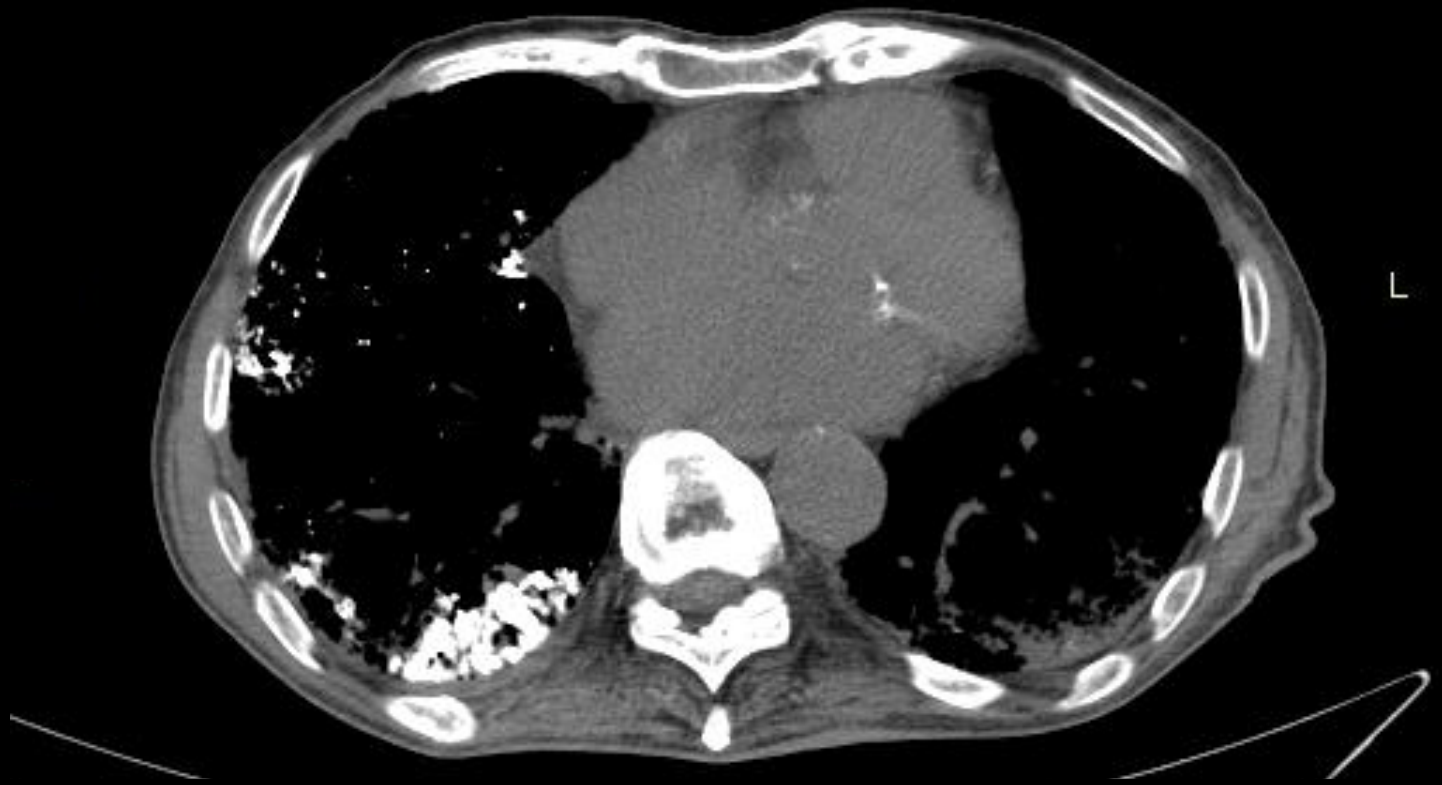
L

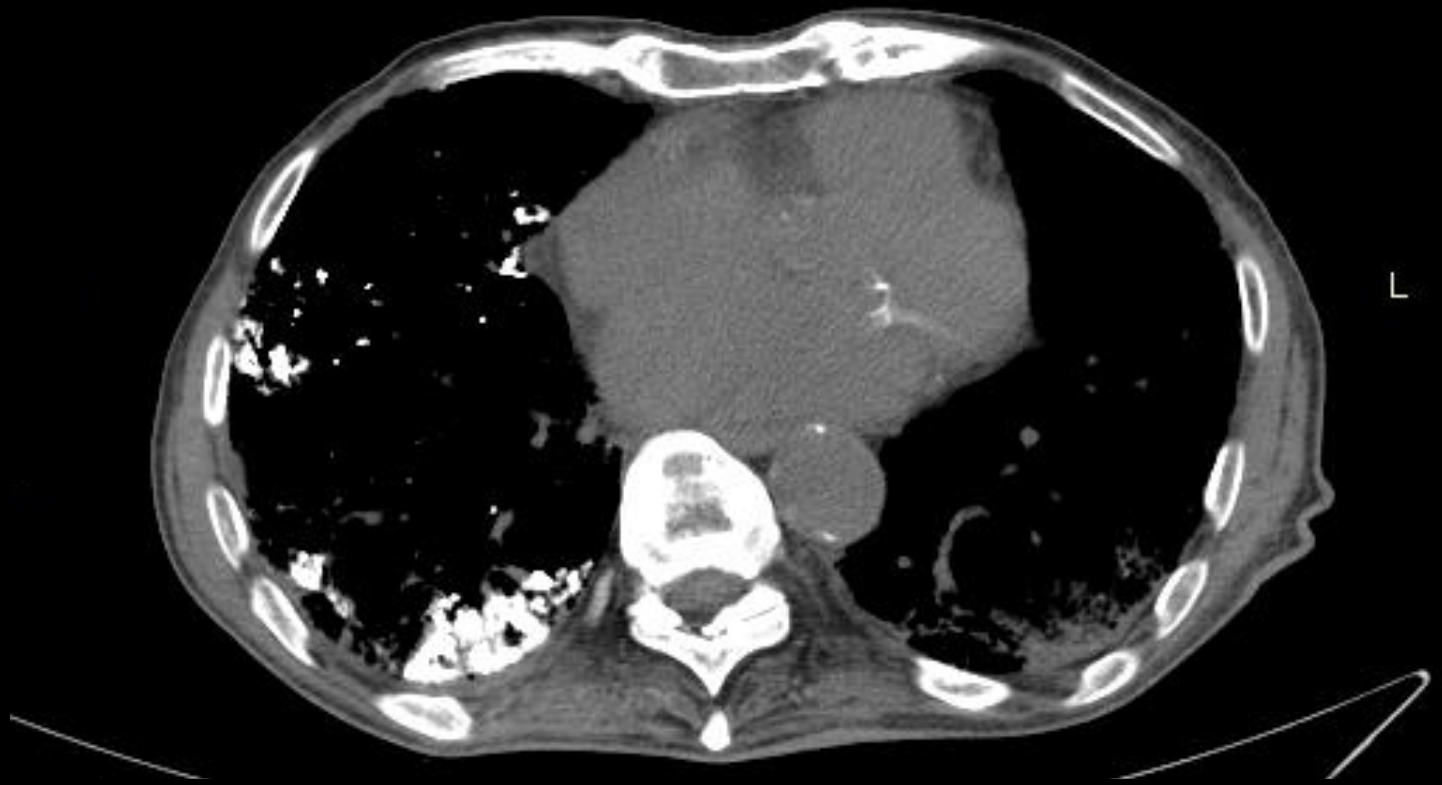
L

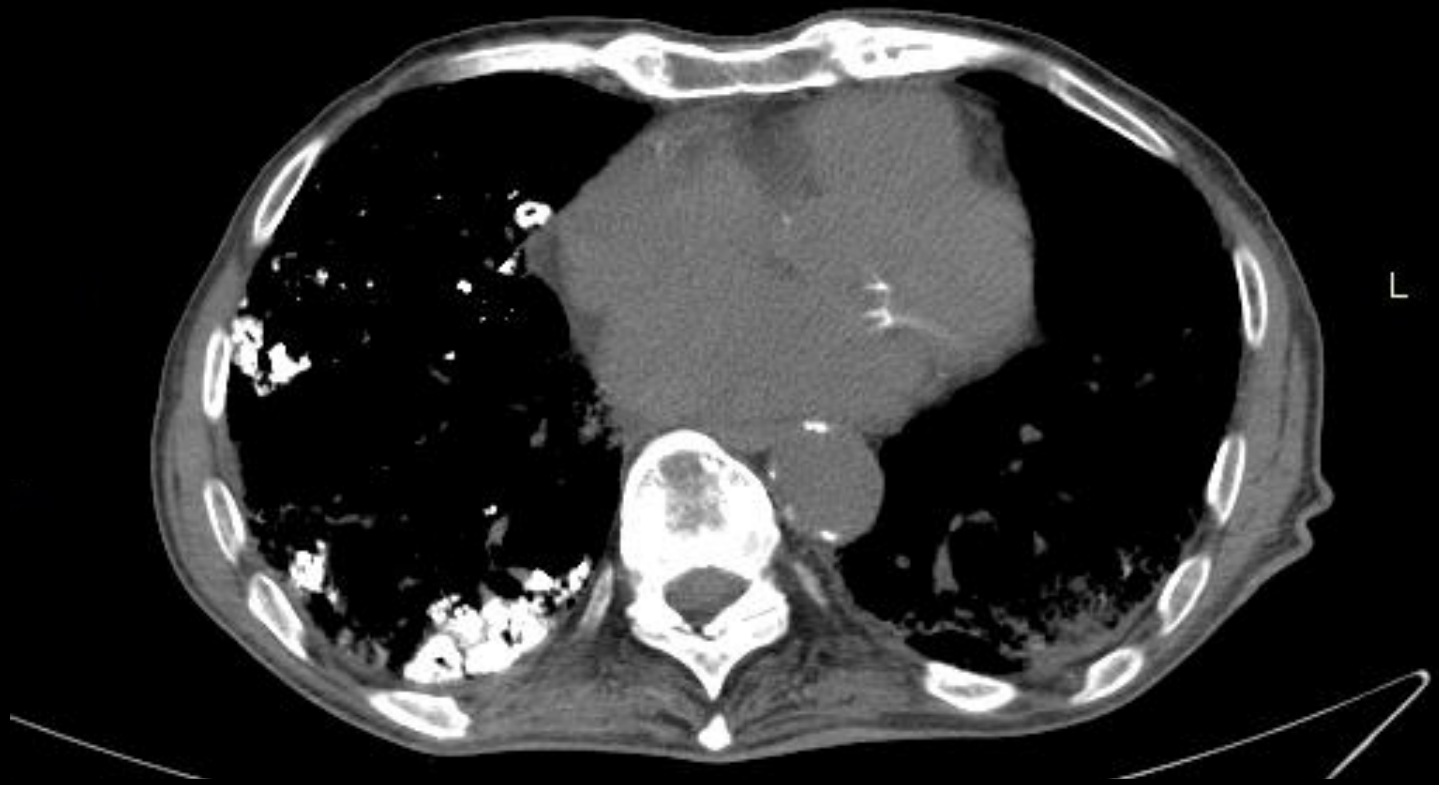
L

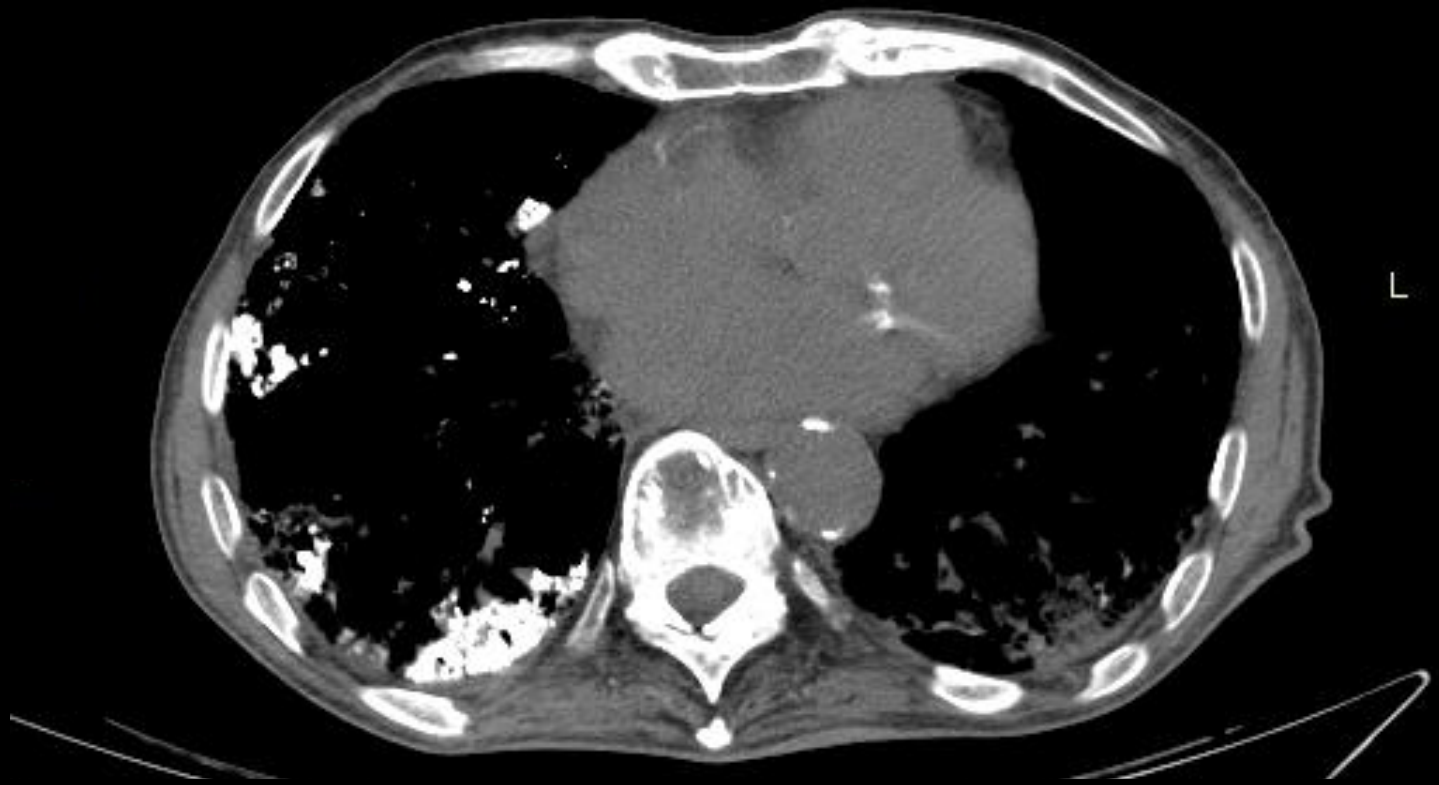
L

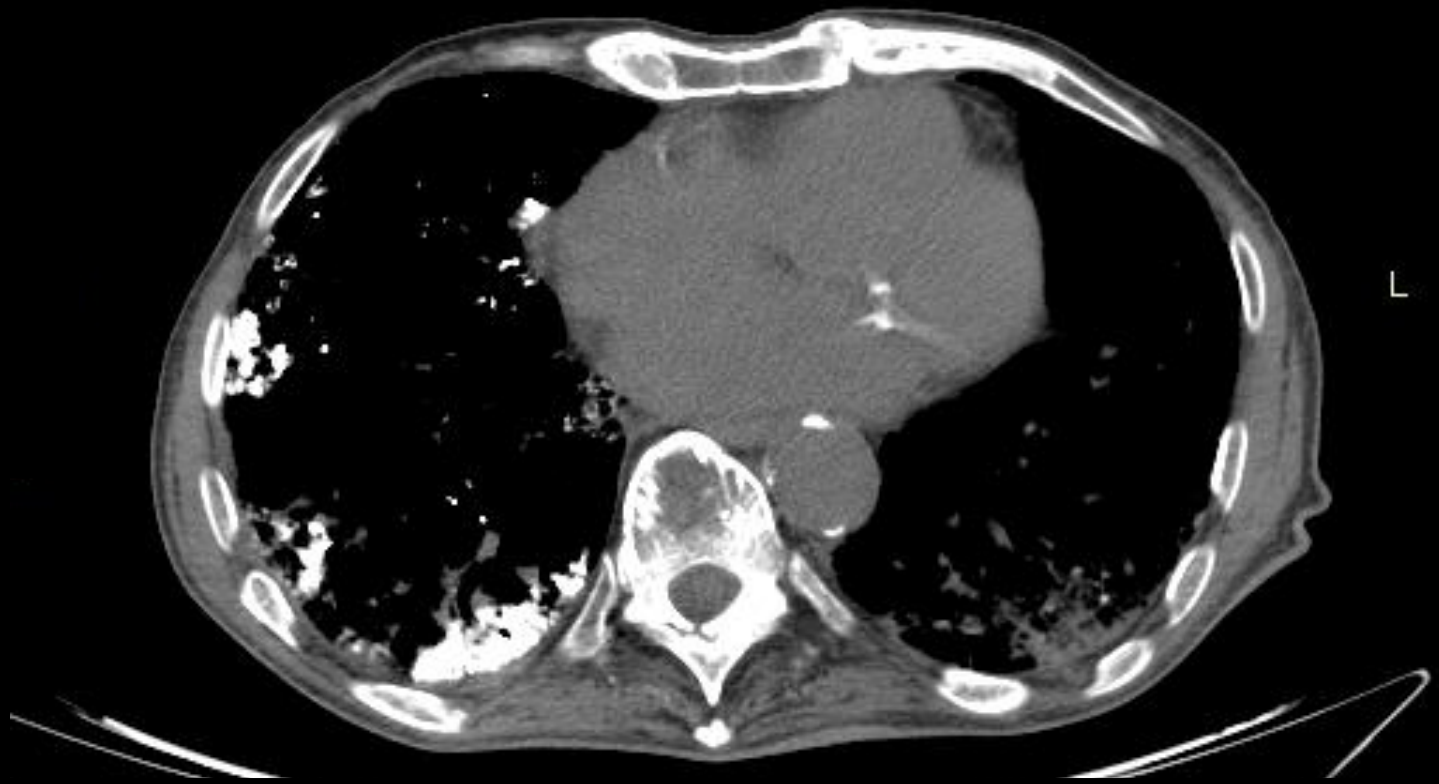
L

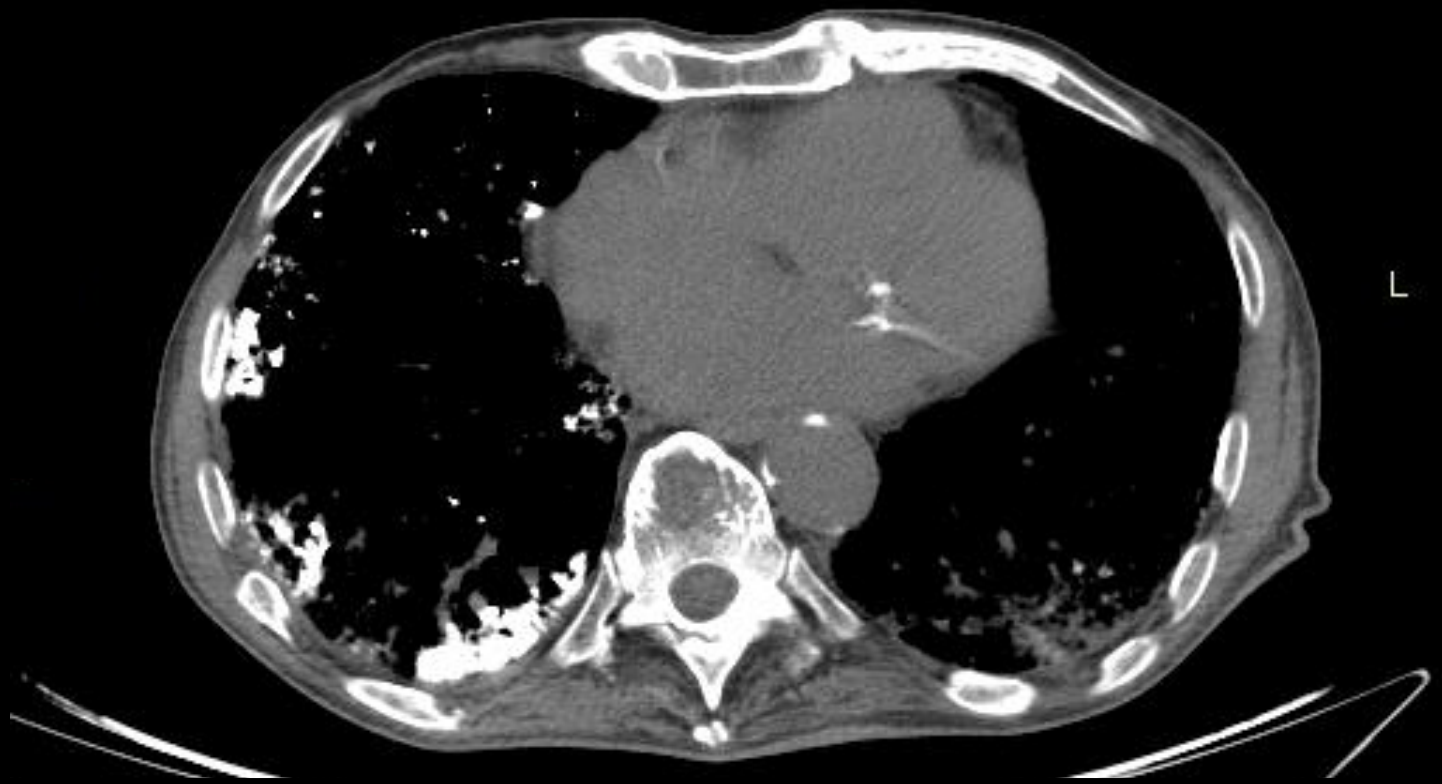
L

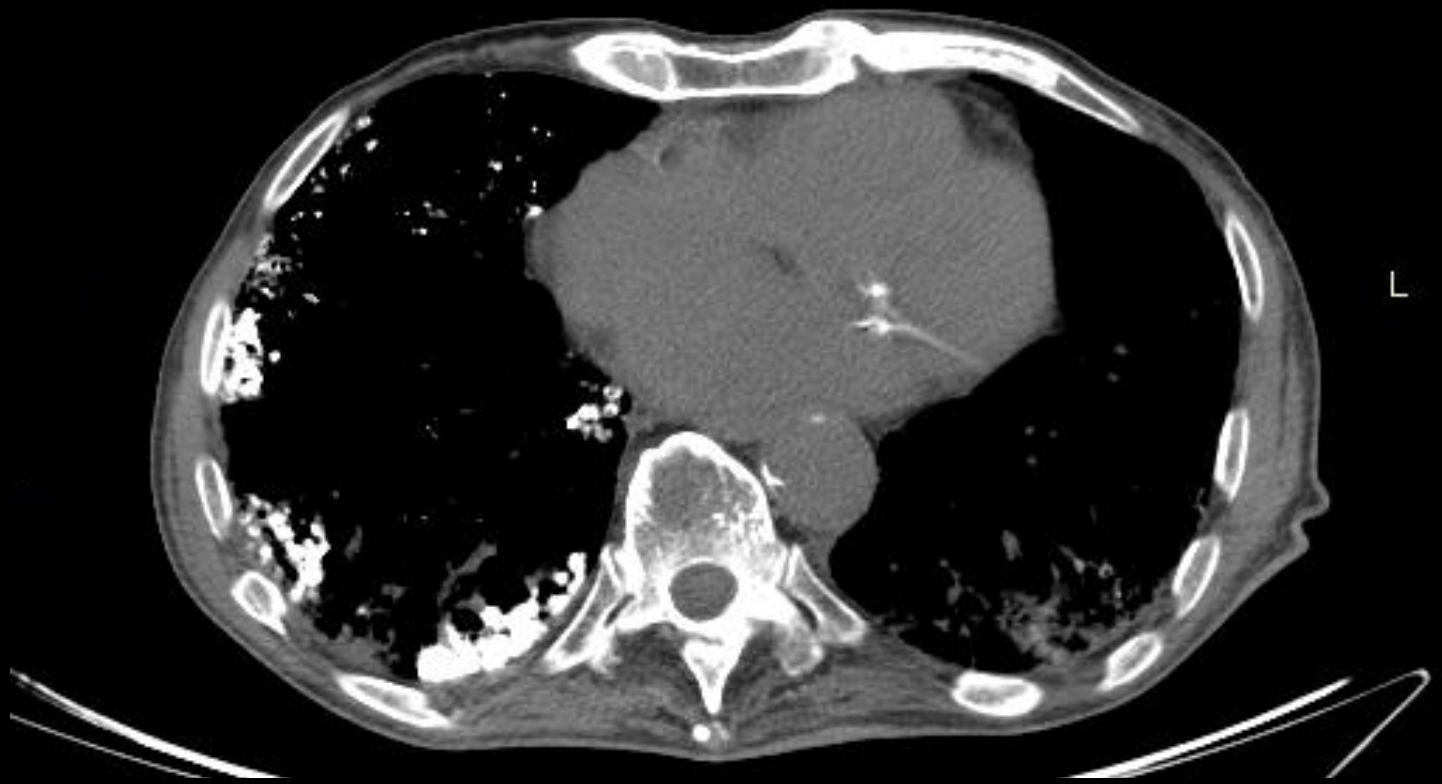
L

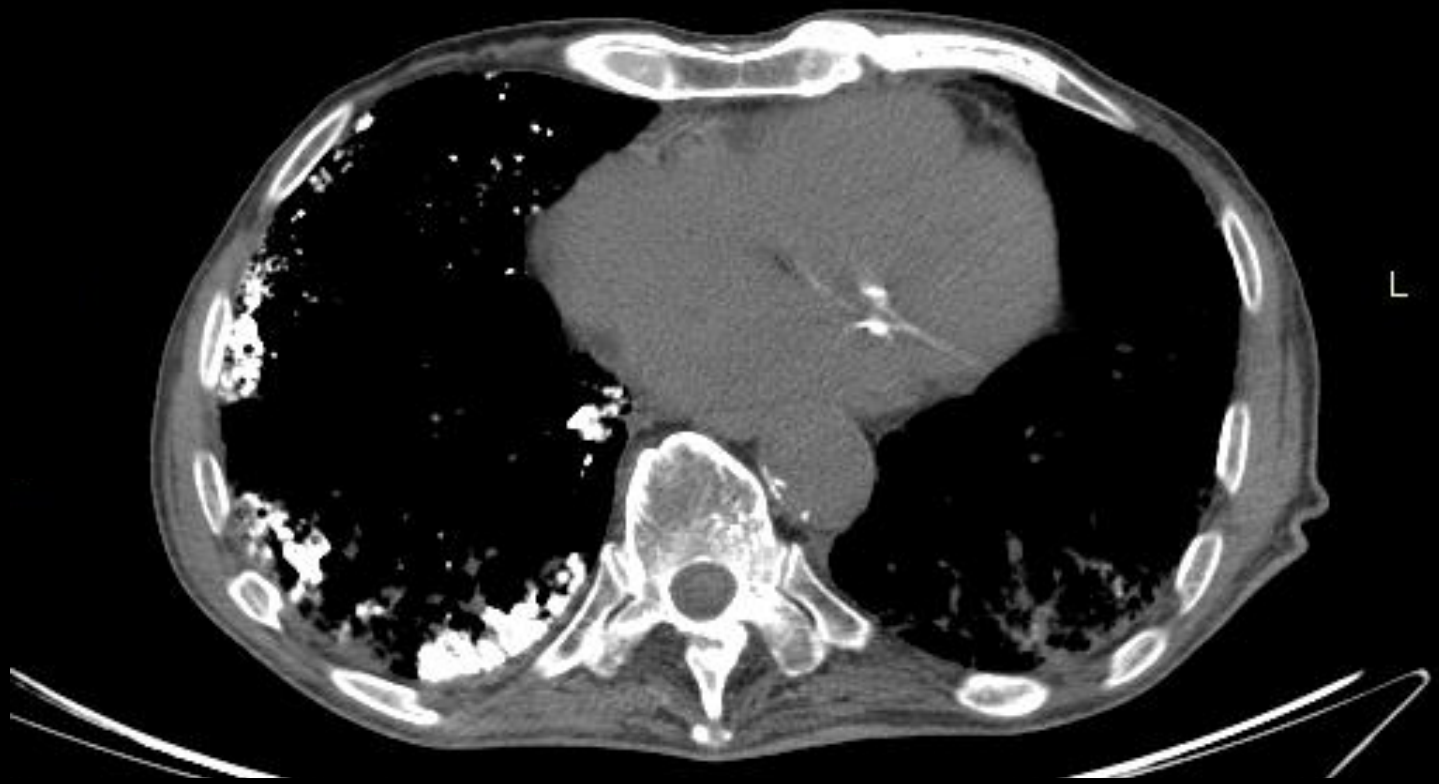
L

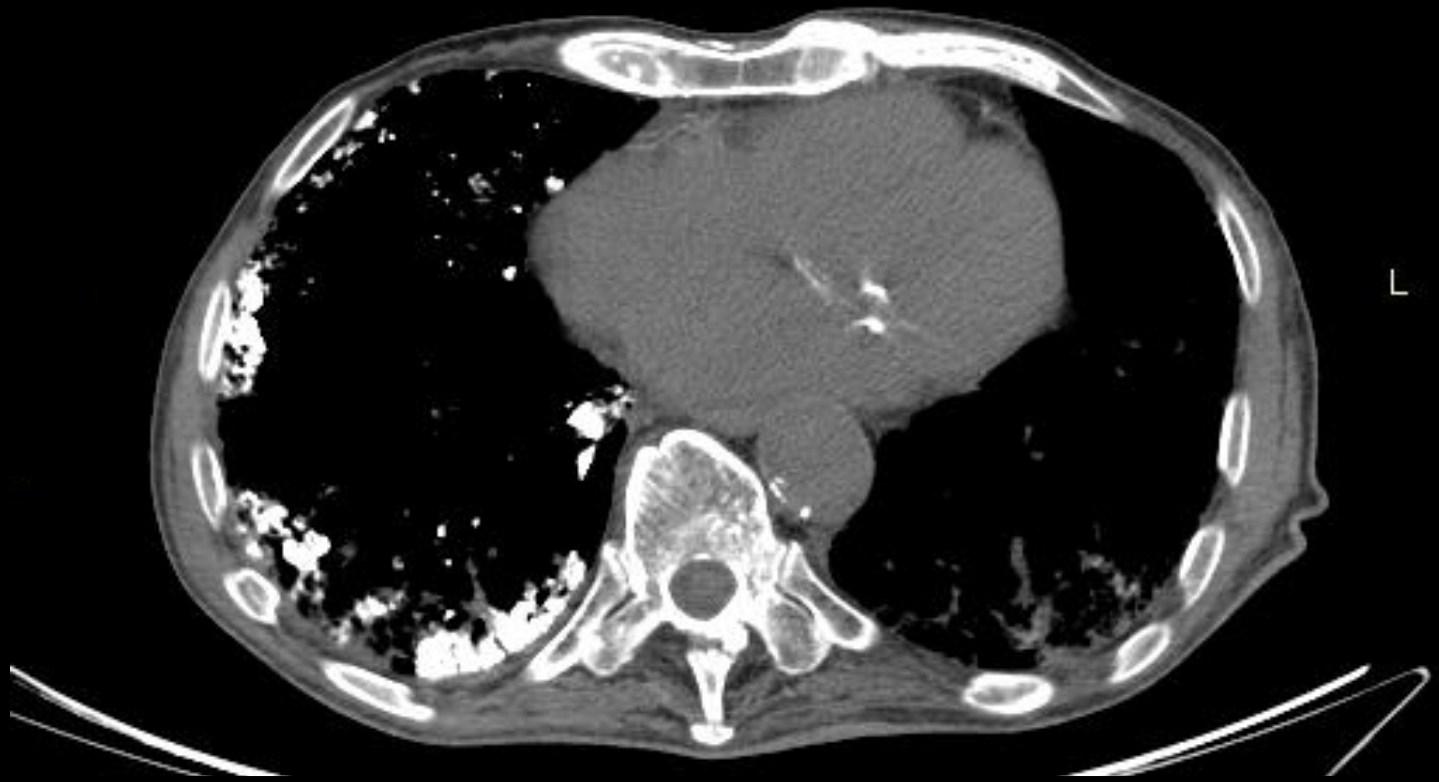
L

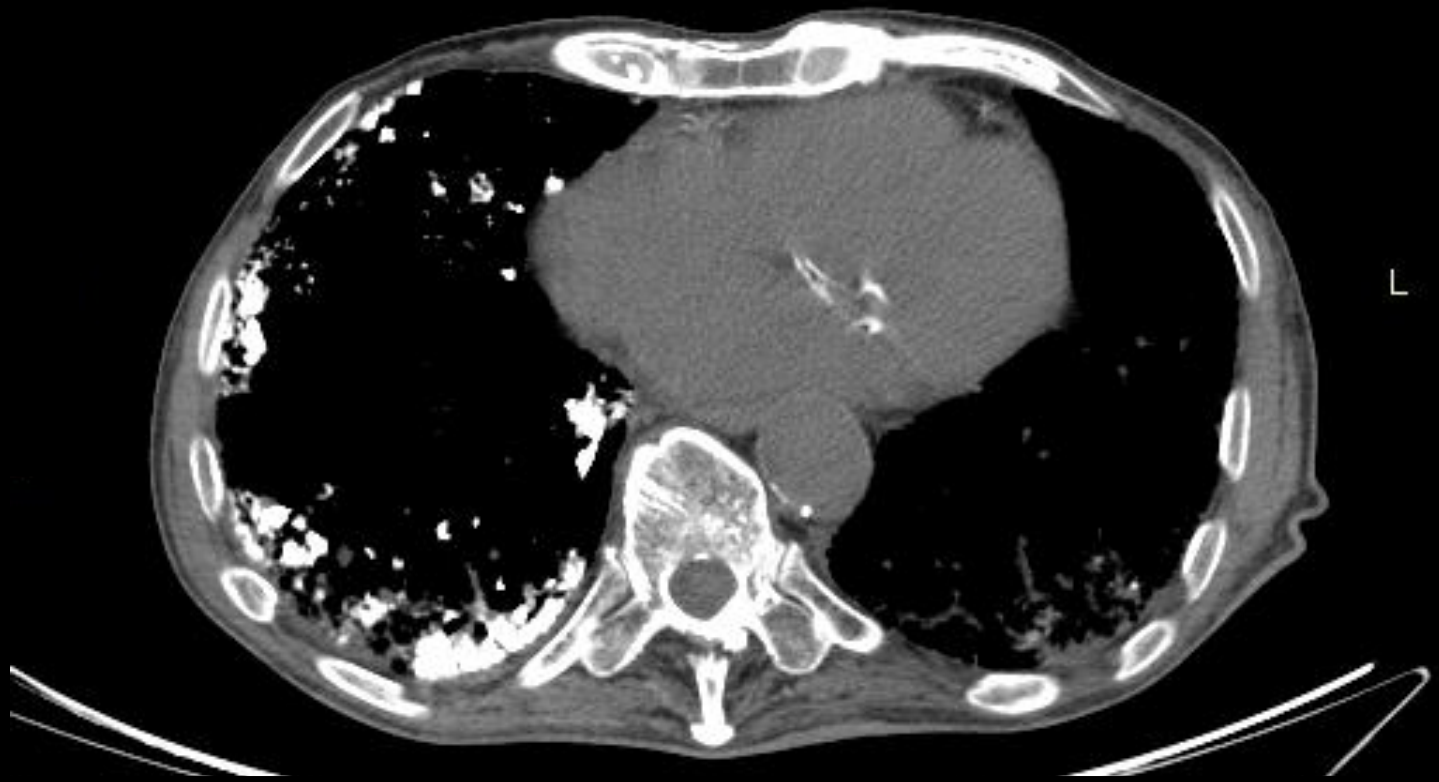
L

L

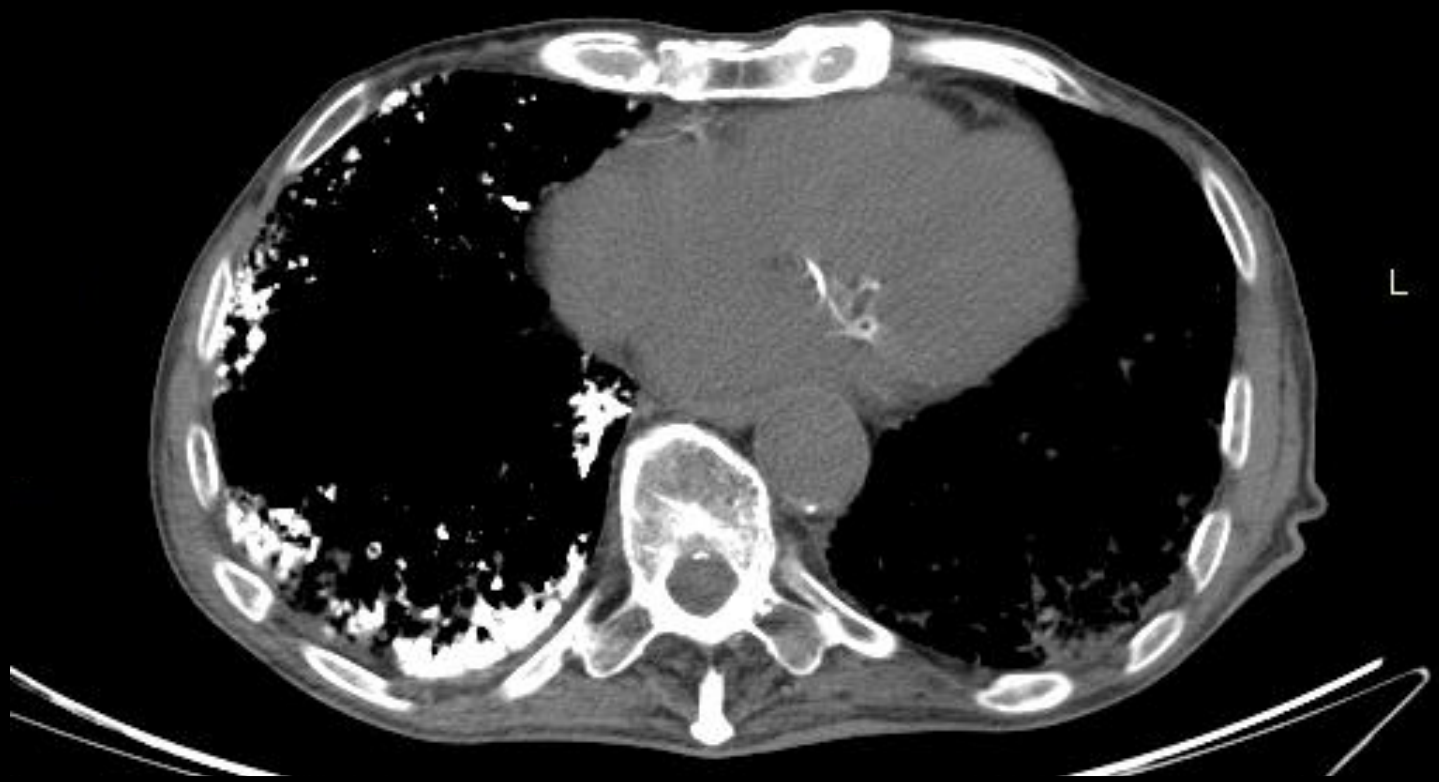
L

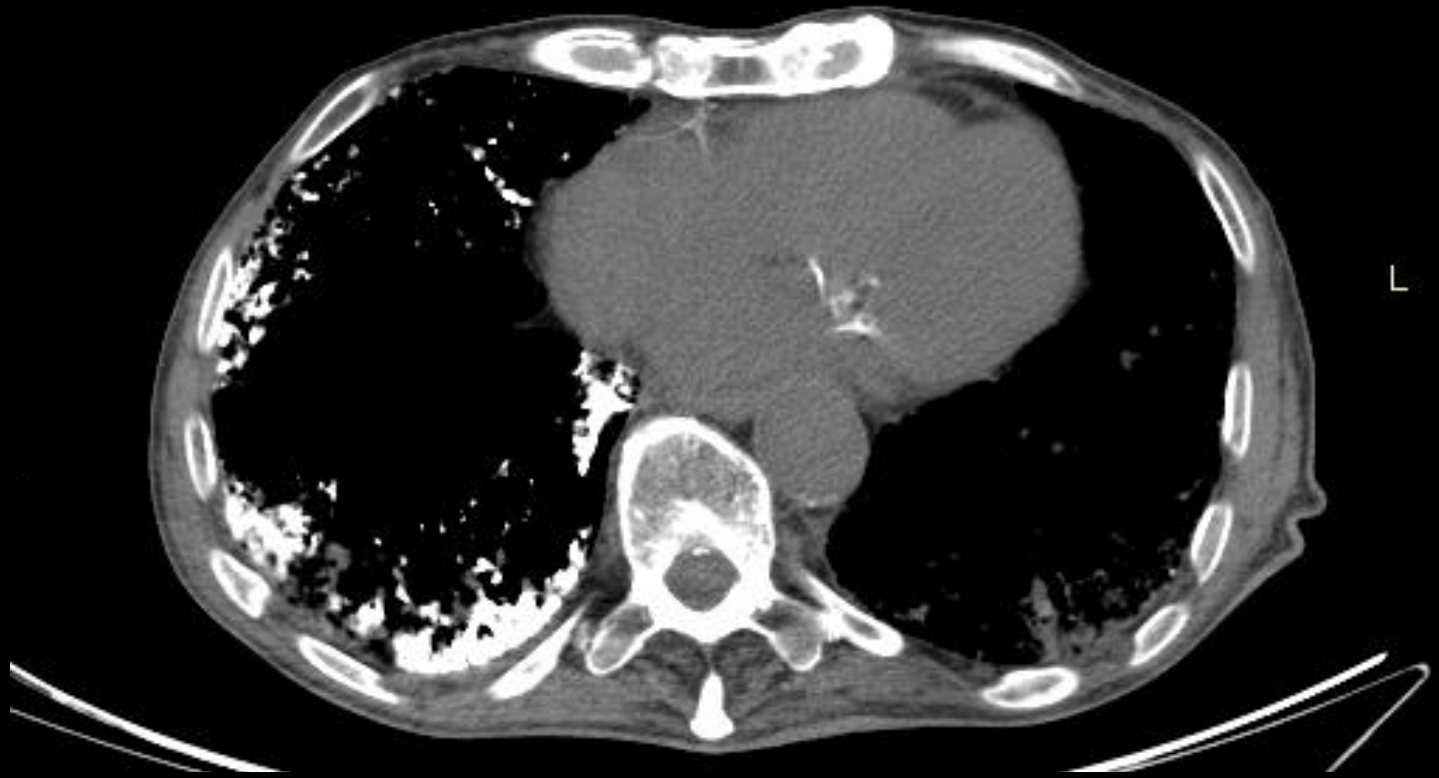
L

L

L

L

L

L

L

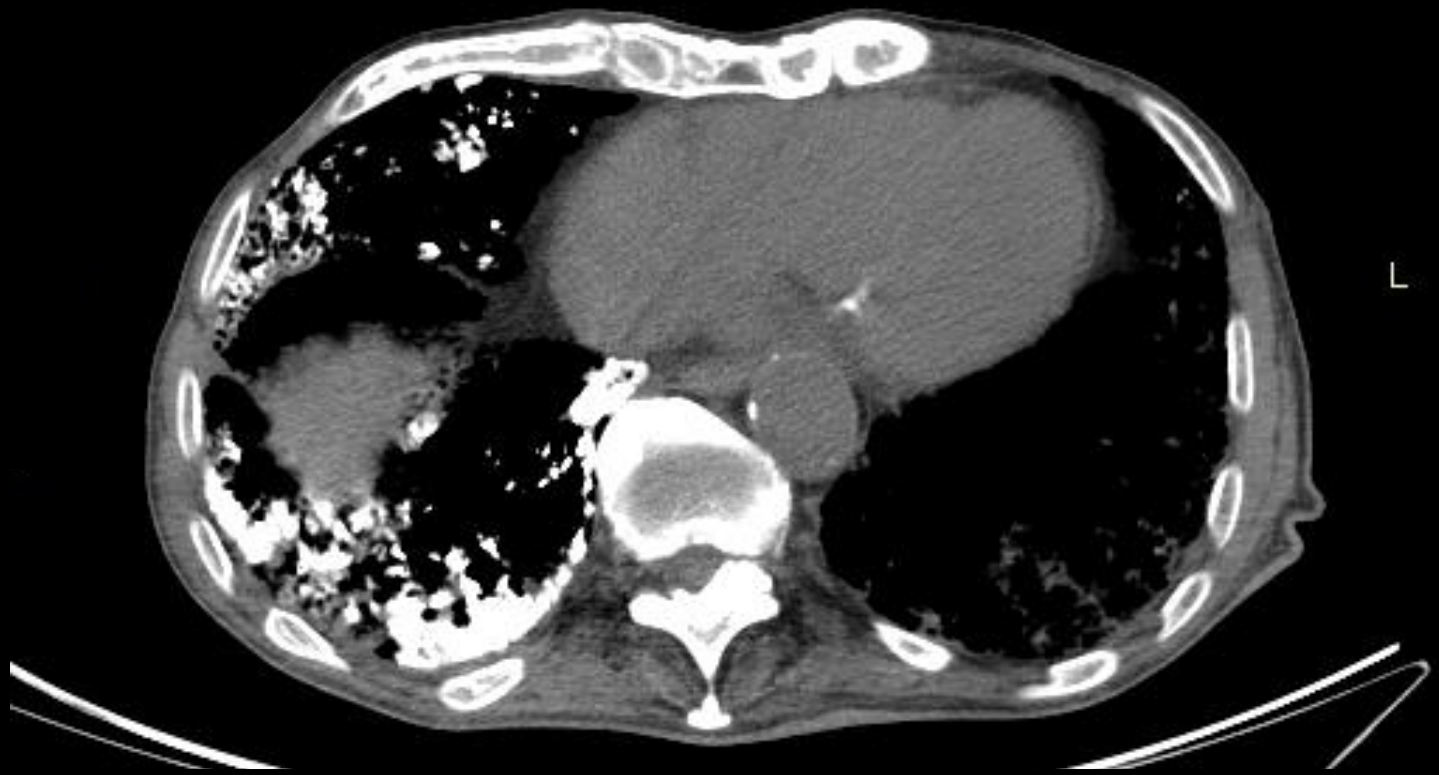
L

L

L

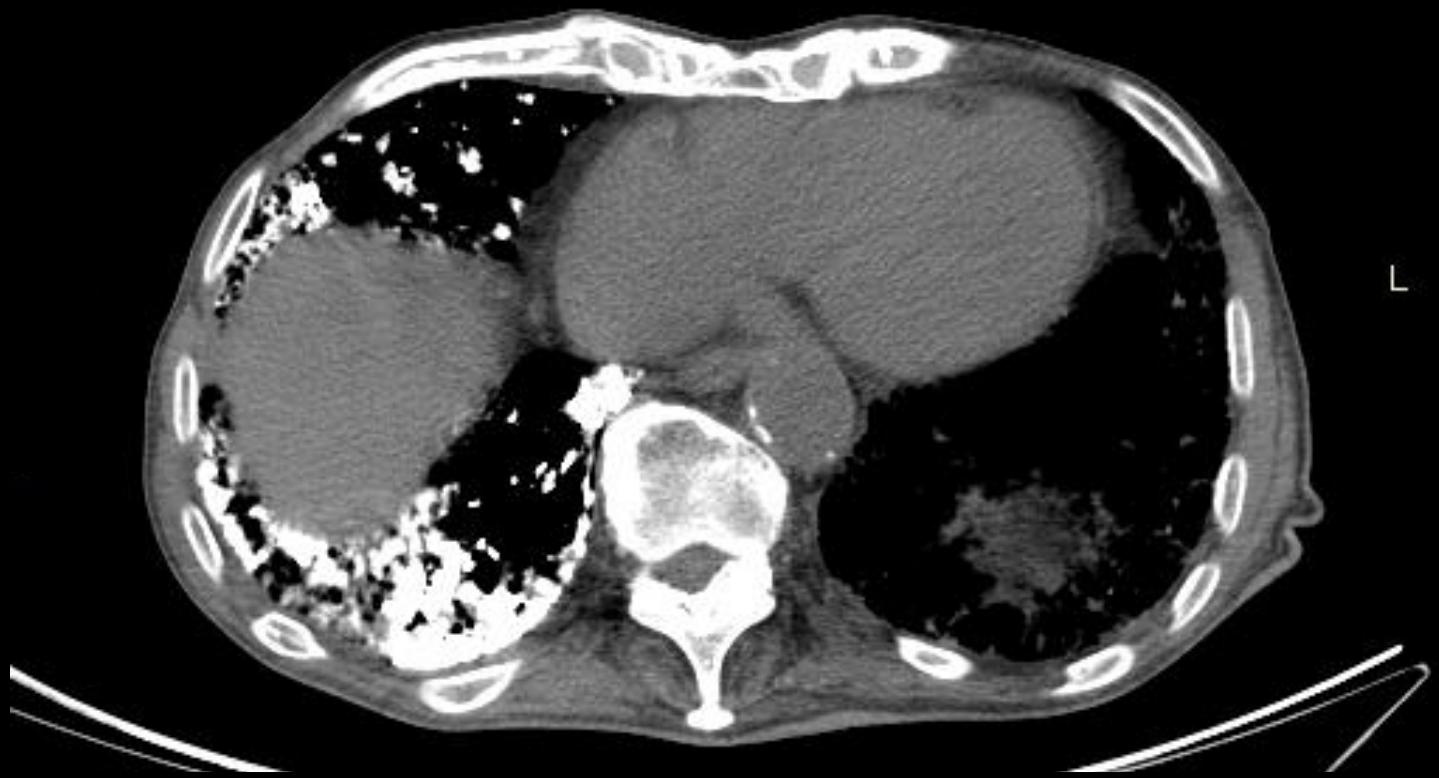
L

L

L

L

L

L

L

L

L

L

L

L

L

L

L

L

L

L

L

L

L

L

L

L

L

L

L

L

L

L

L

L

L

L

L

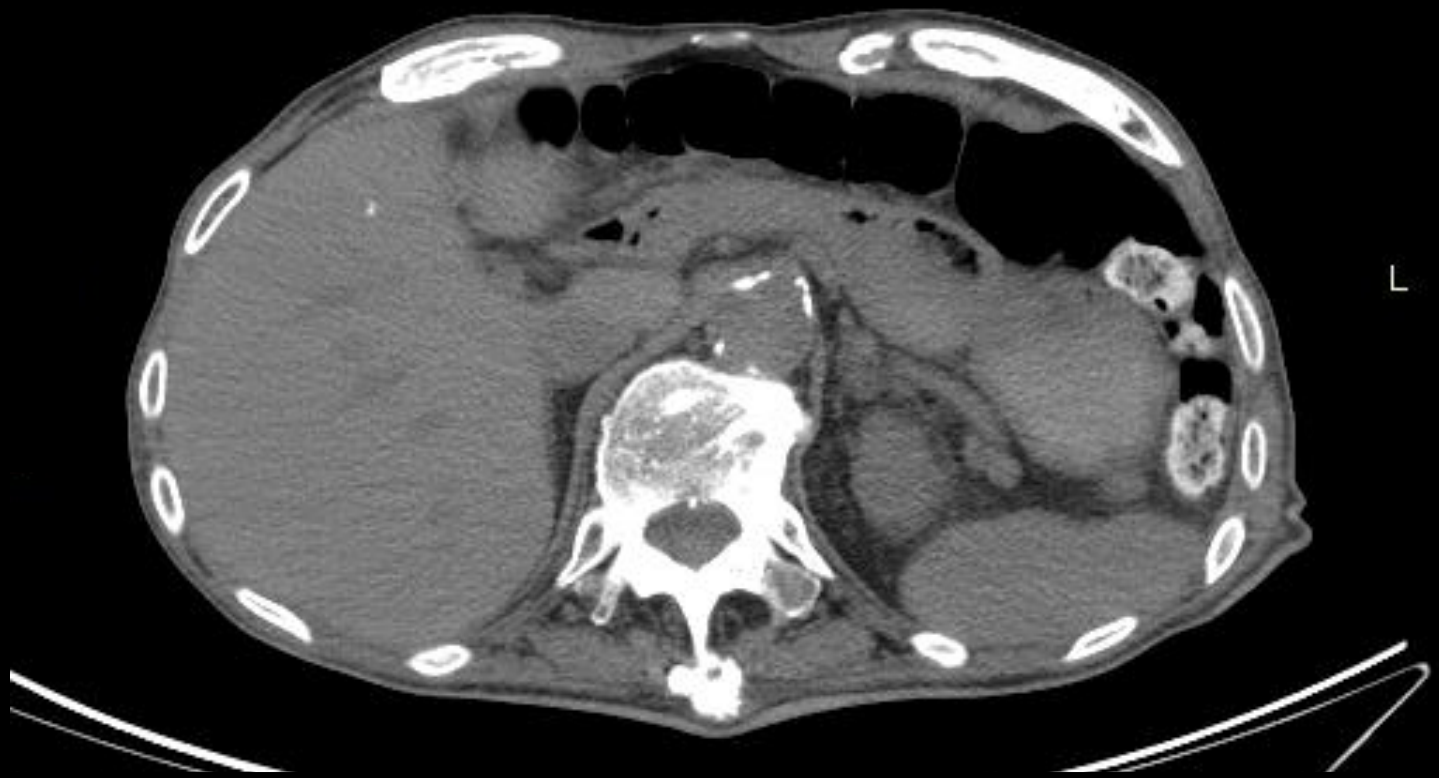
L

L

L

L

L

L

L

L

L

L

L

L

L

L

L

L

L

L

L

L

L

L

L

L

L

L

L

L

L

L

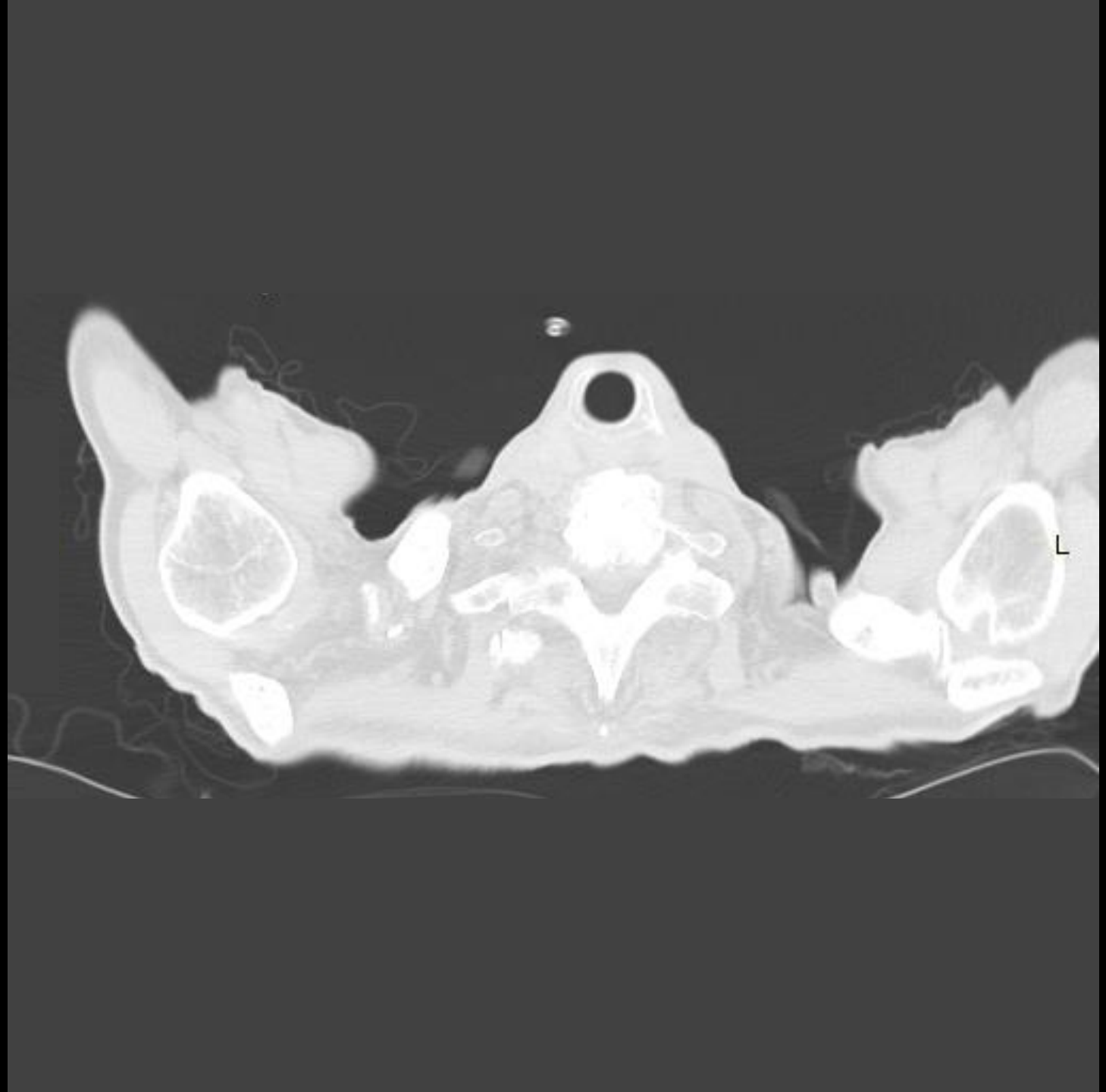
L

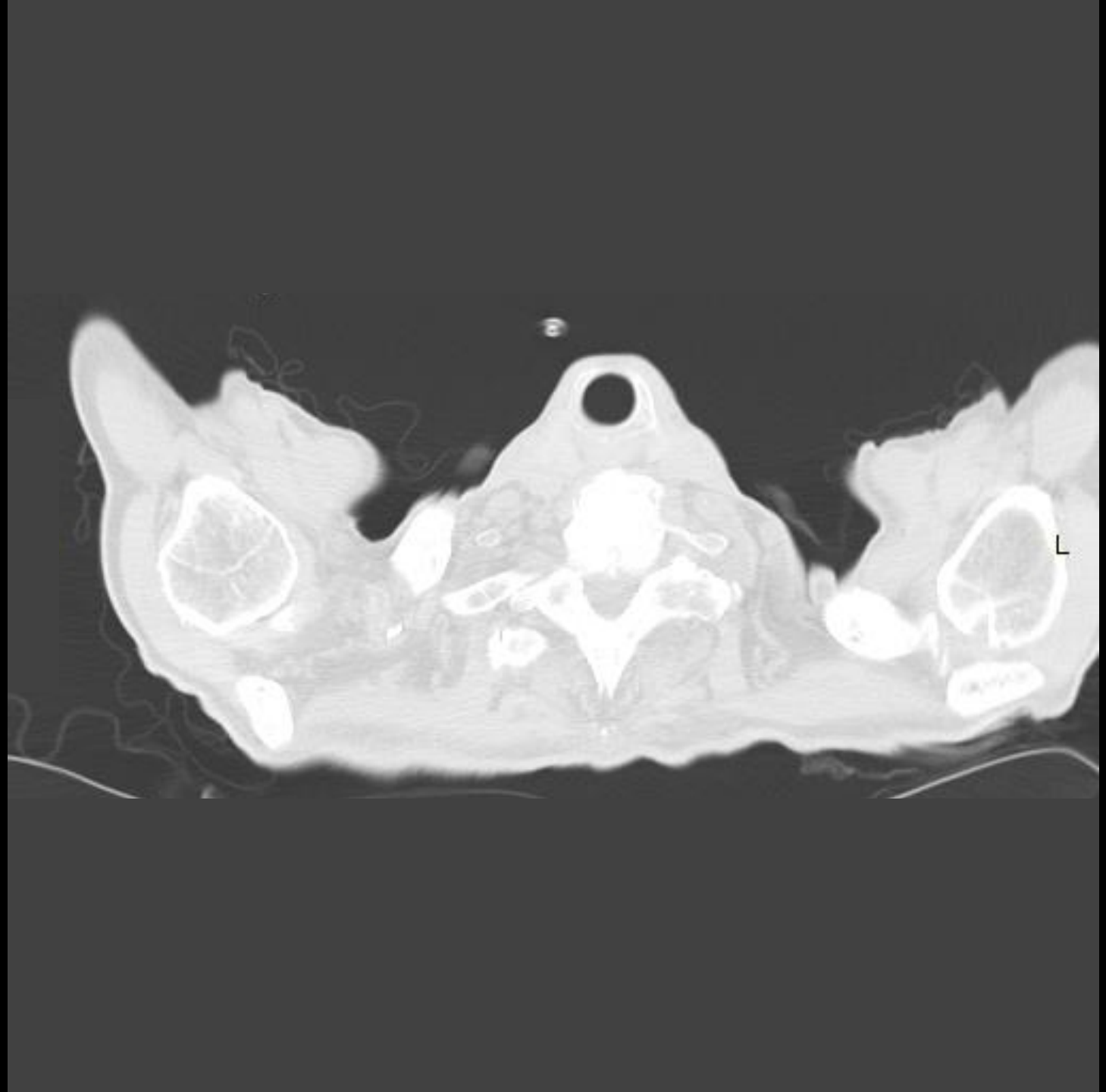
L

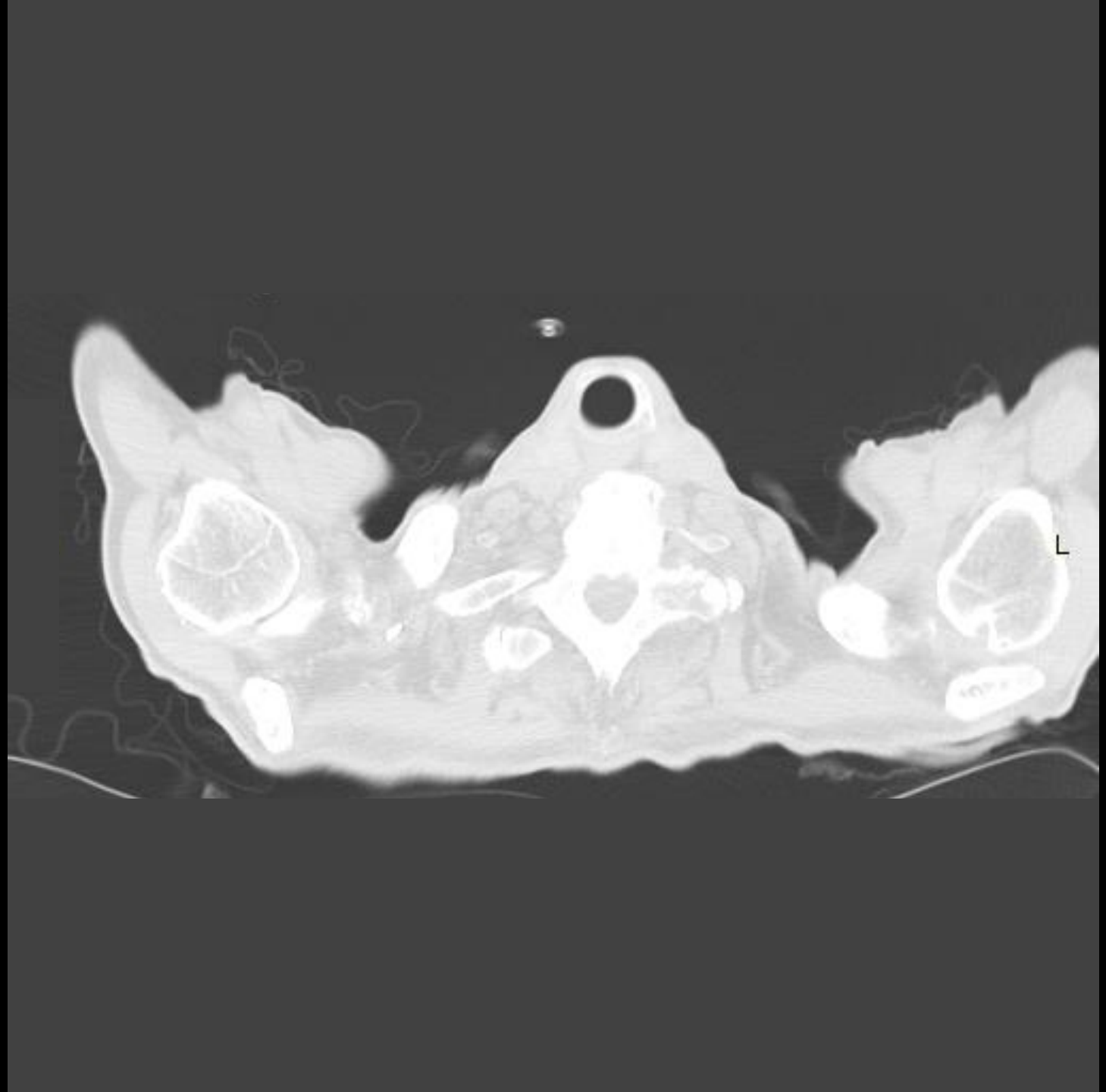
L

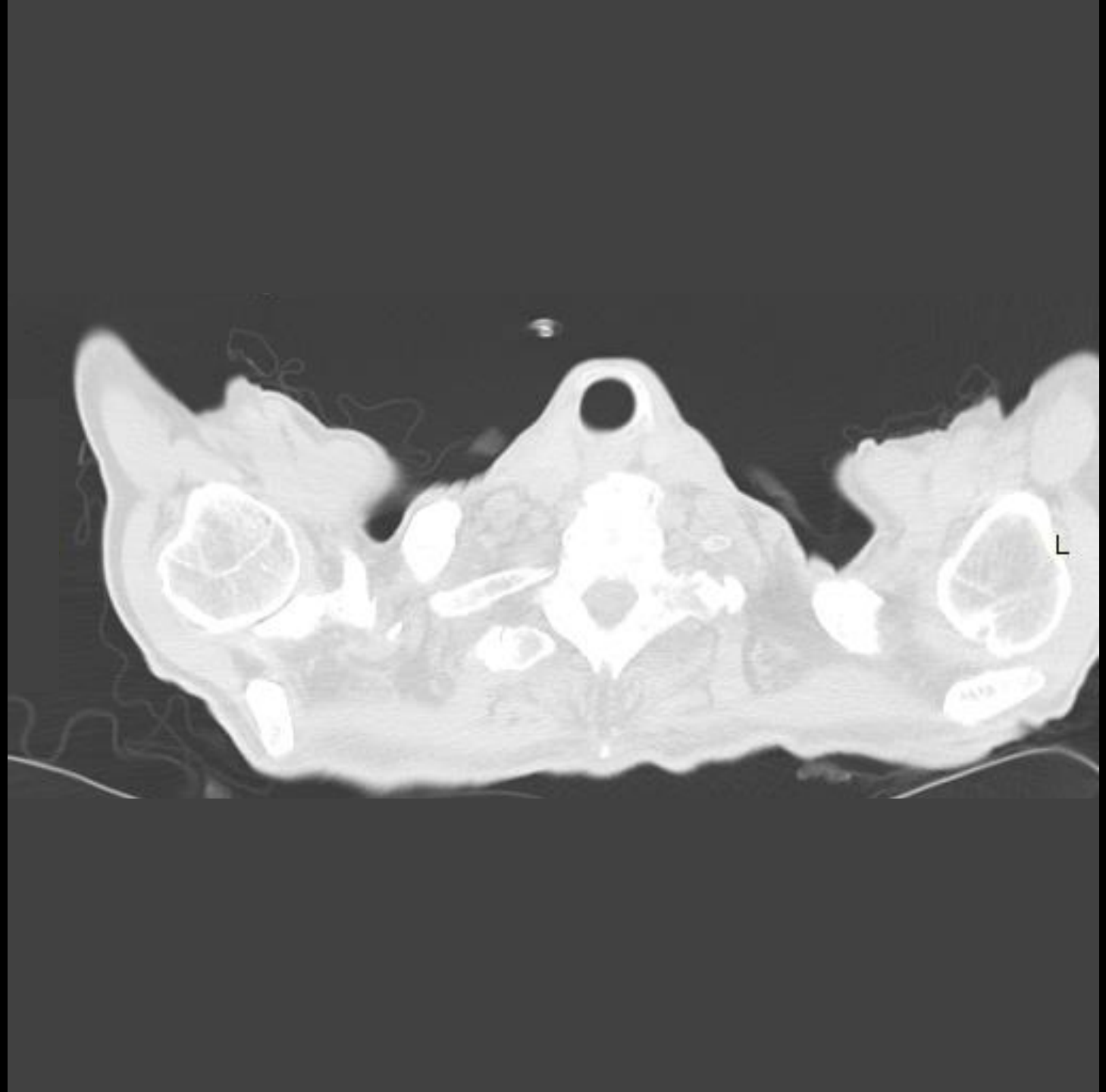
L

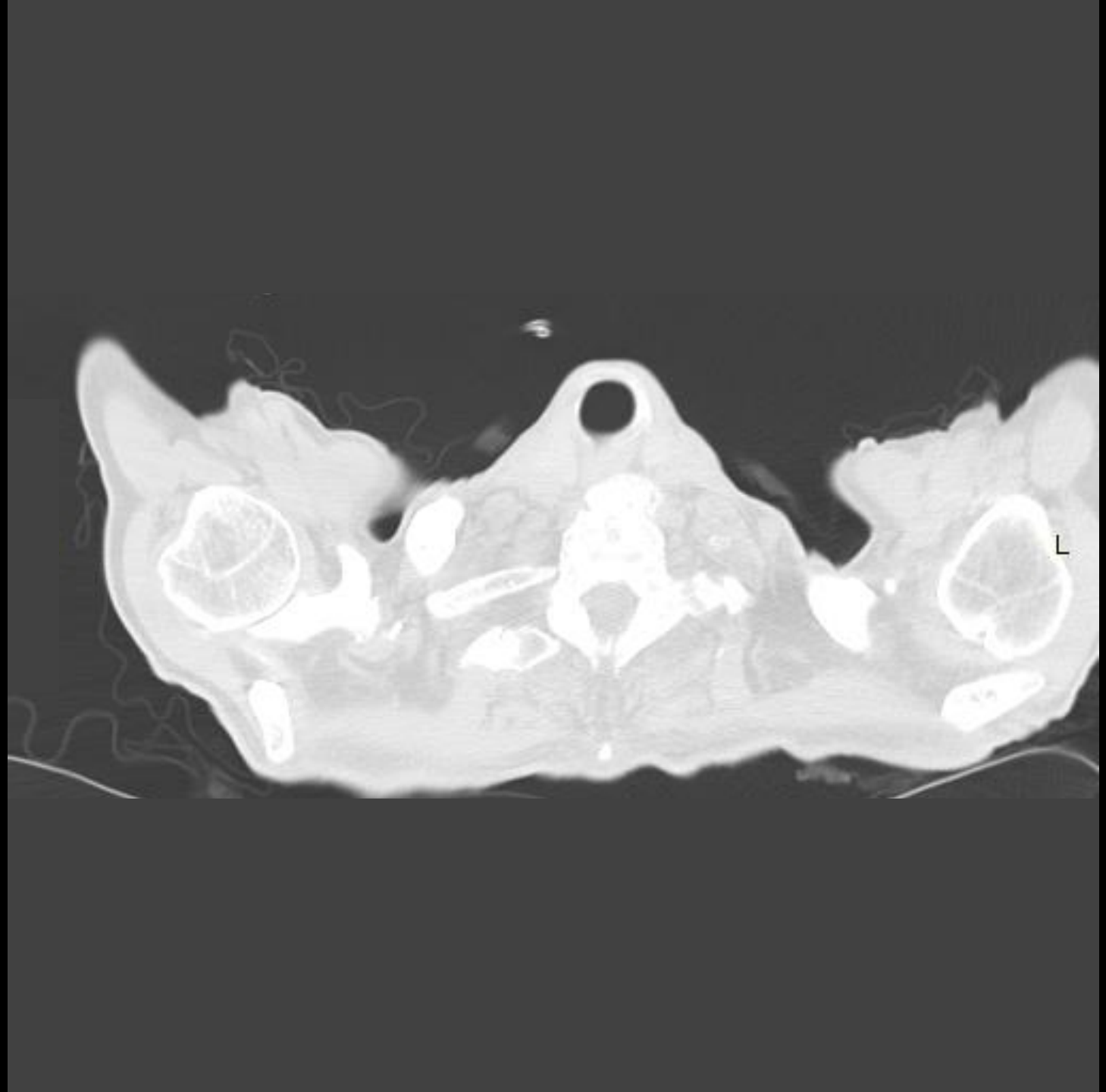
L

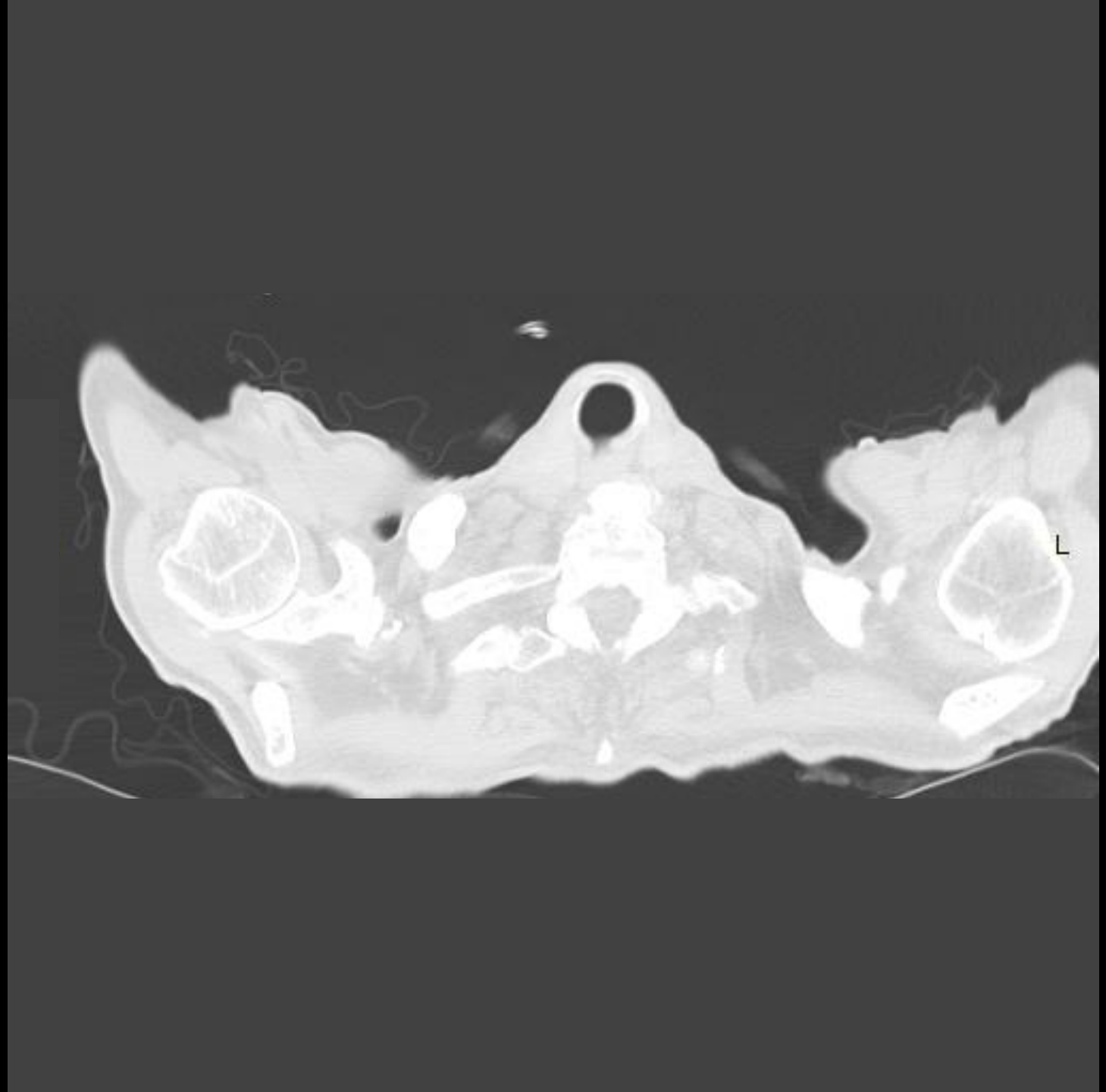
L

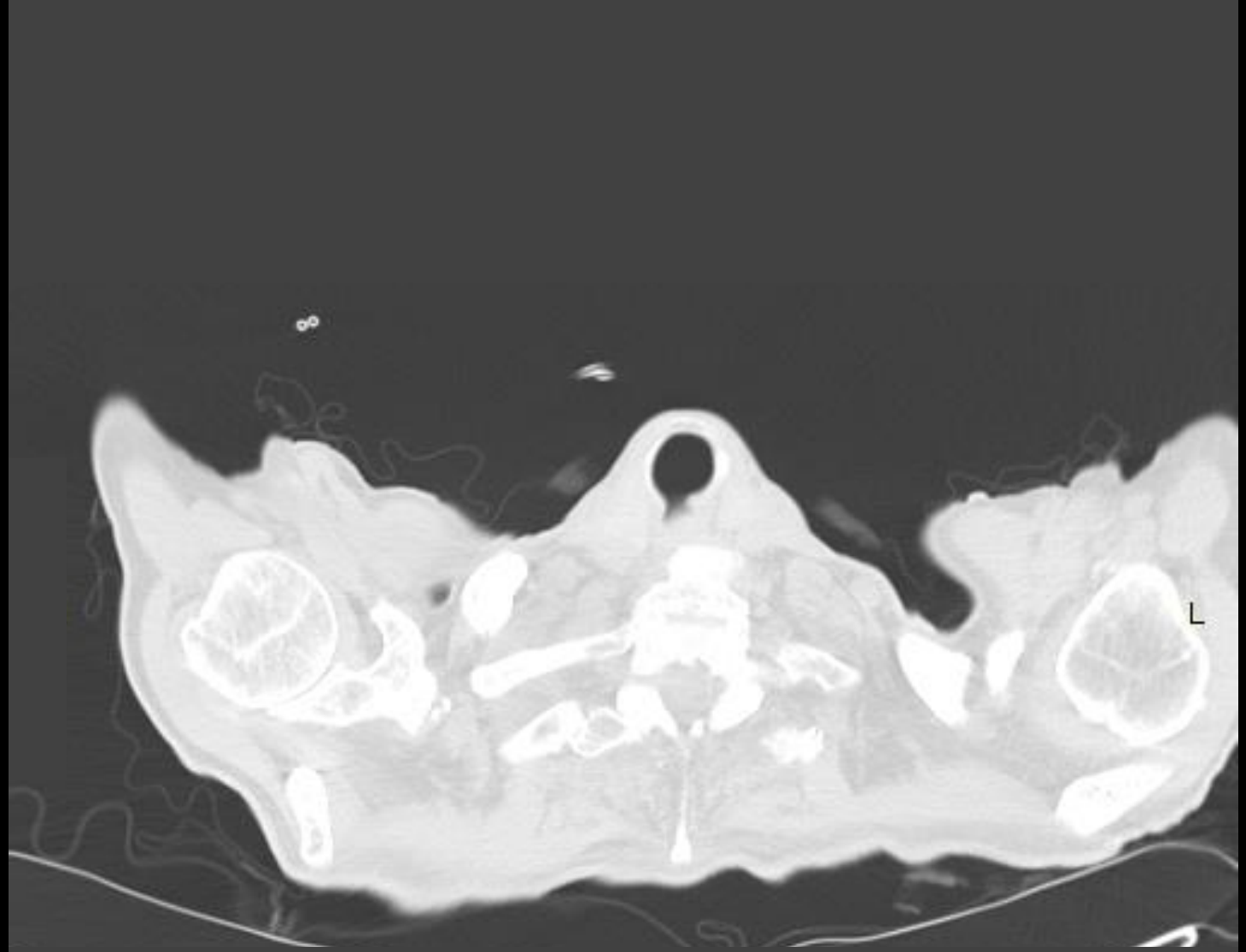
L

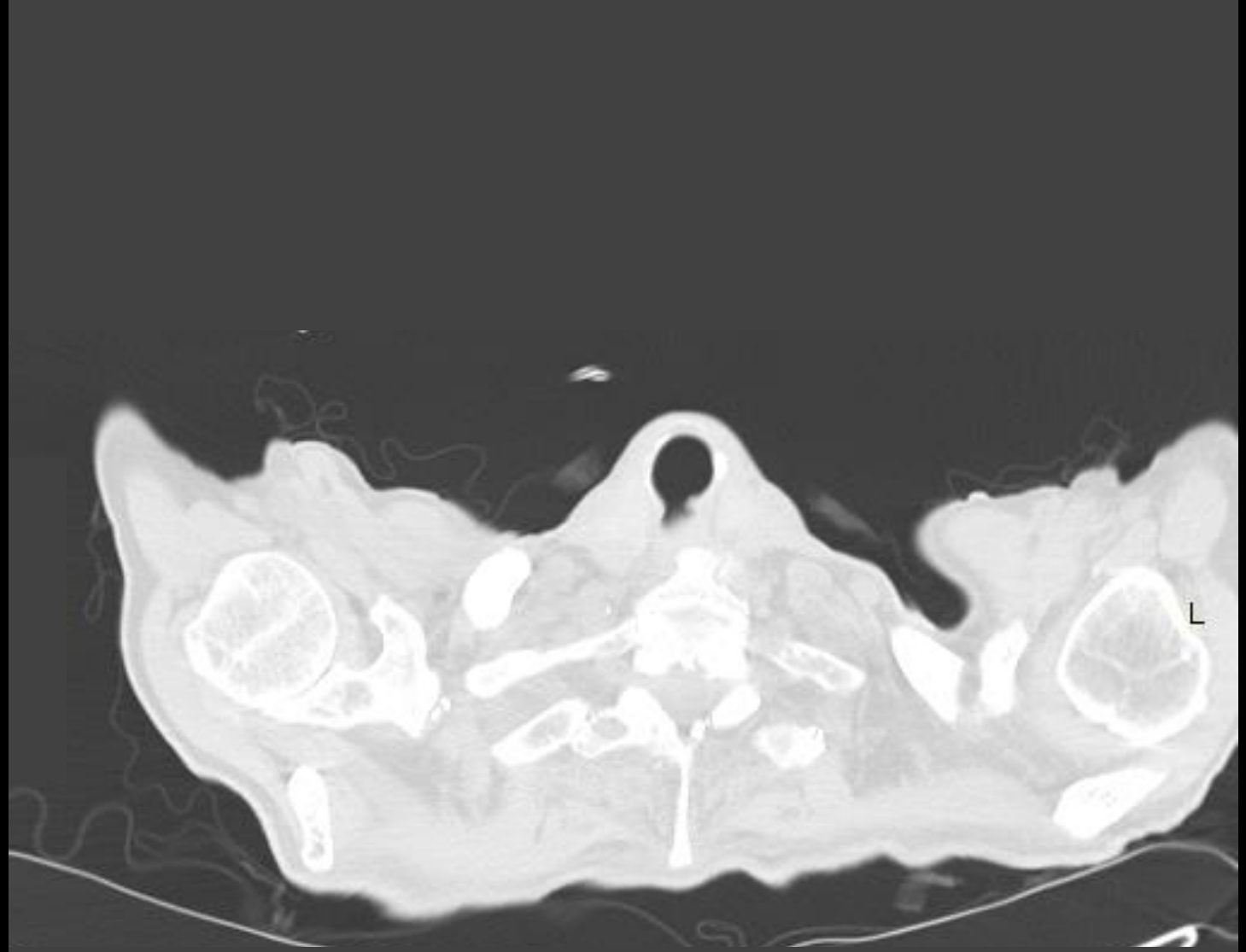
L

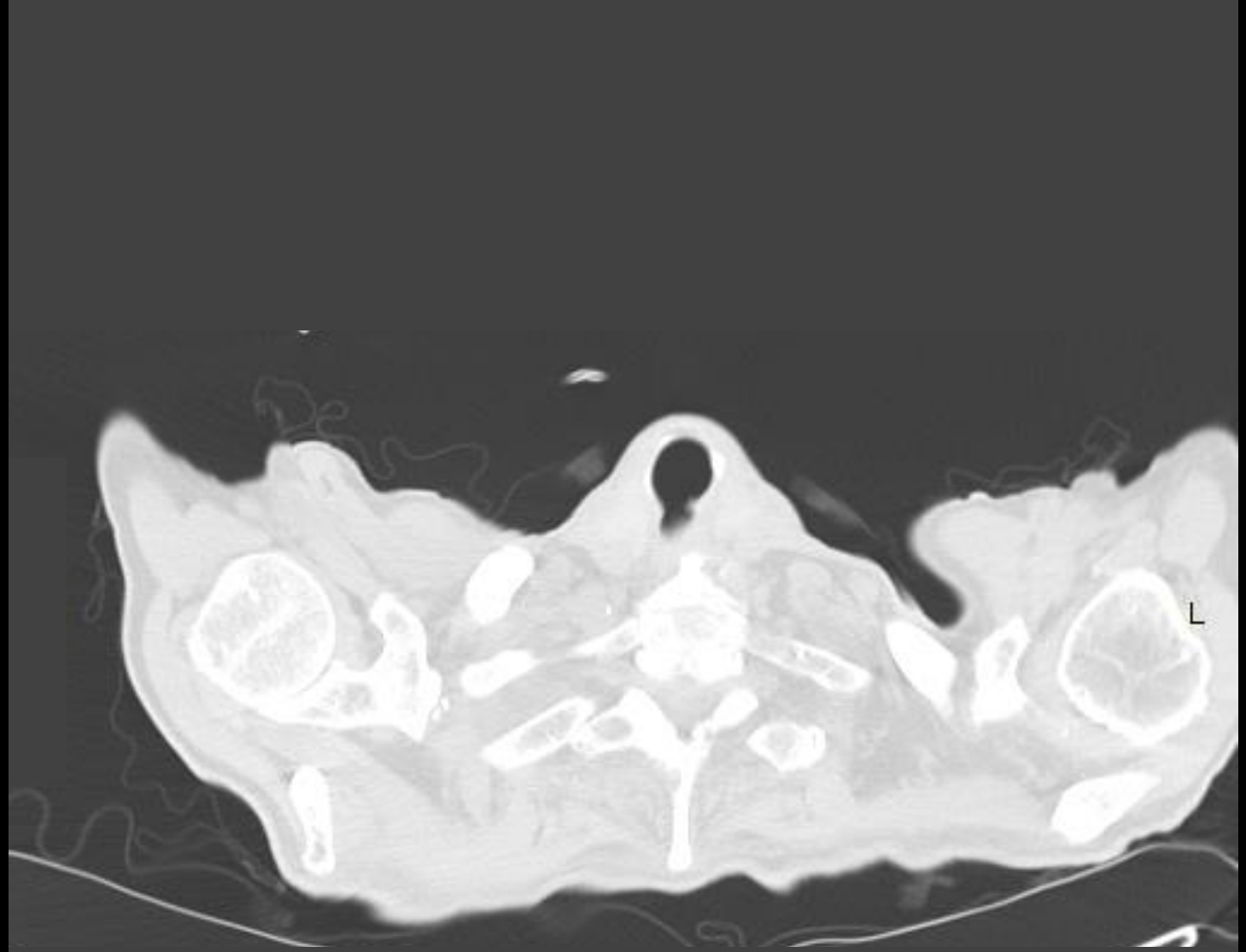
L

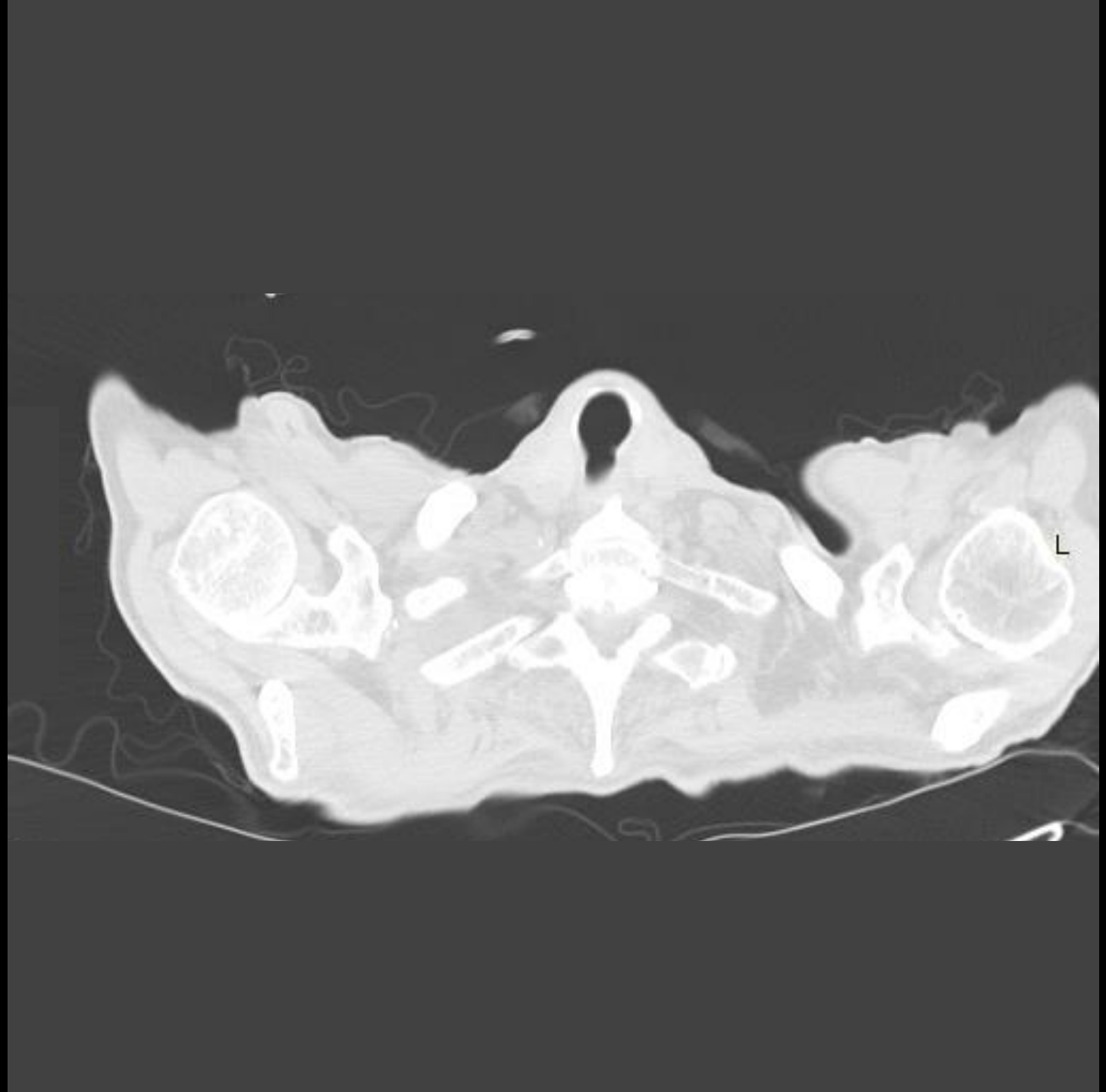
L

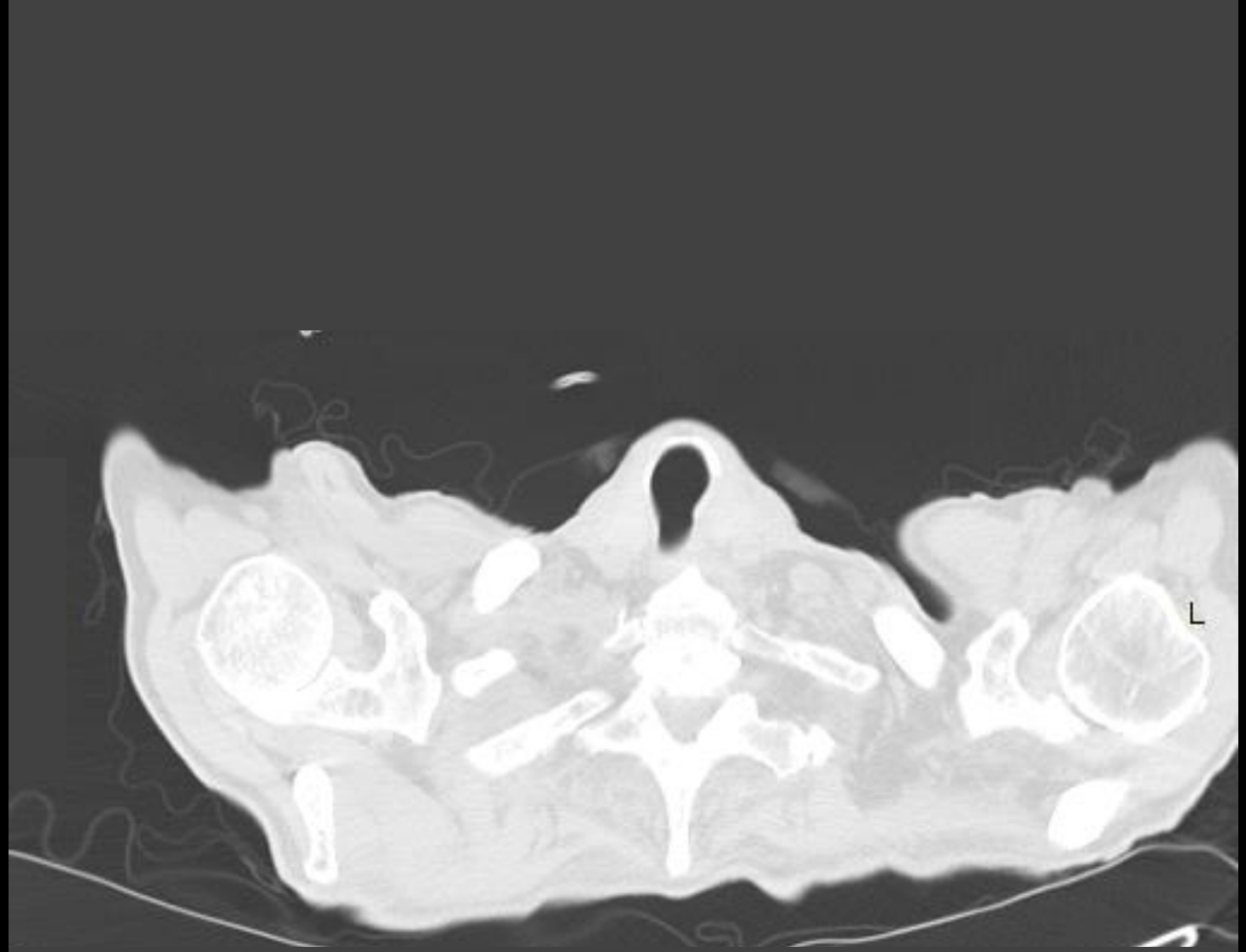
L

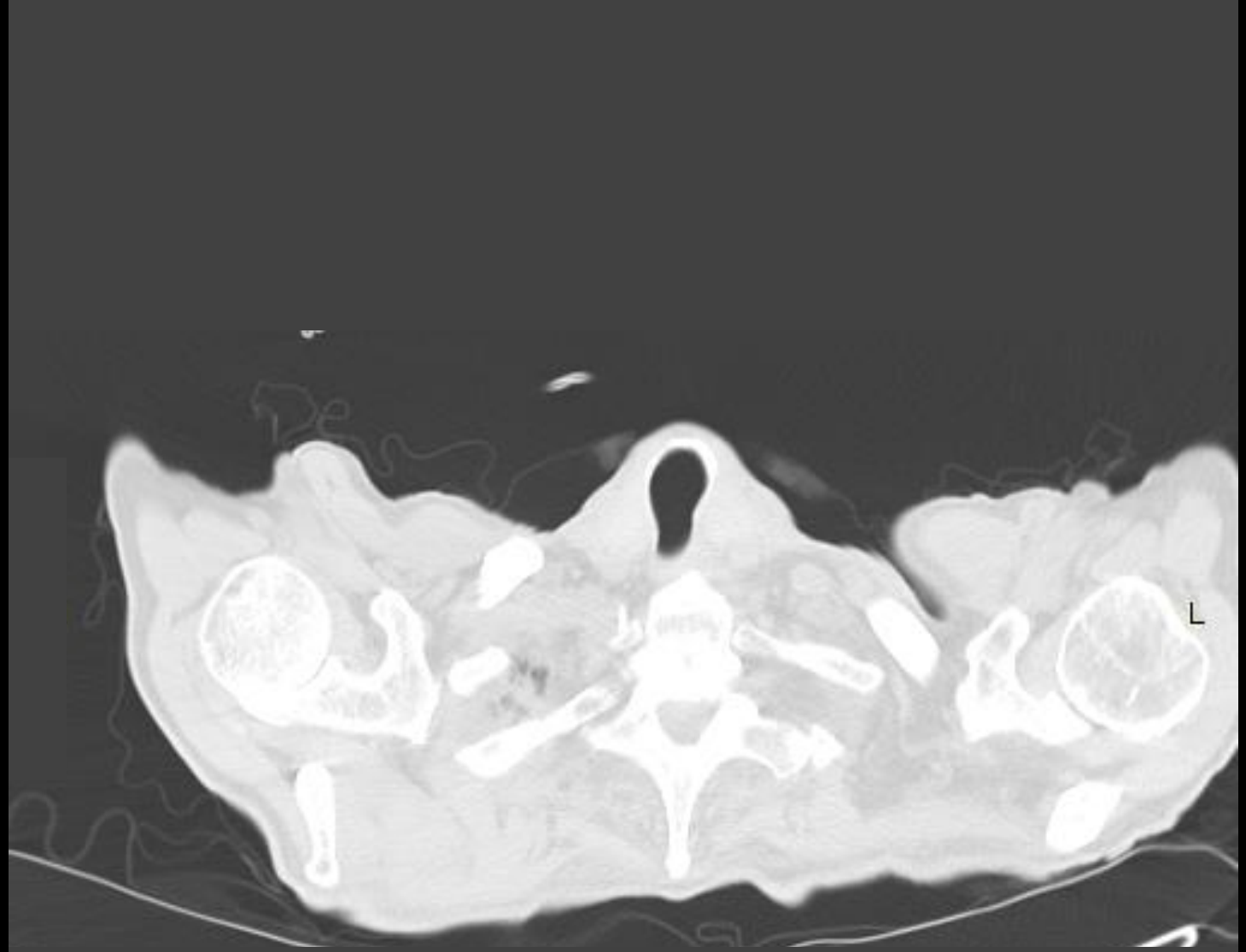
L

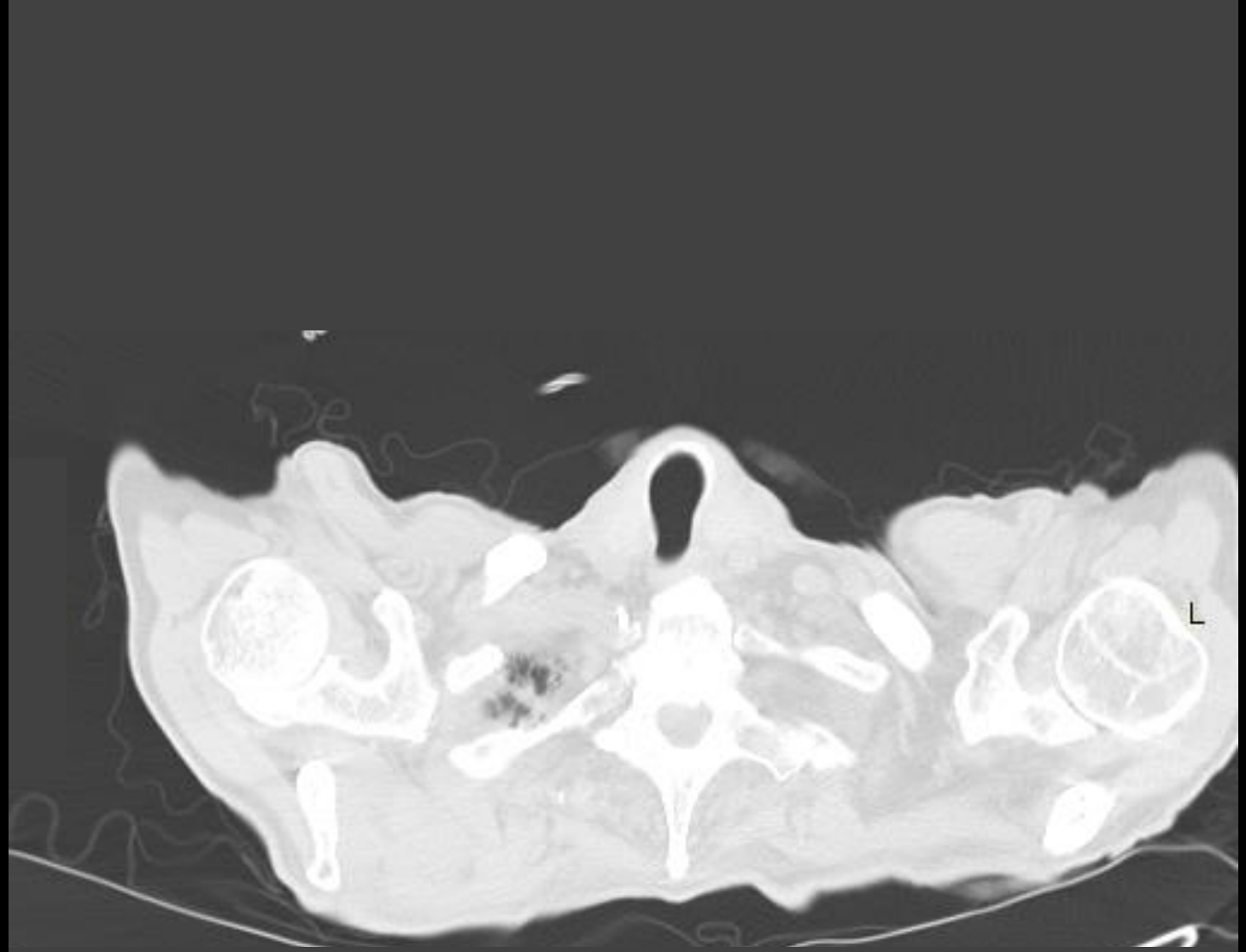
L

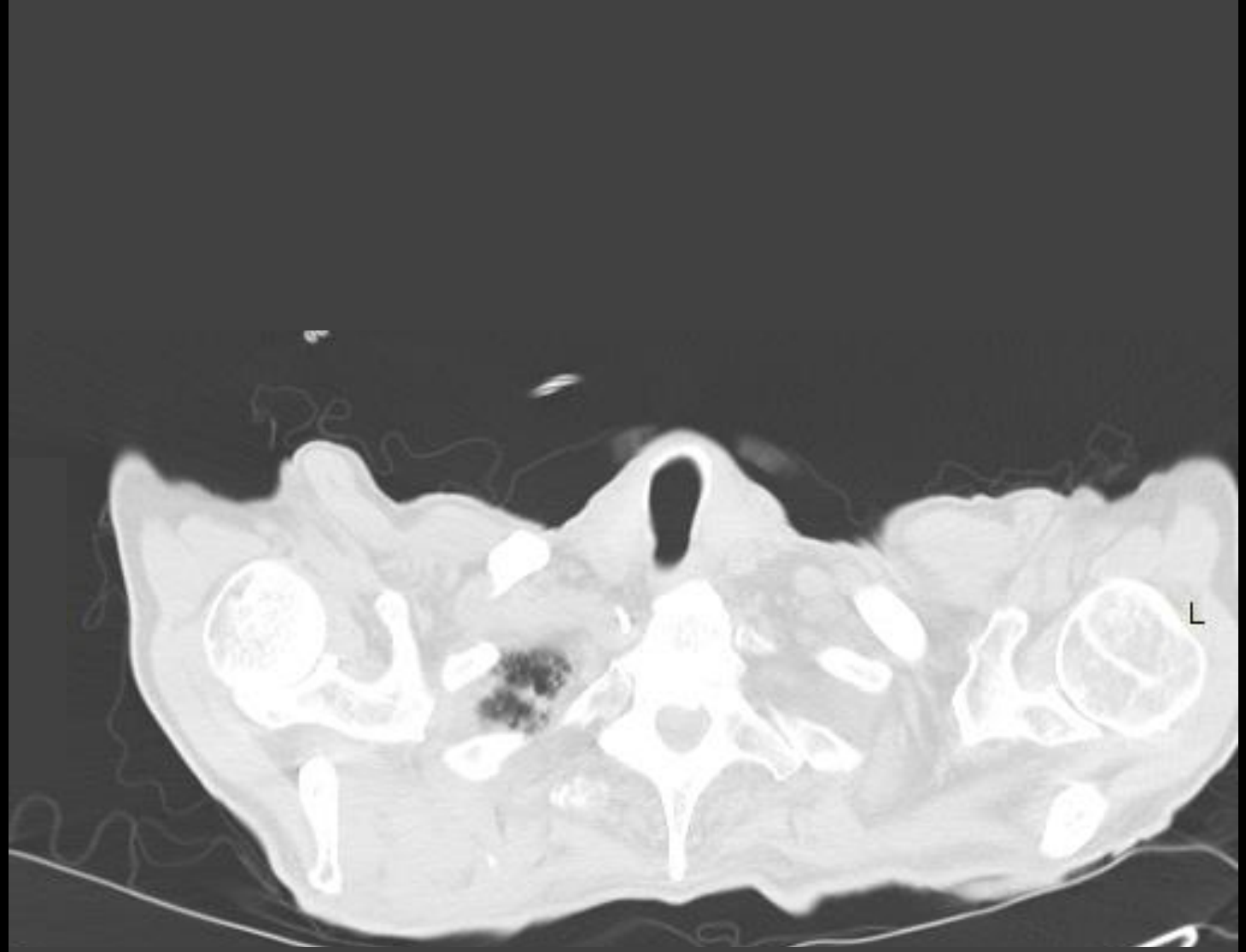
L

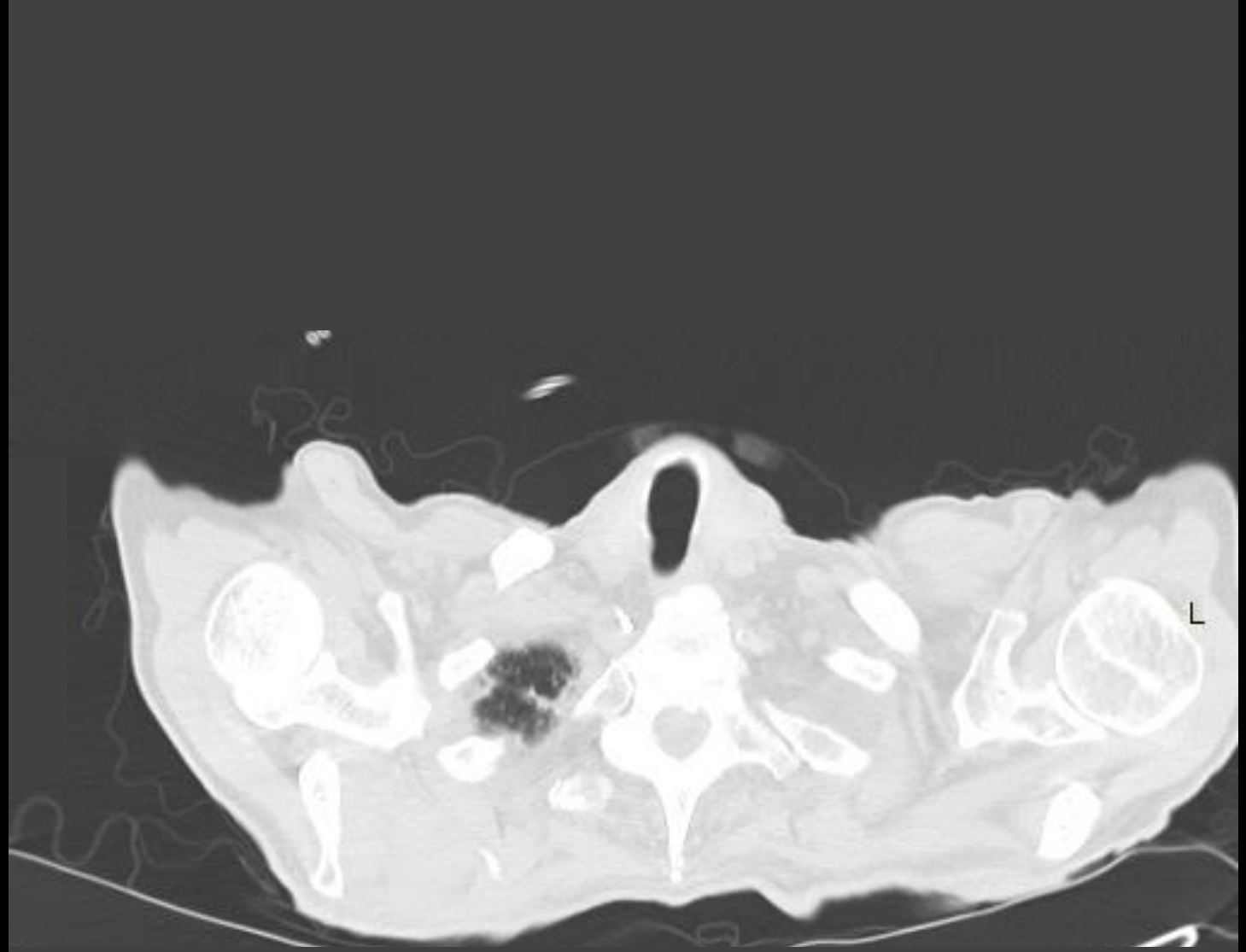
L

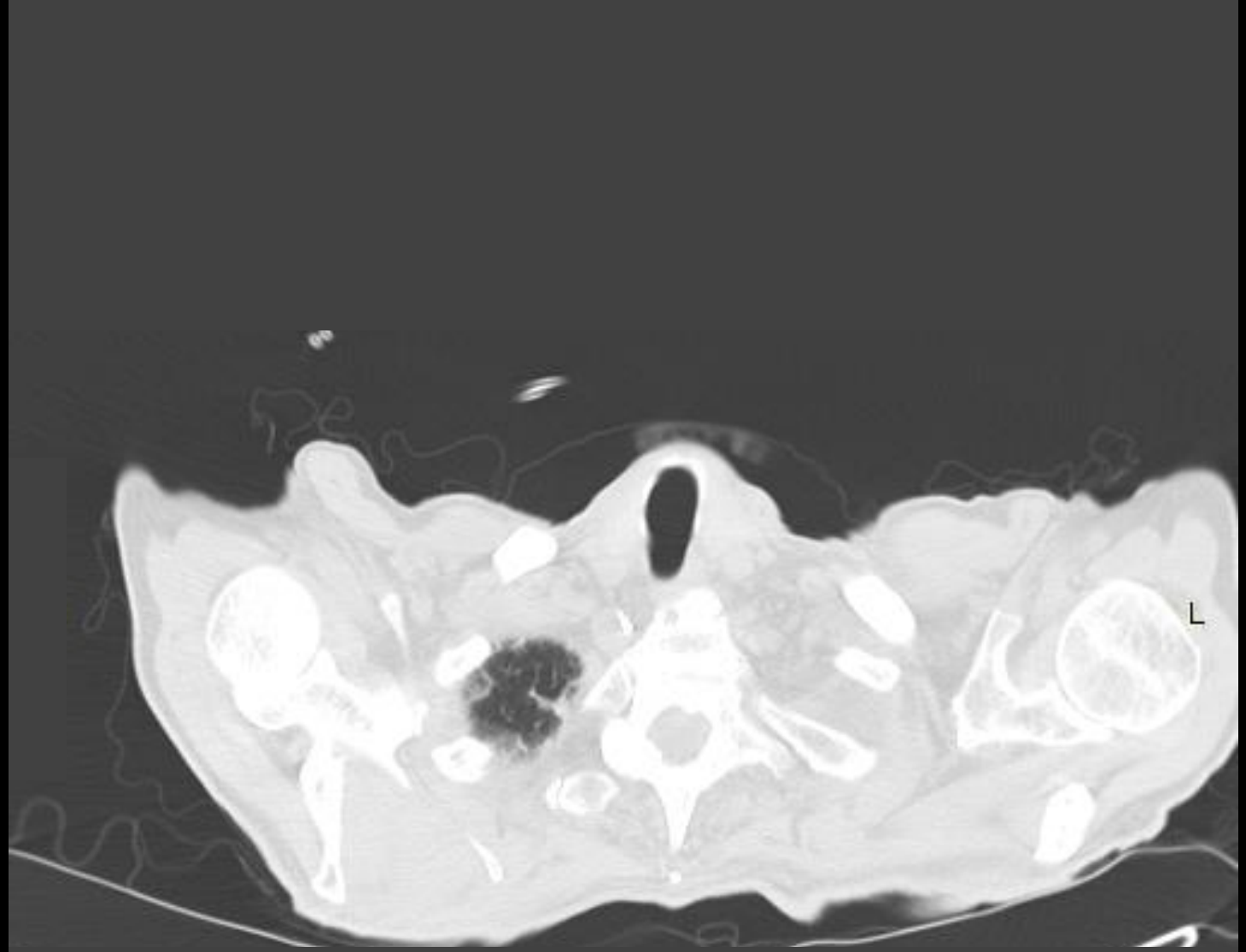
L

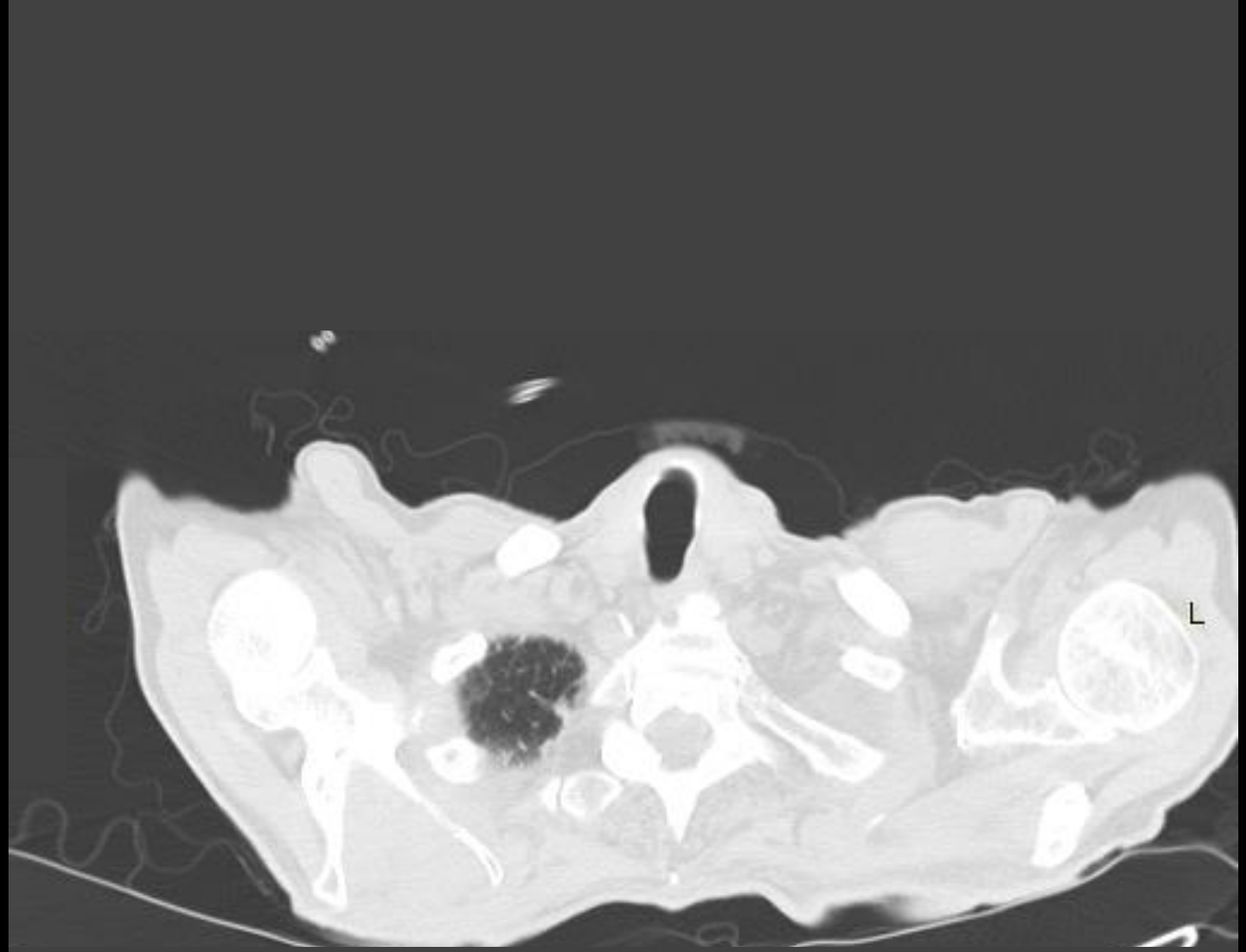
L

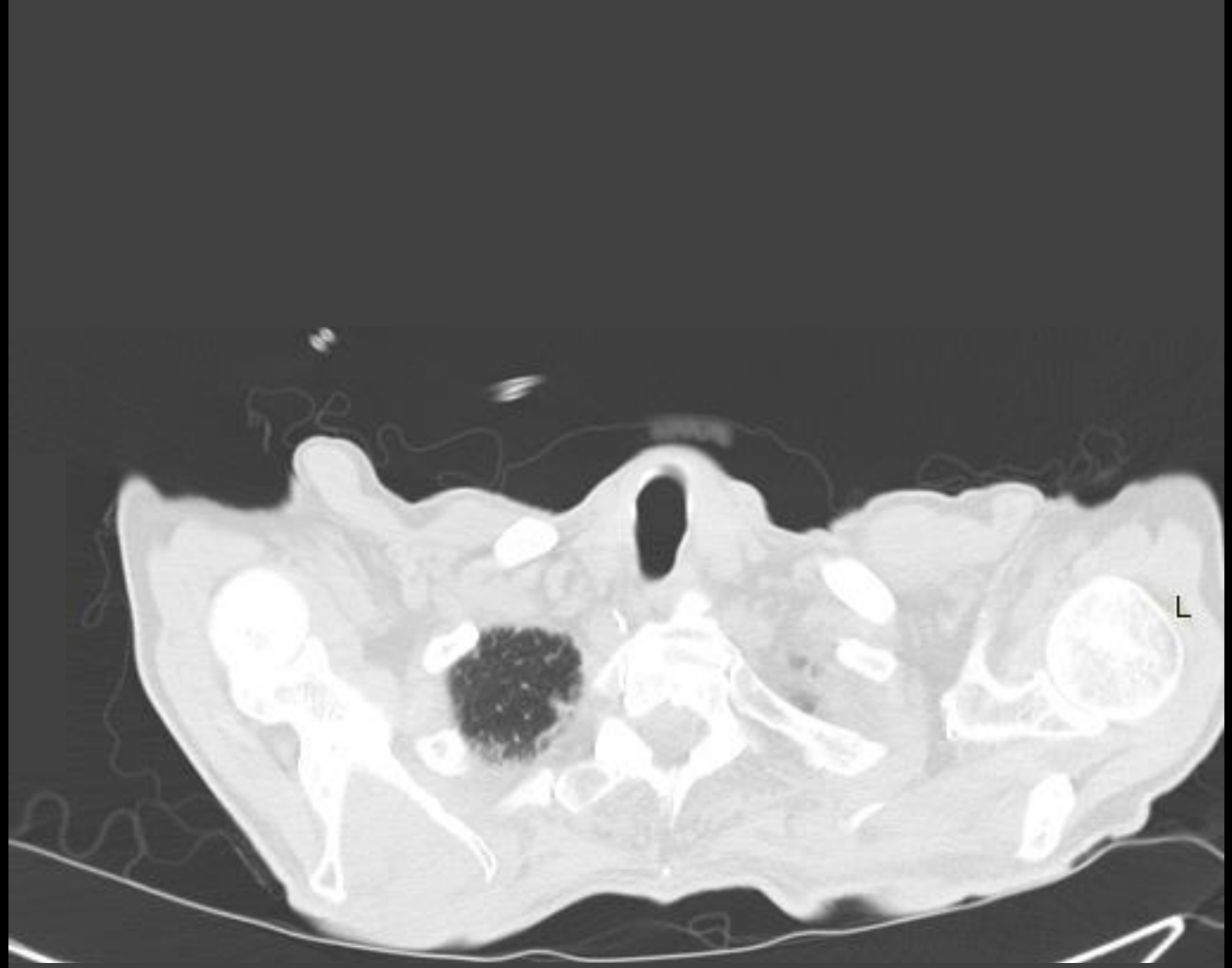
L

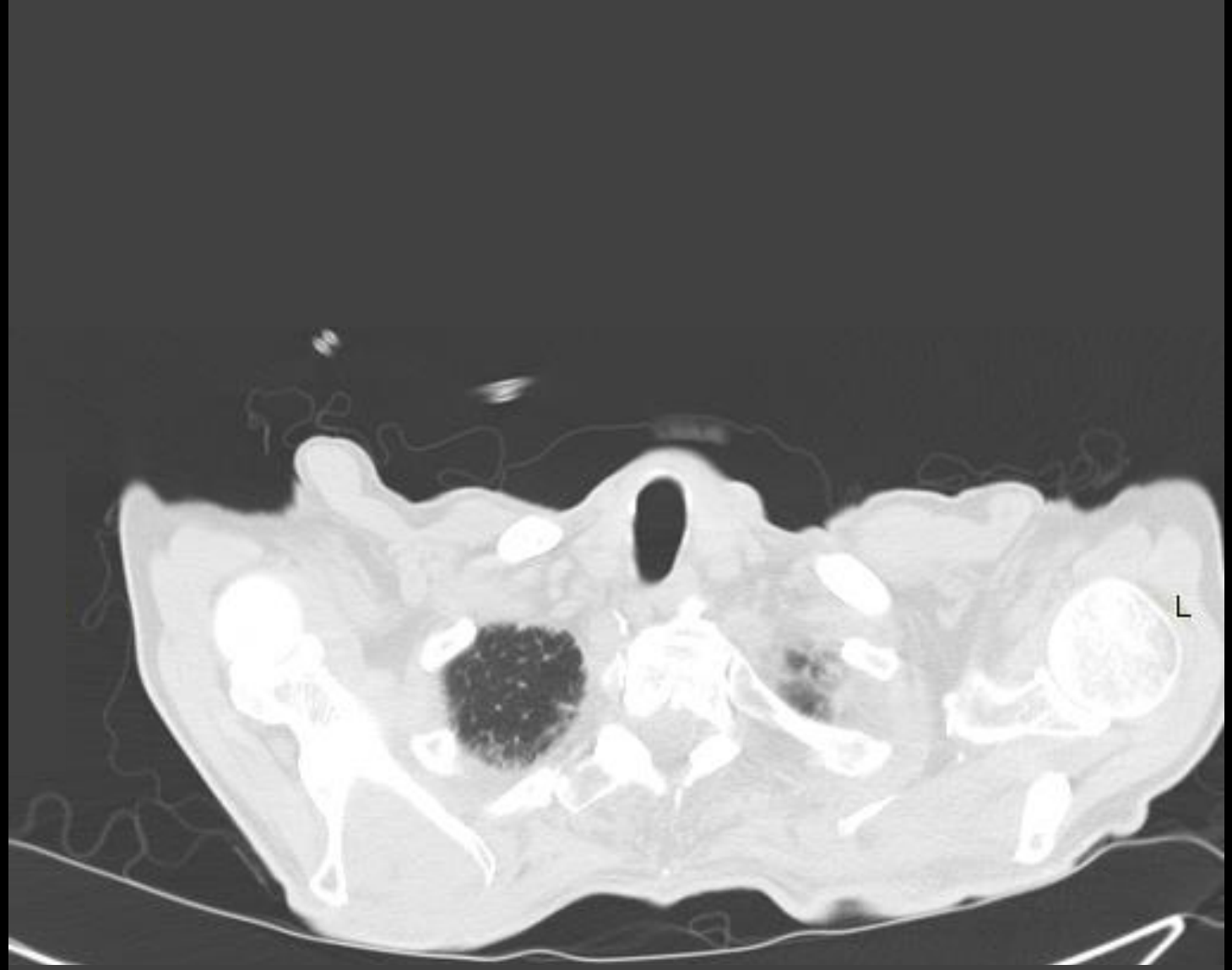
L

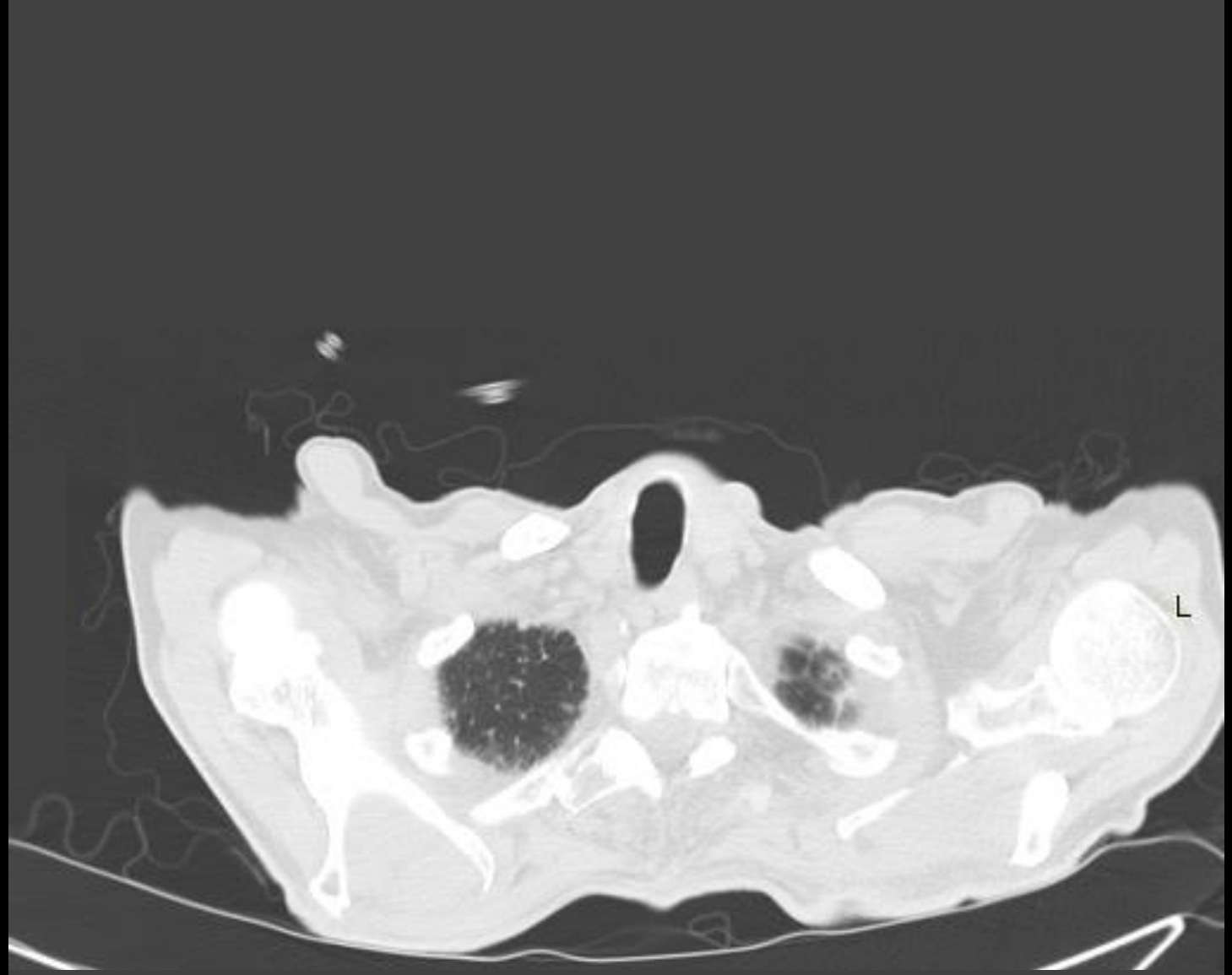
L

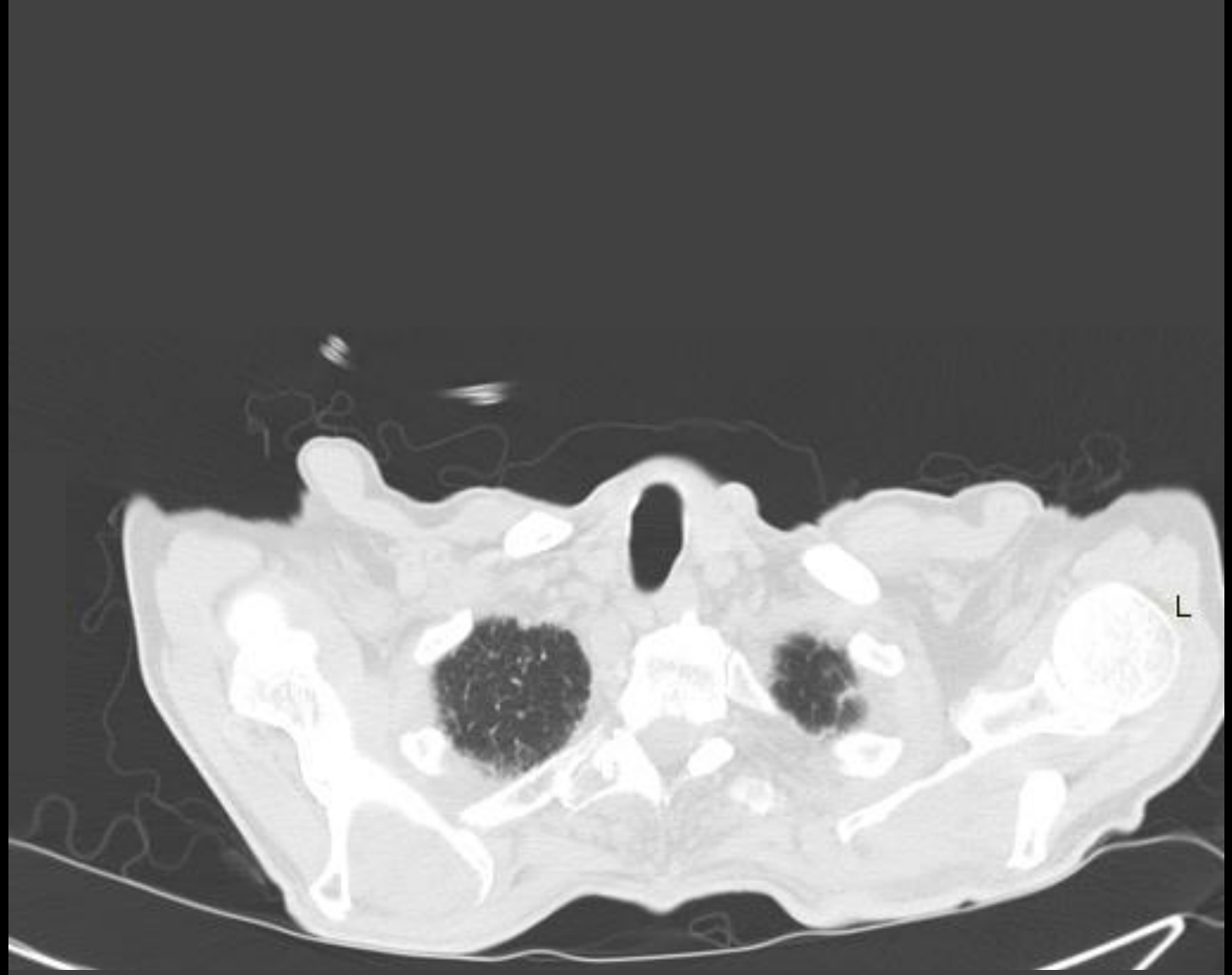
L

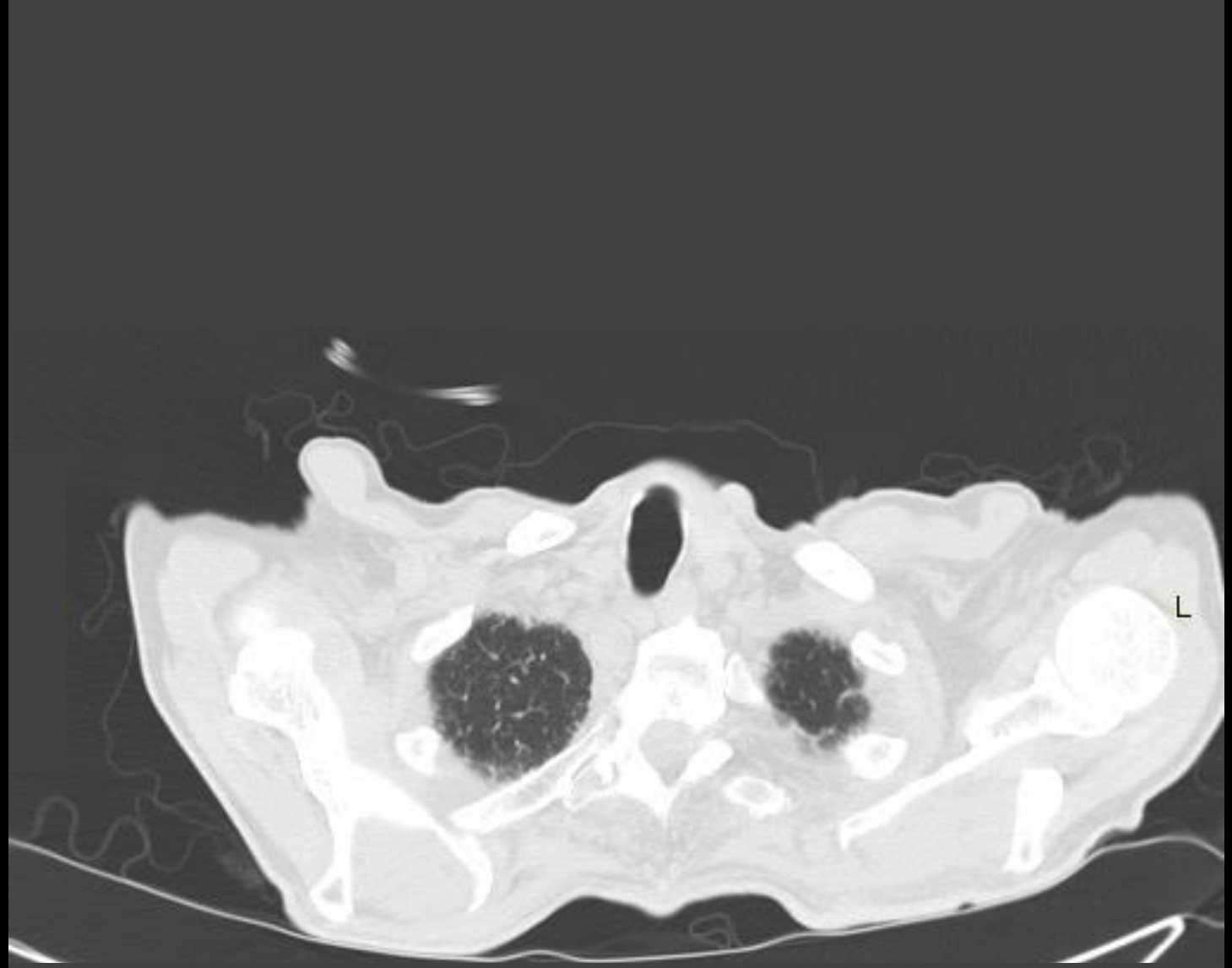
L

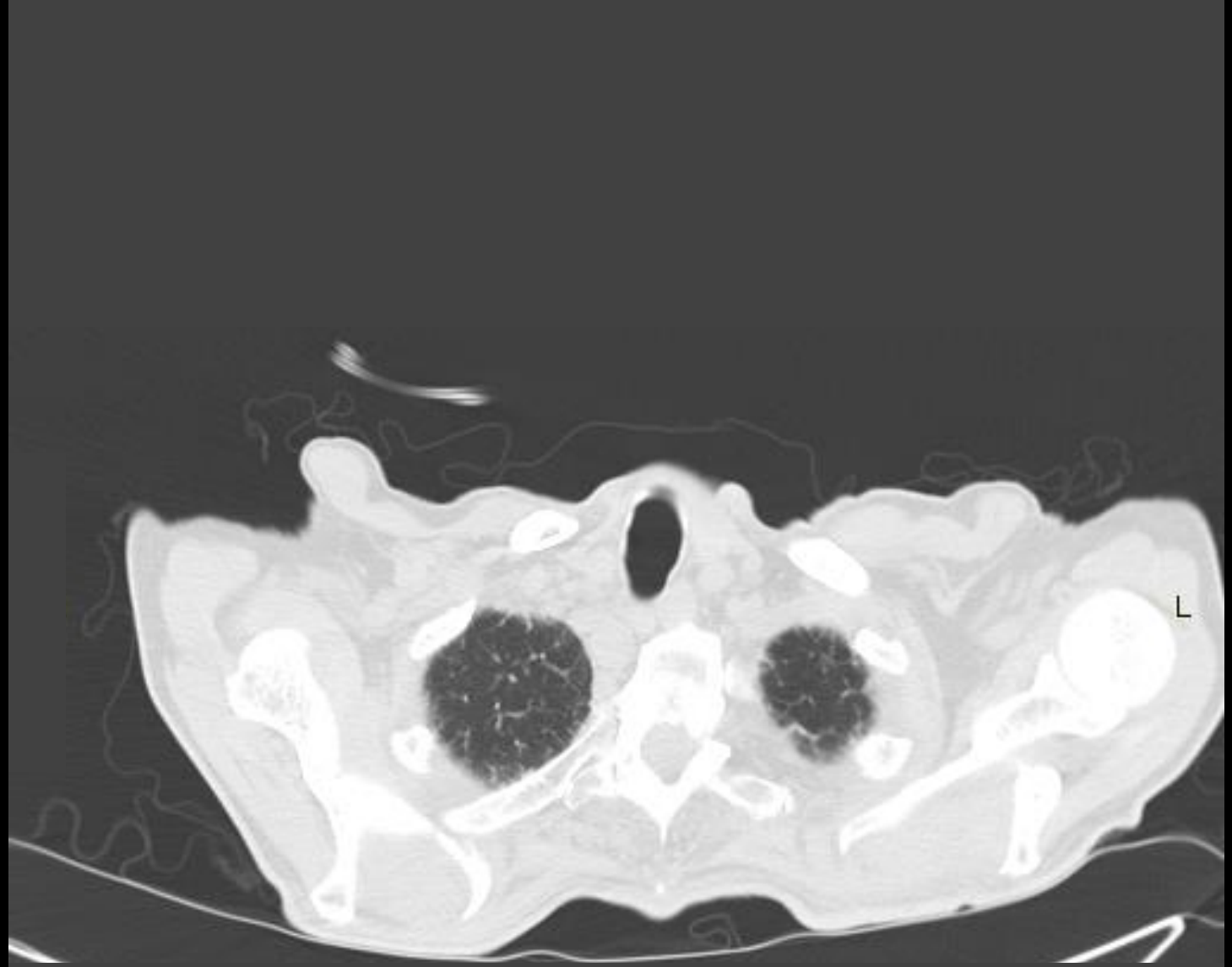
L

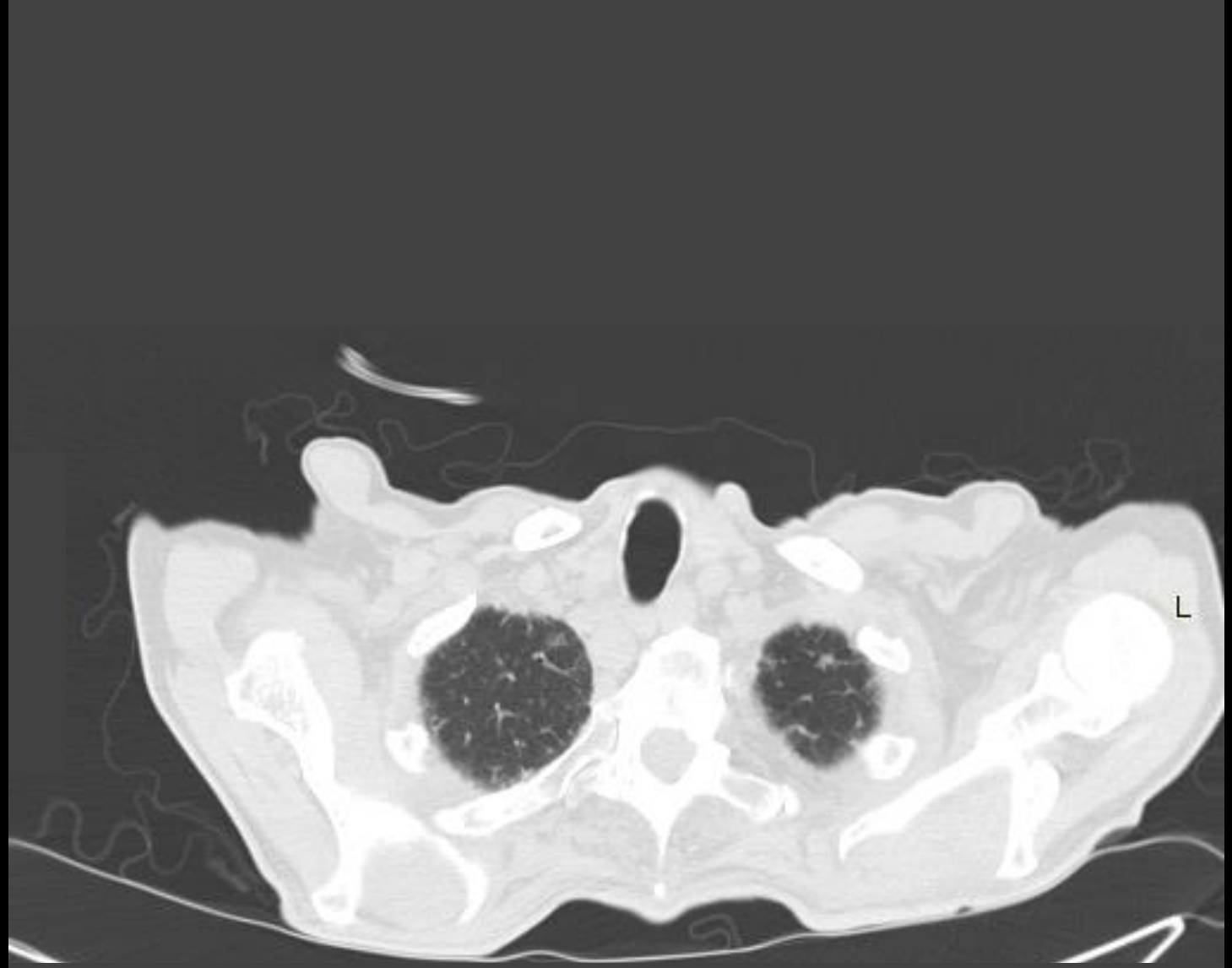
L

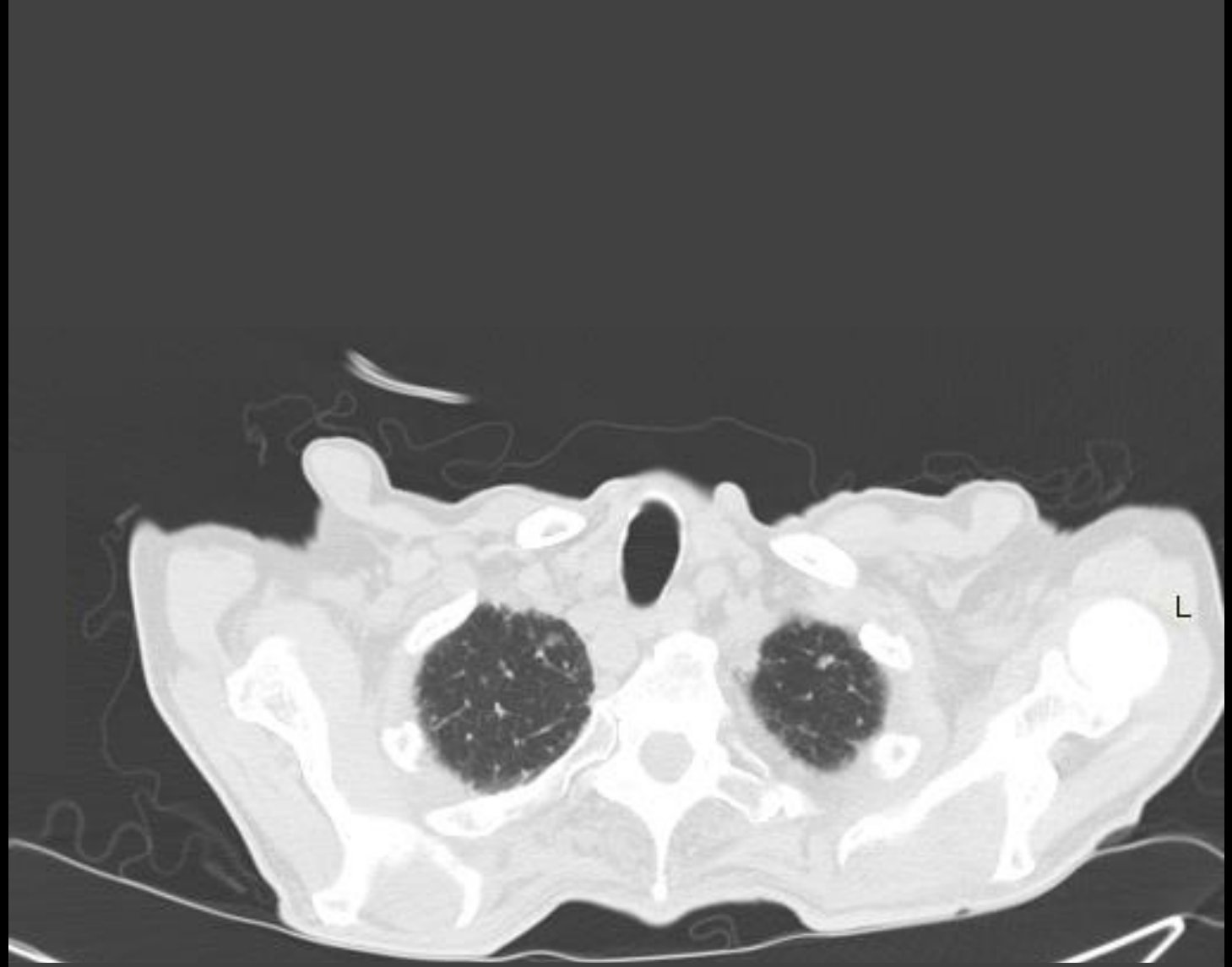
L

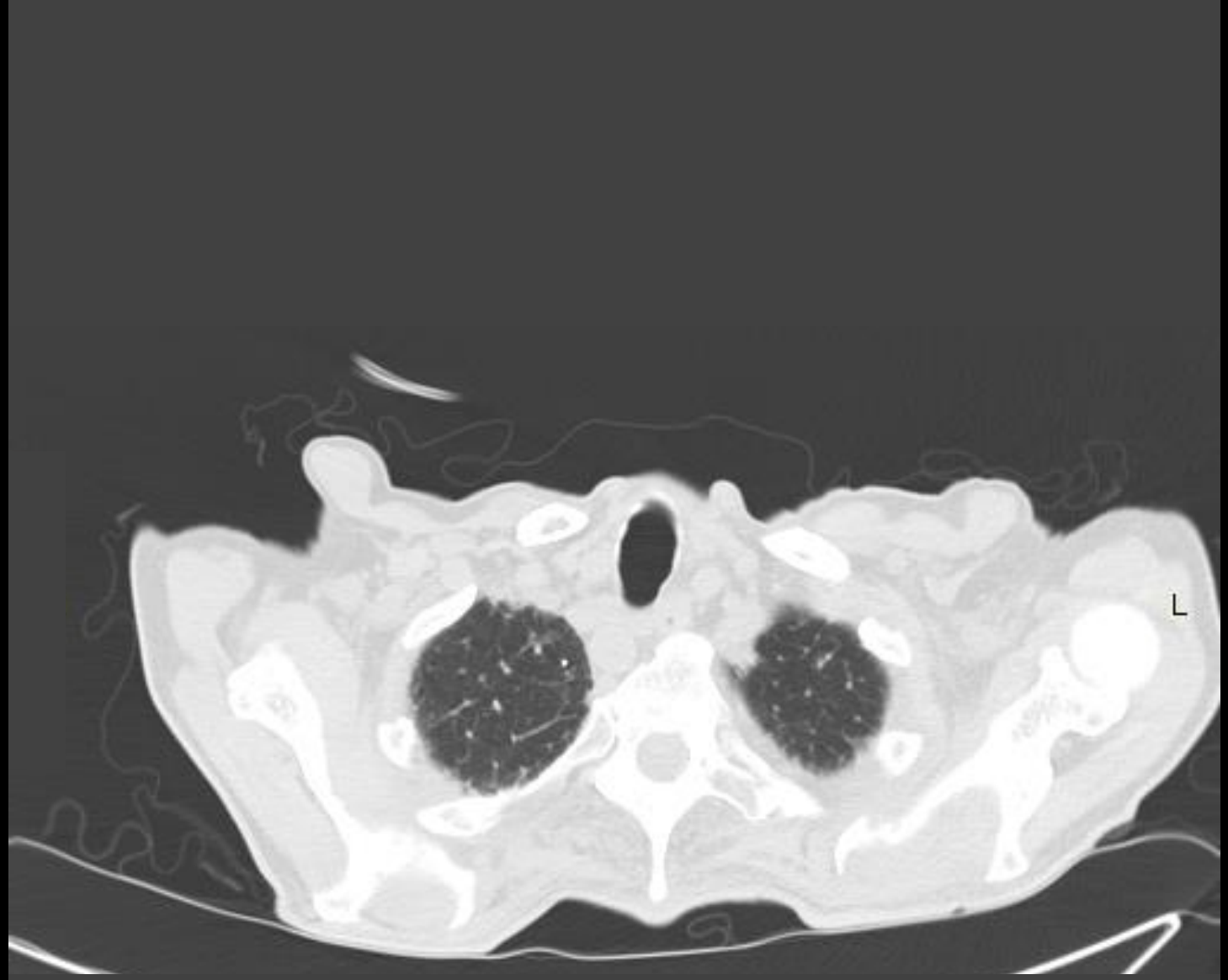
L

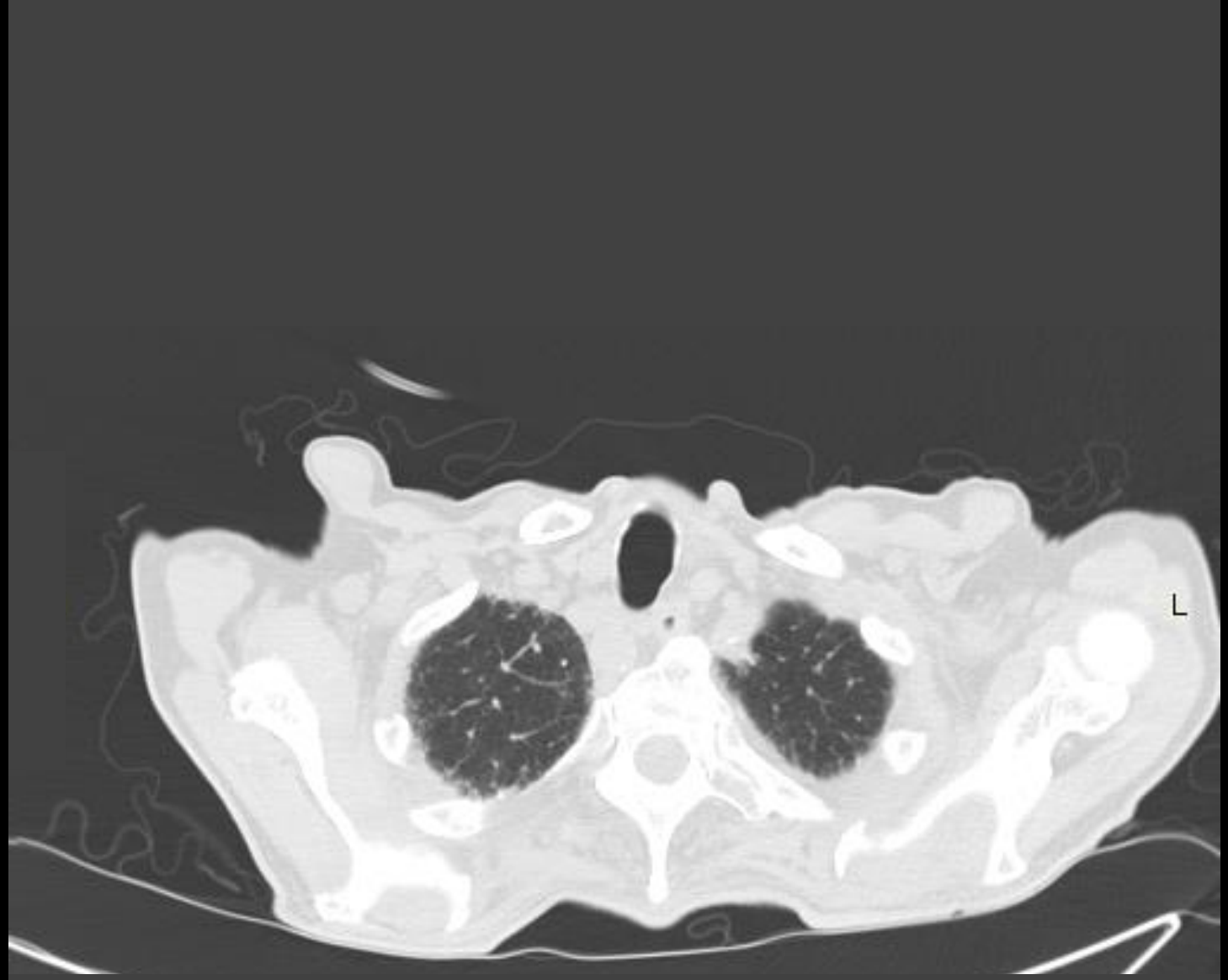
L

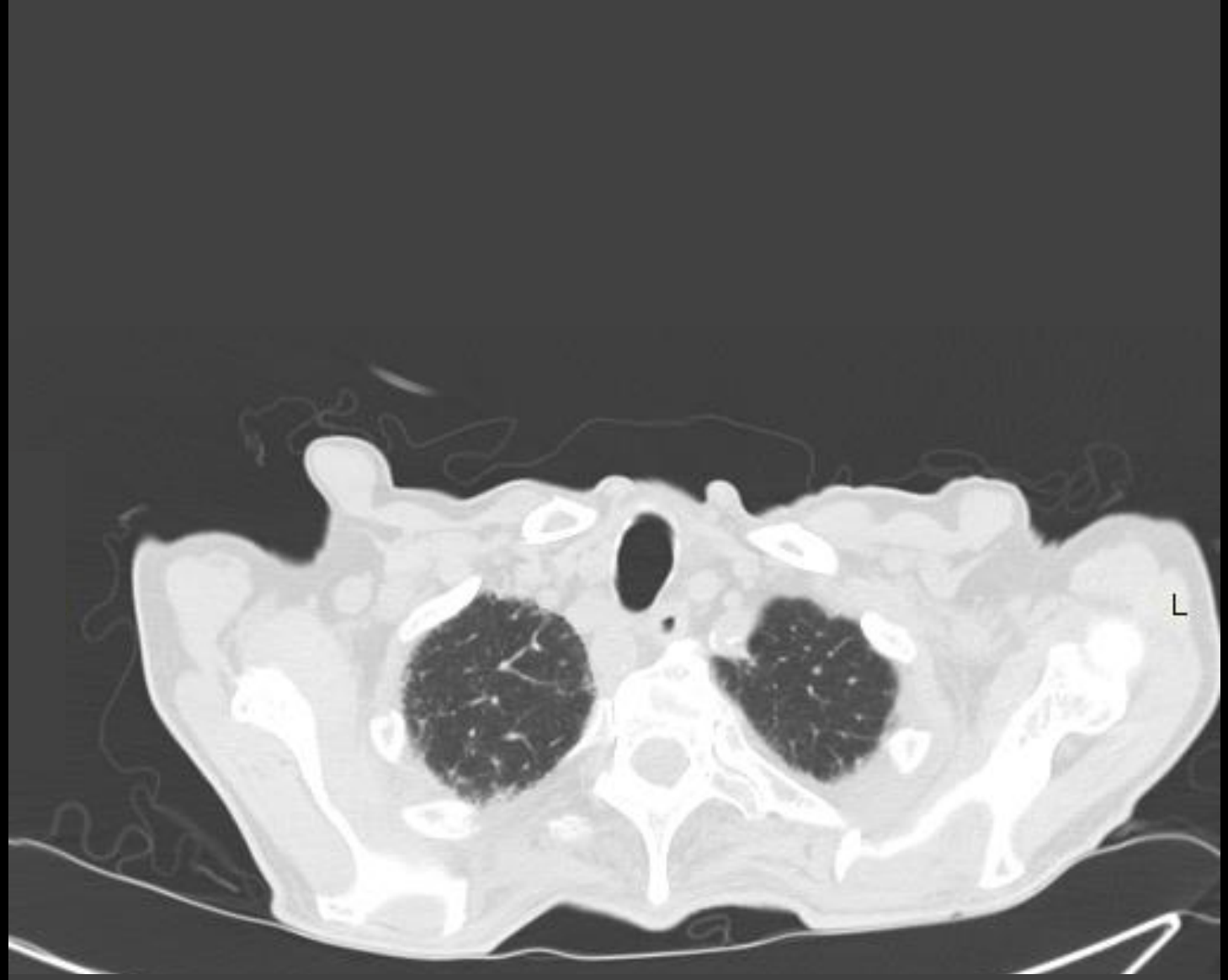
L

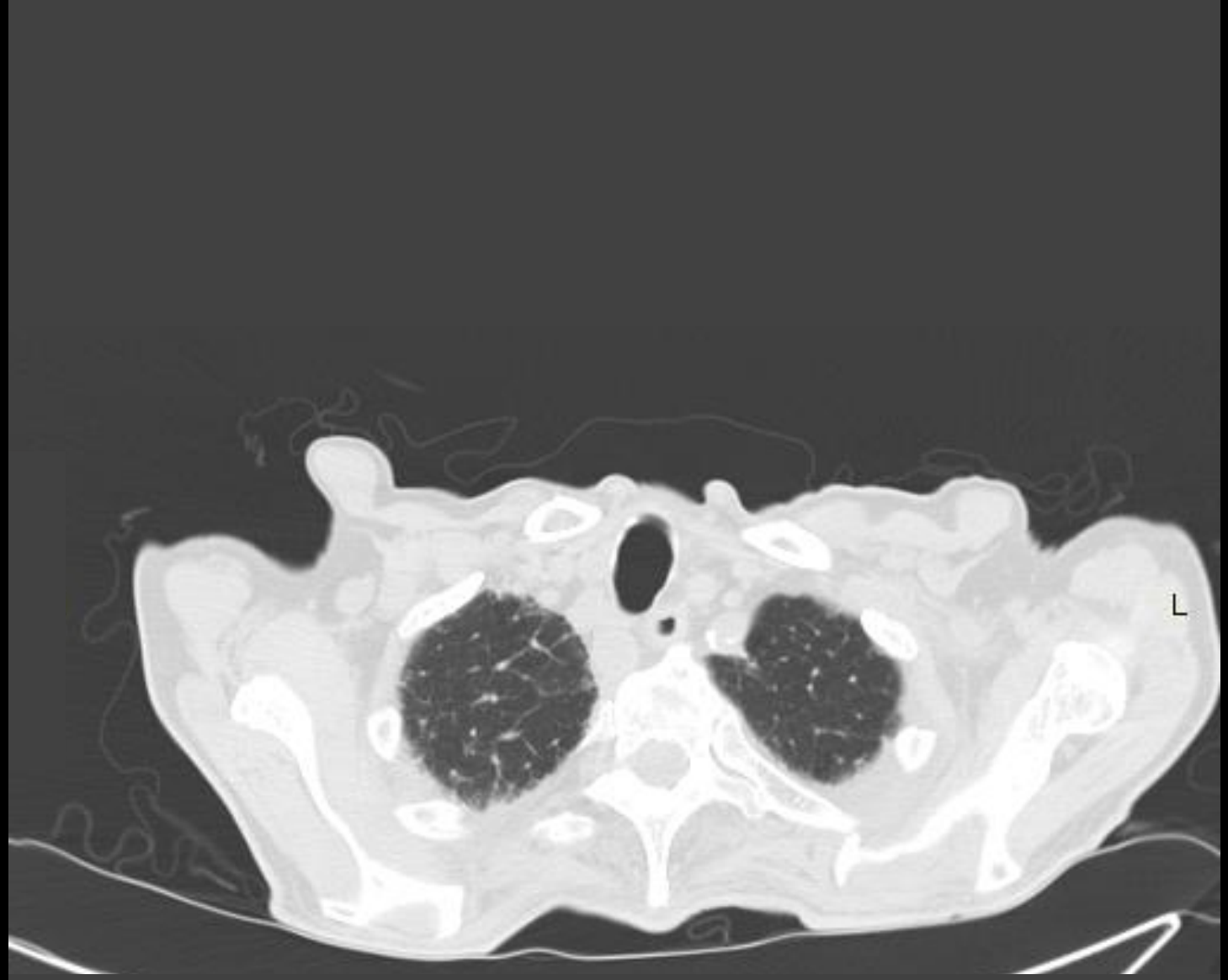
L

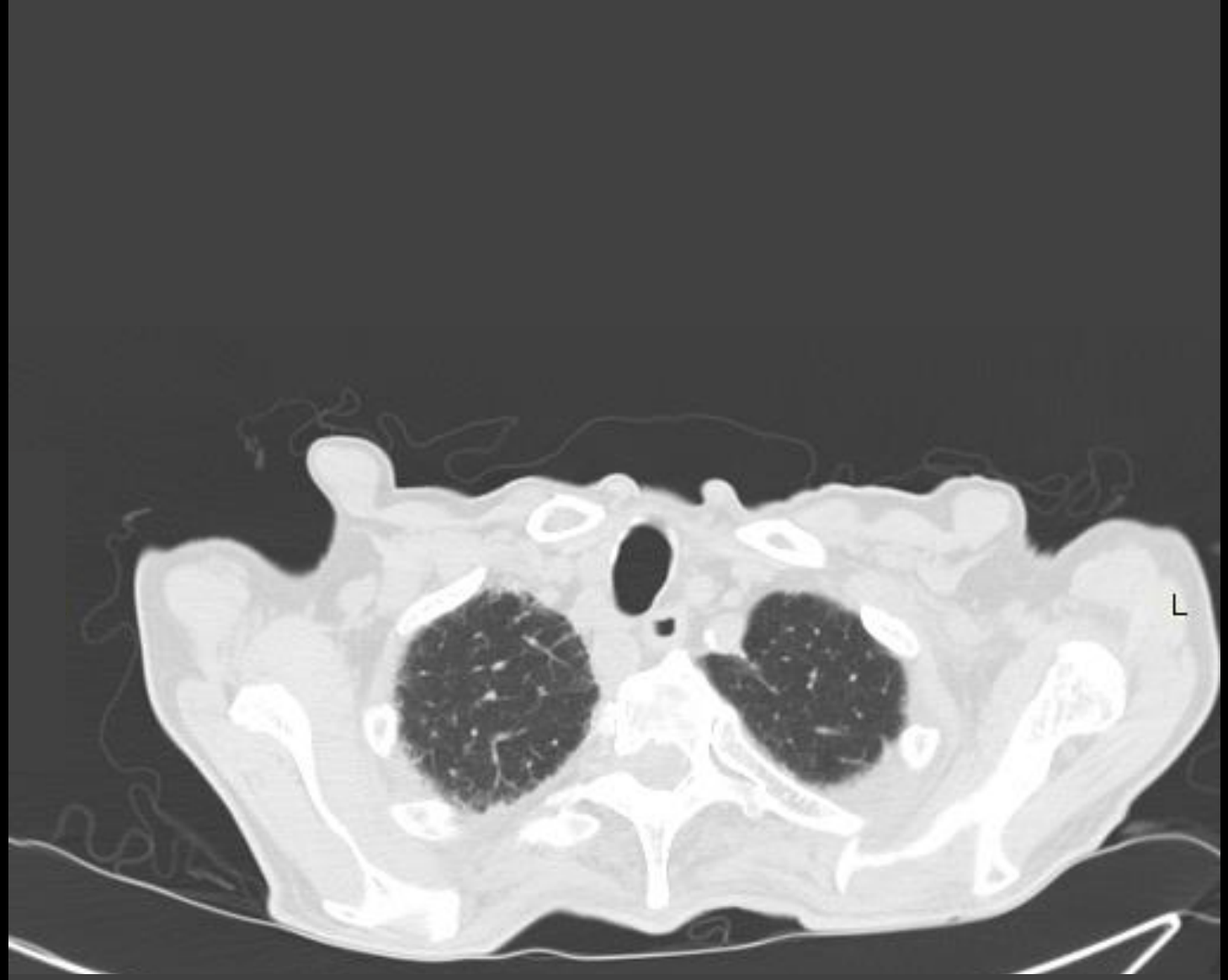
L

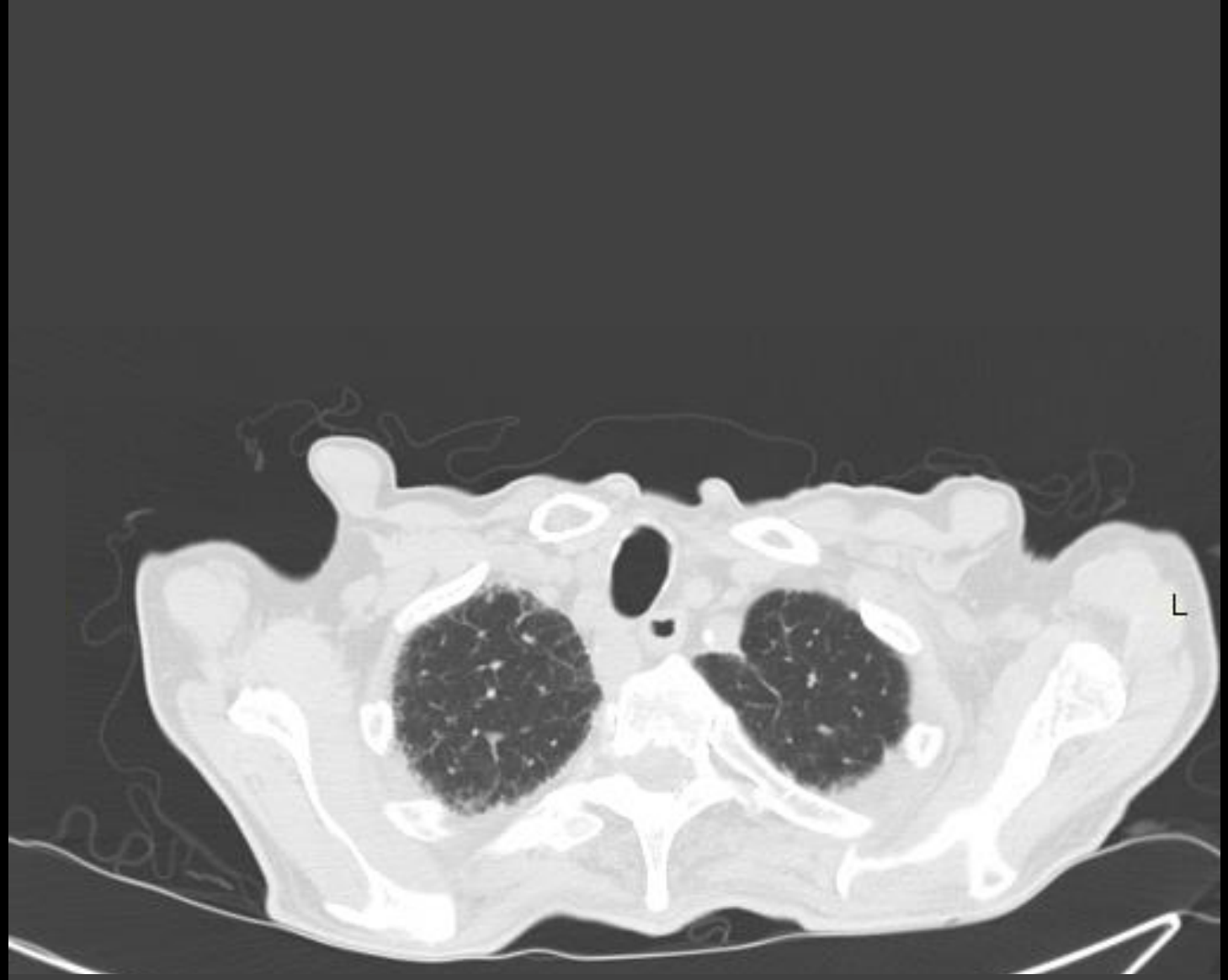
L

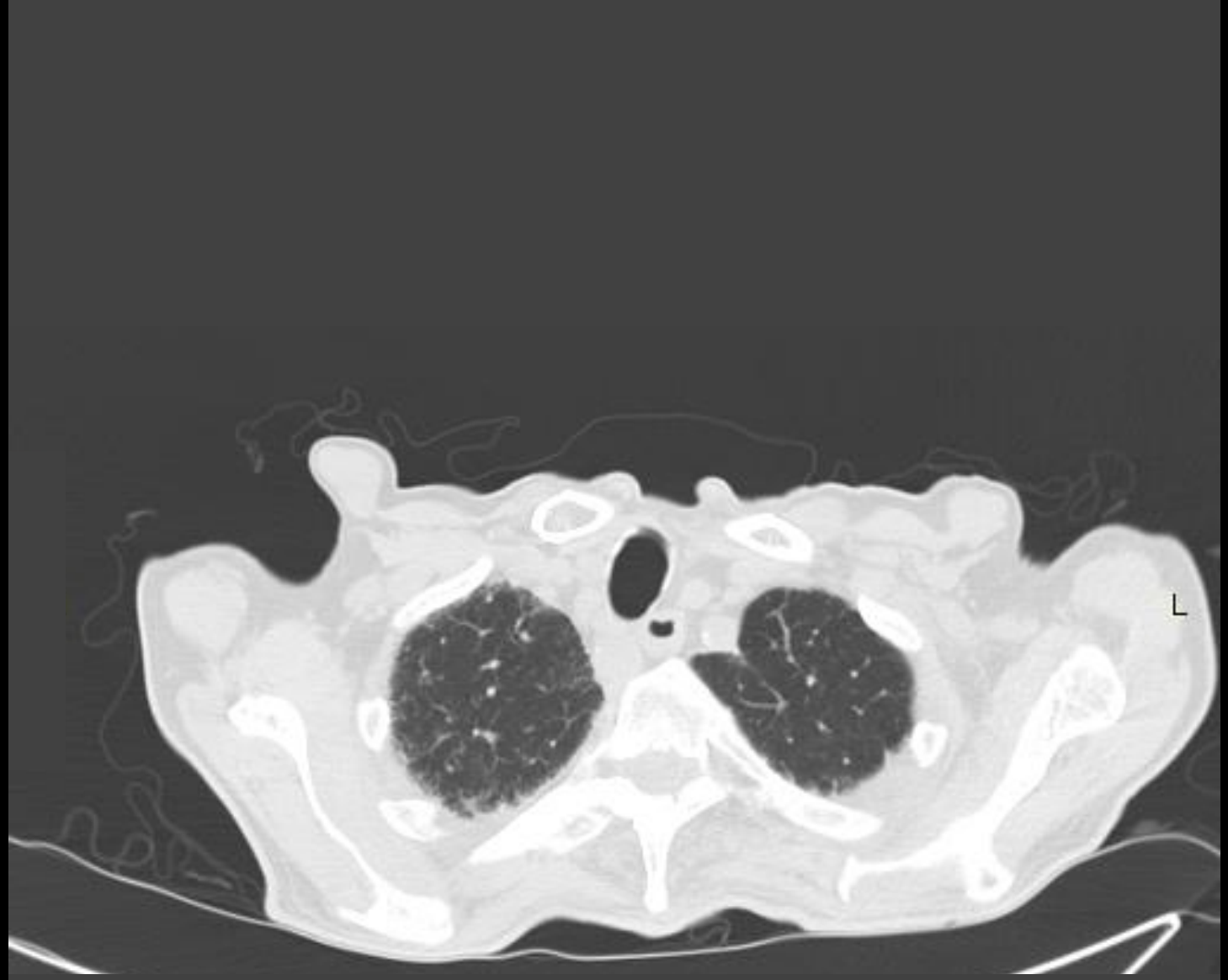
L

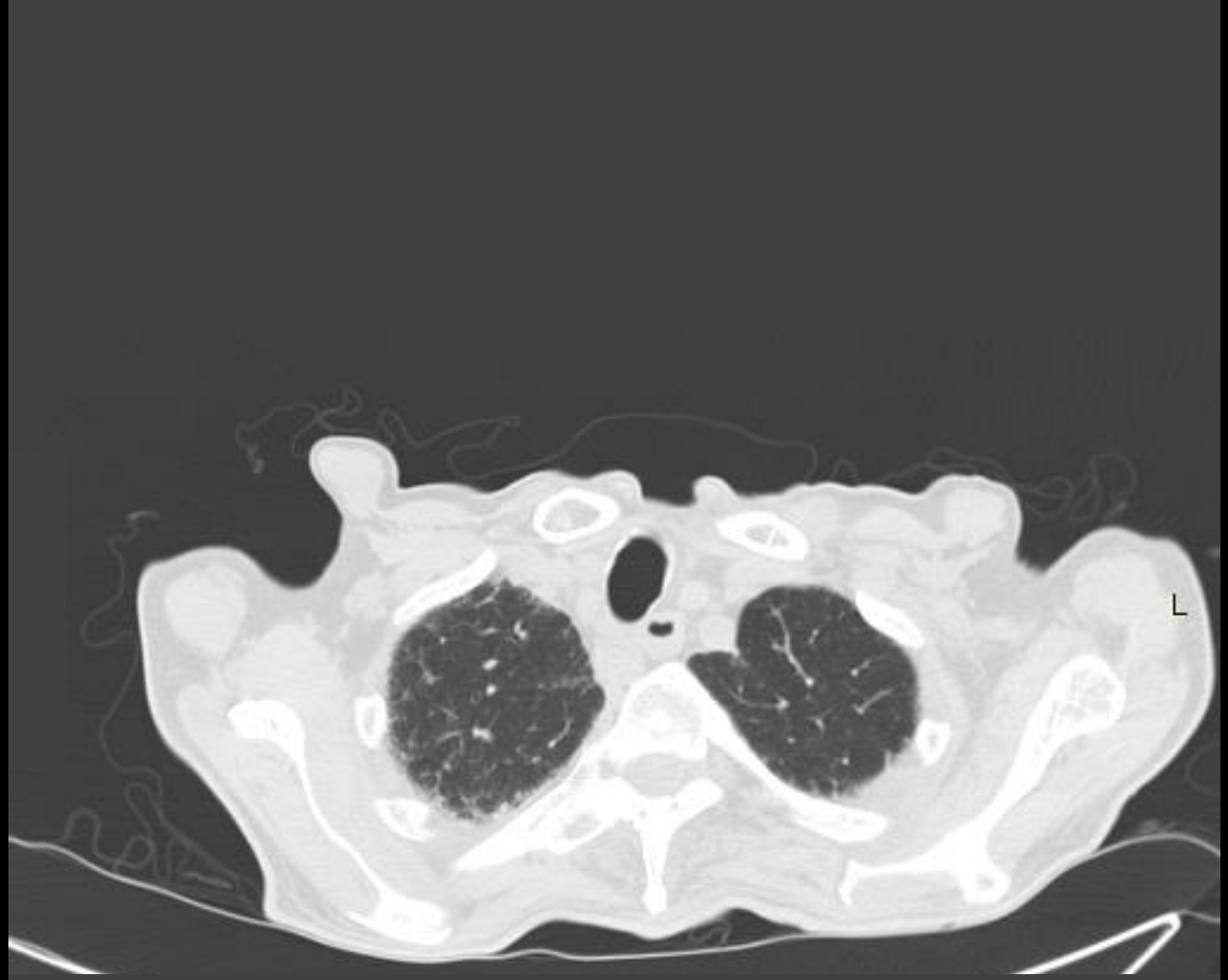
L

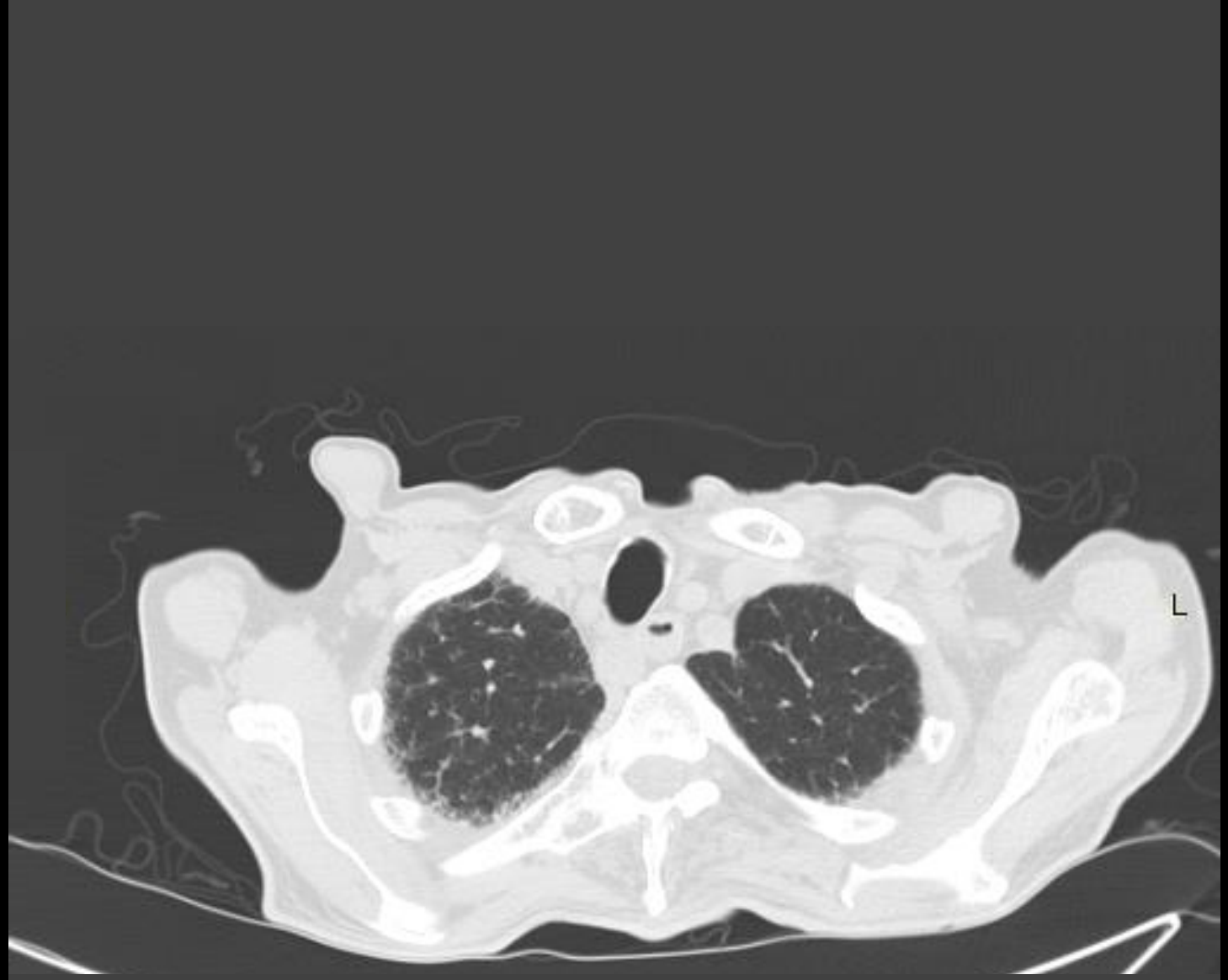
L

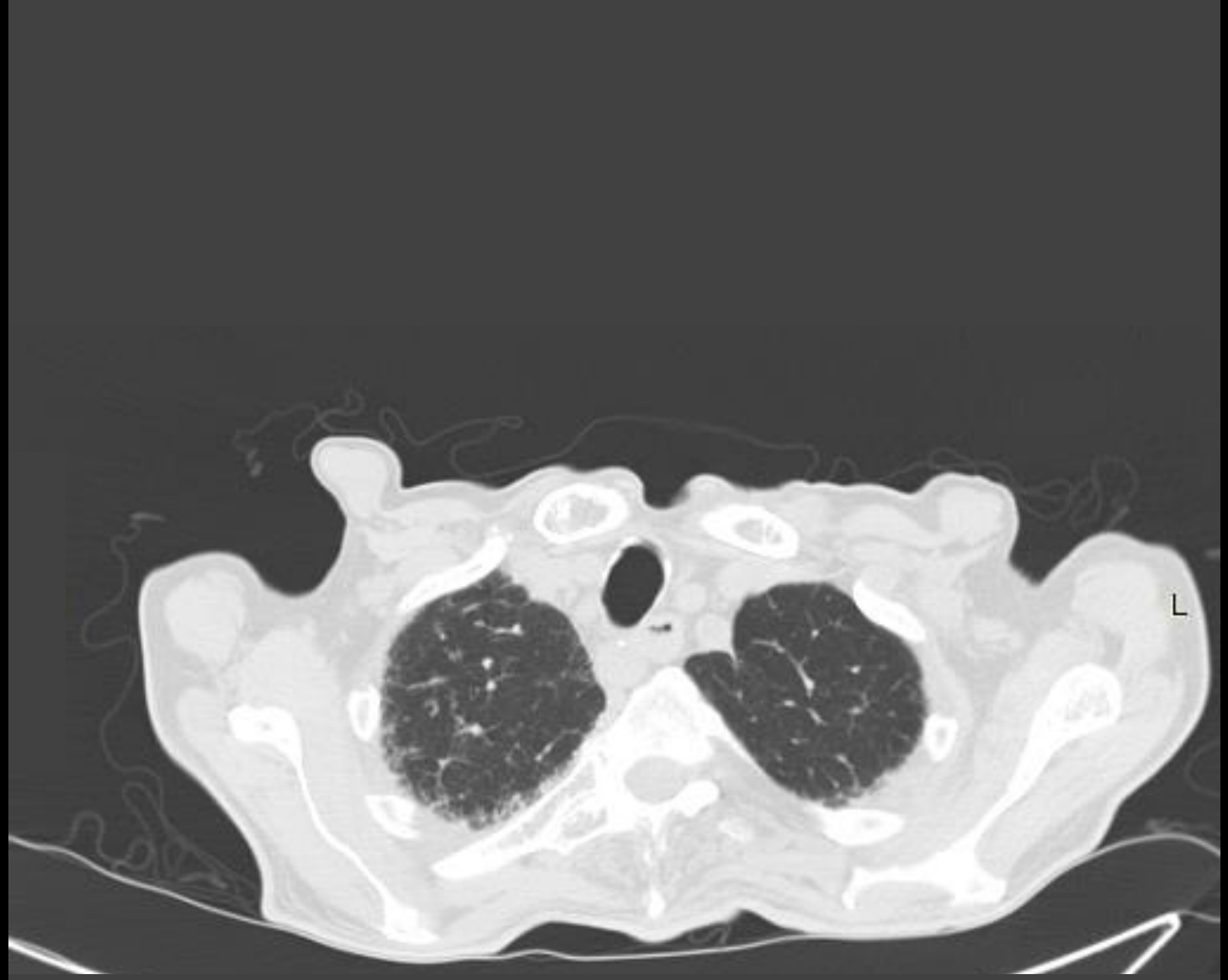
L

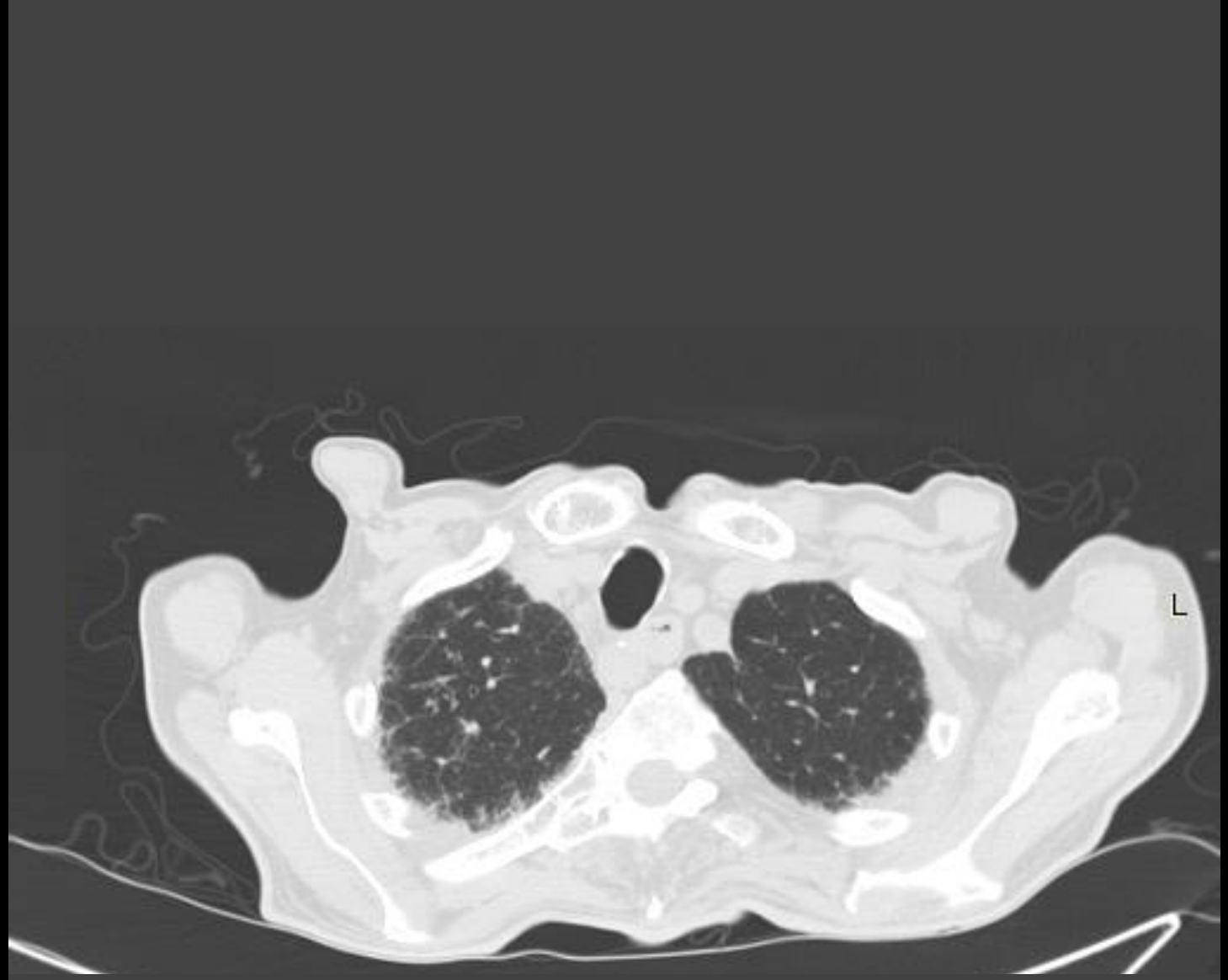
L

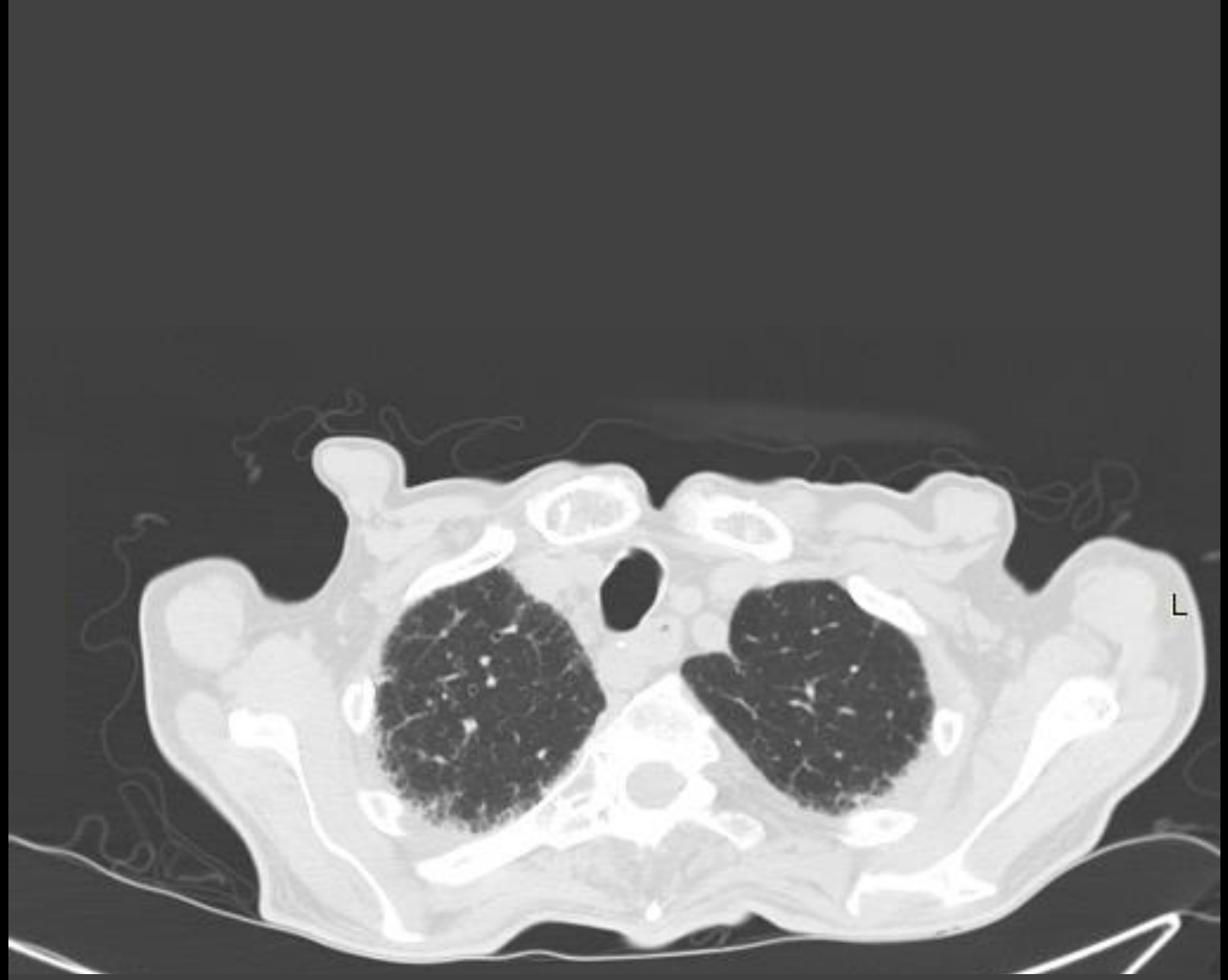
L

L

L

L

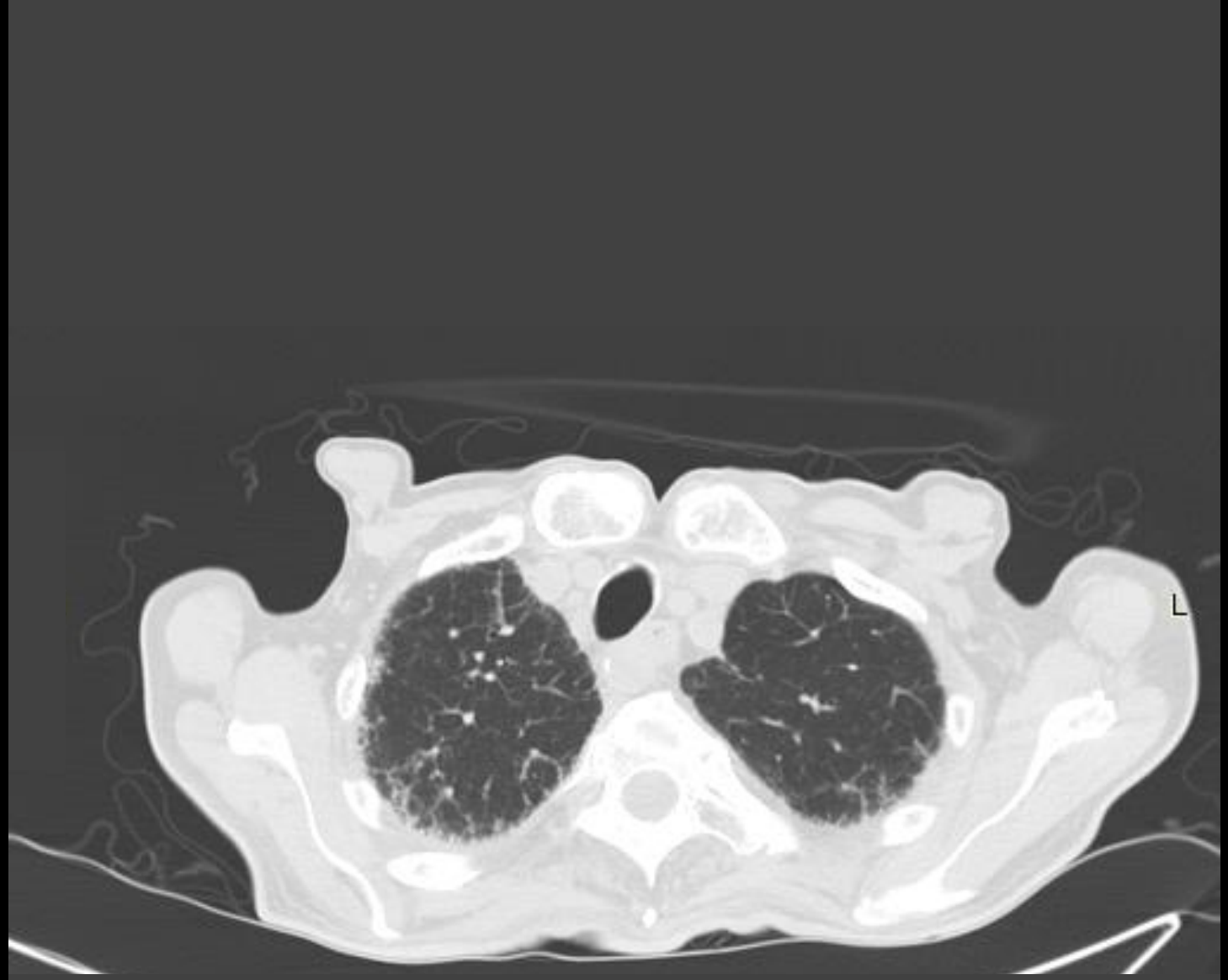
L

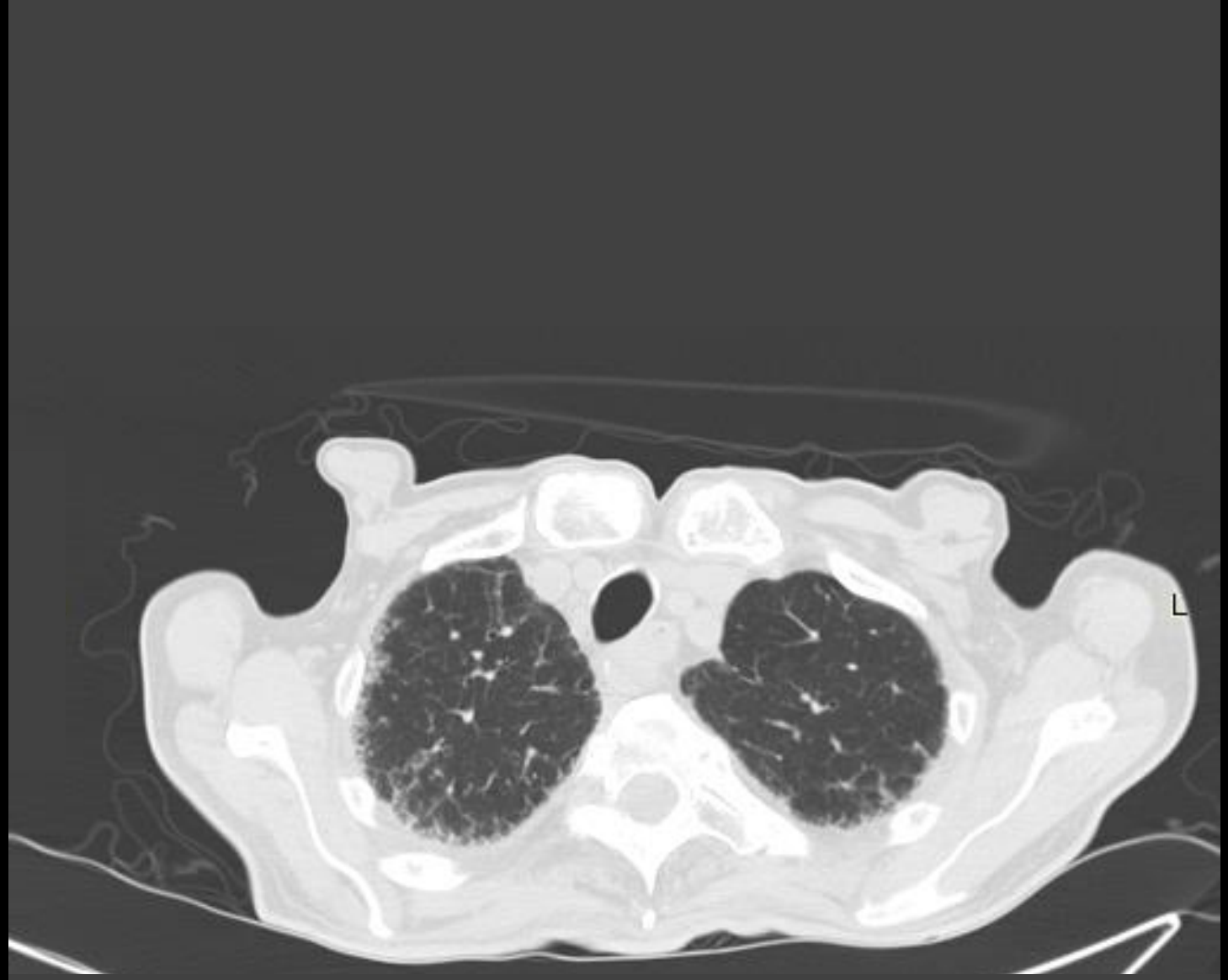
L

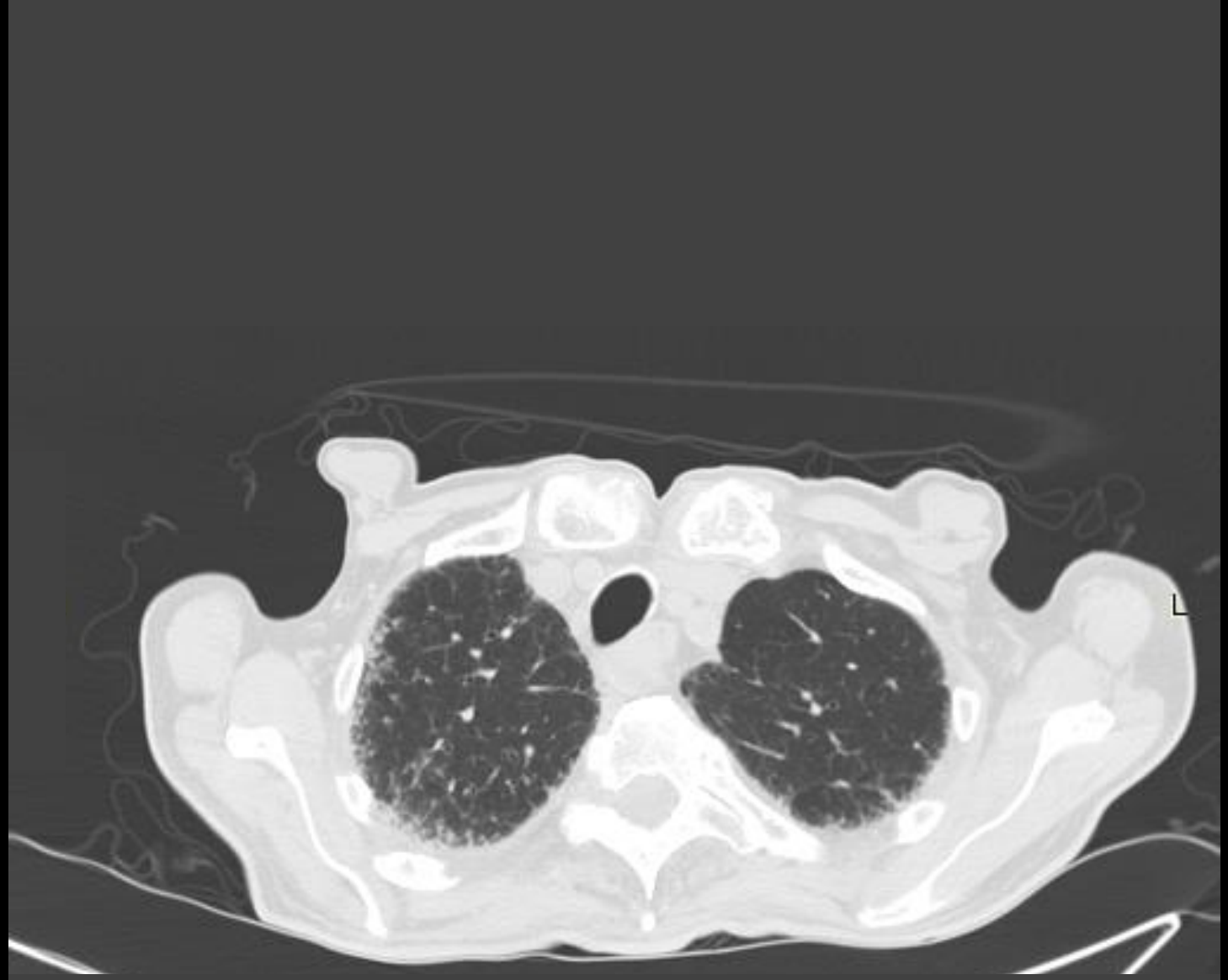
L

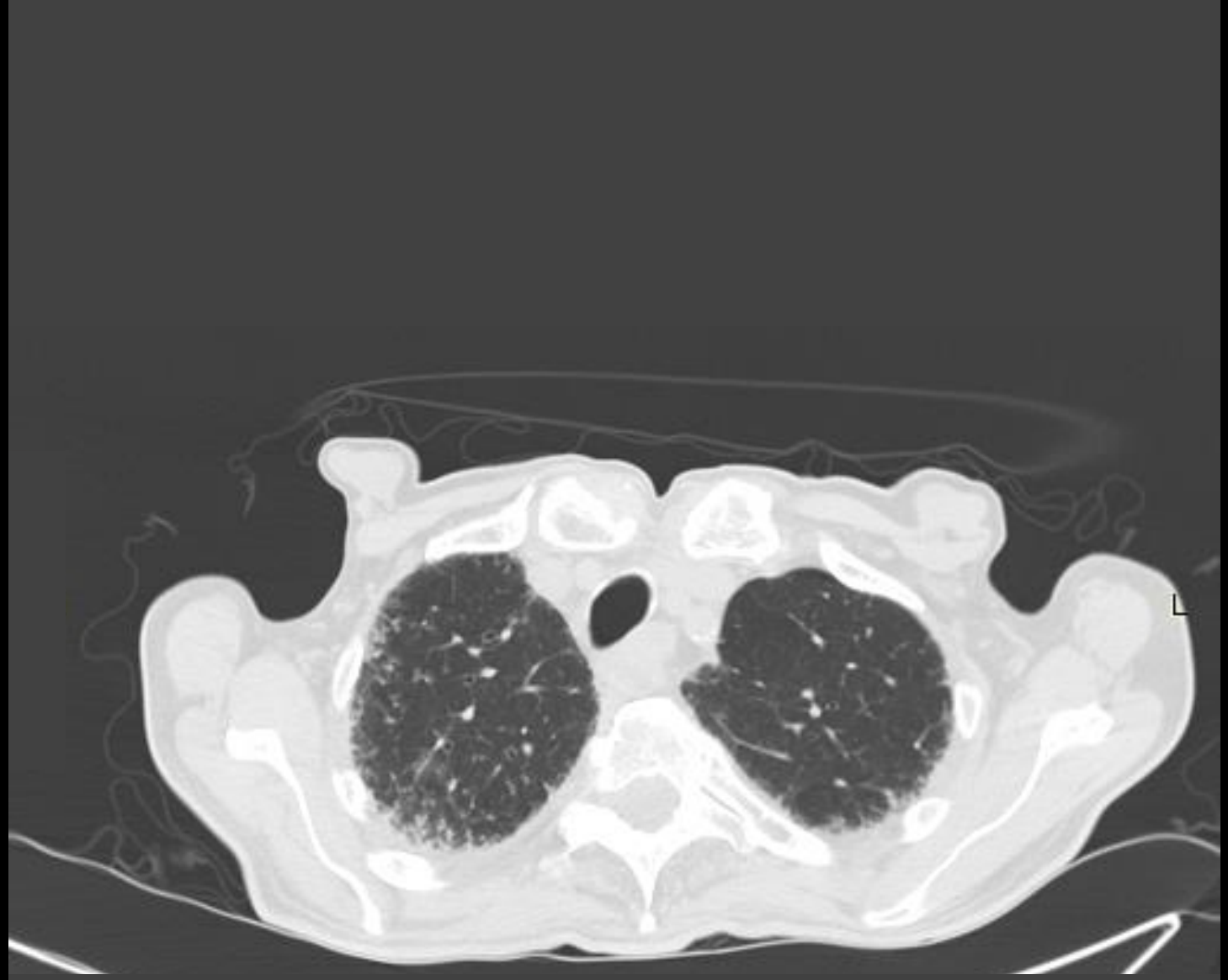
L

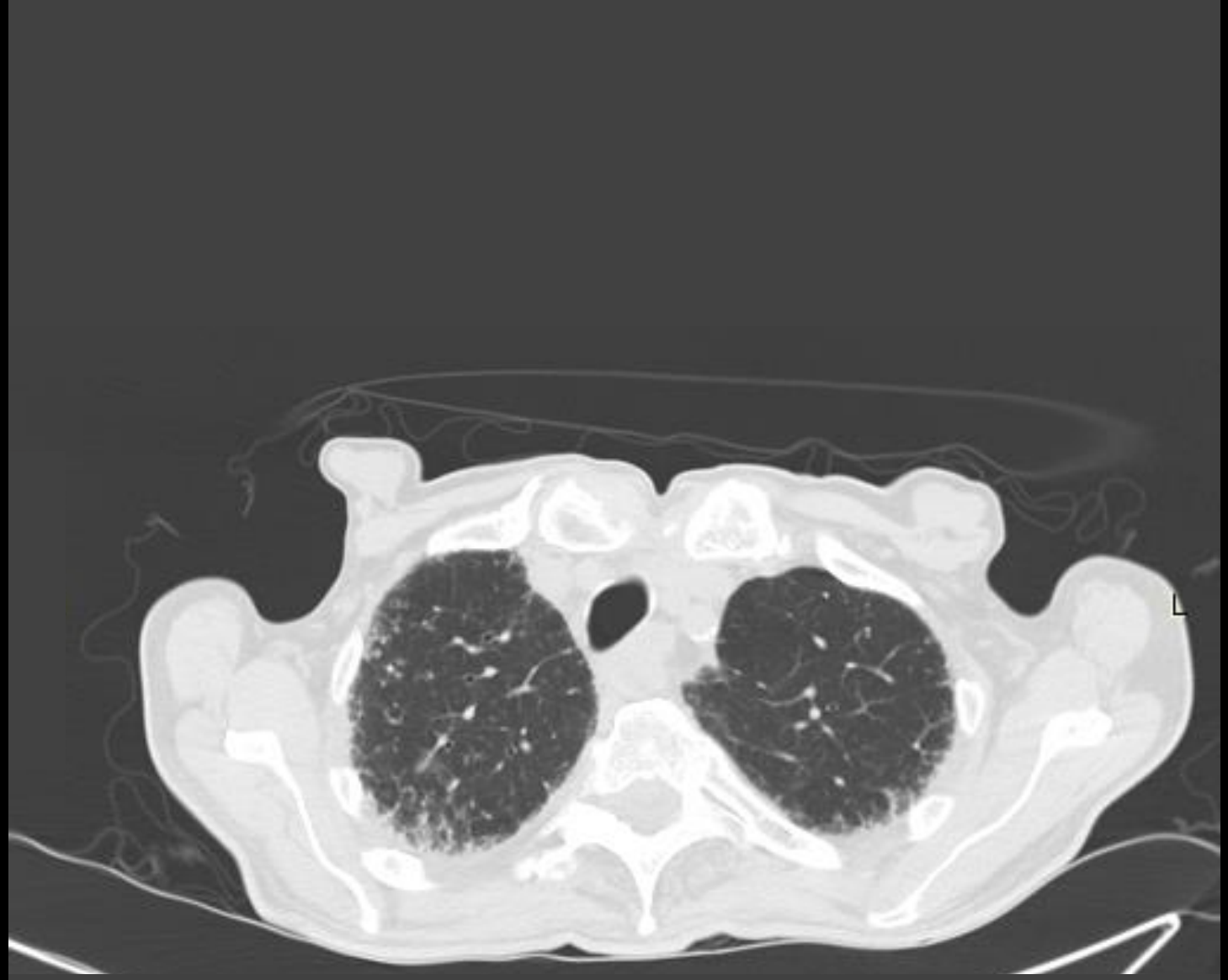
L

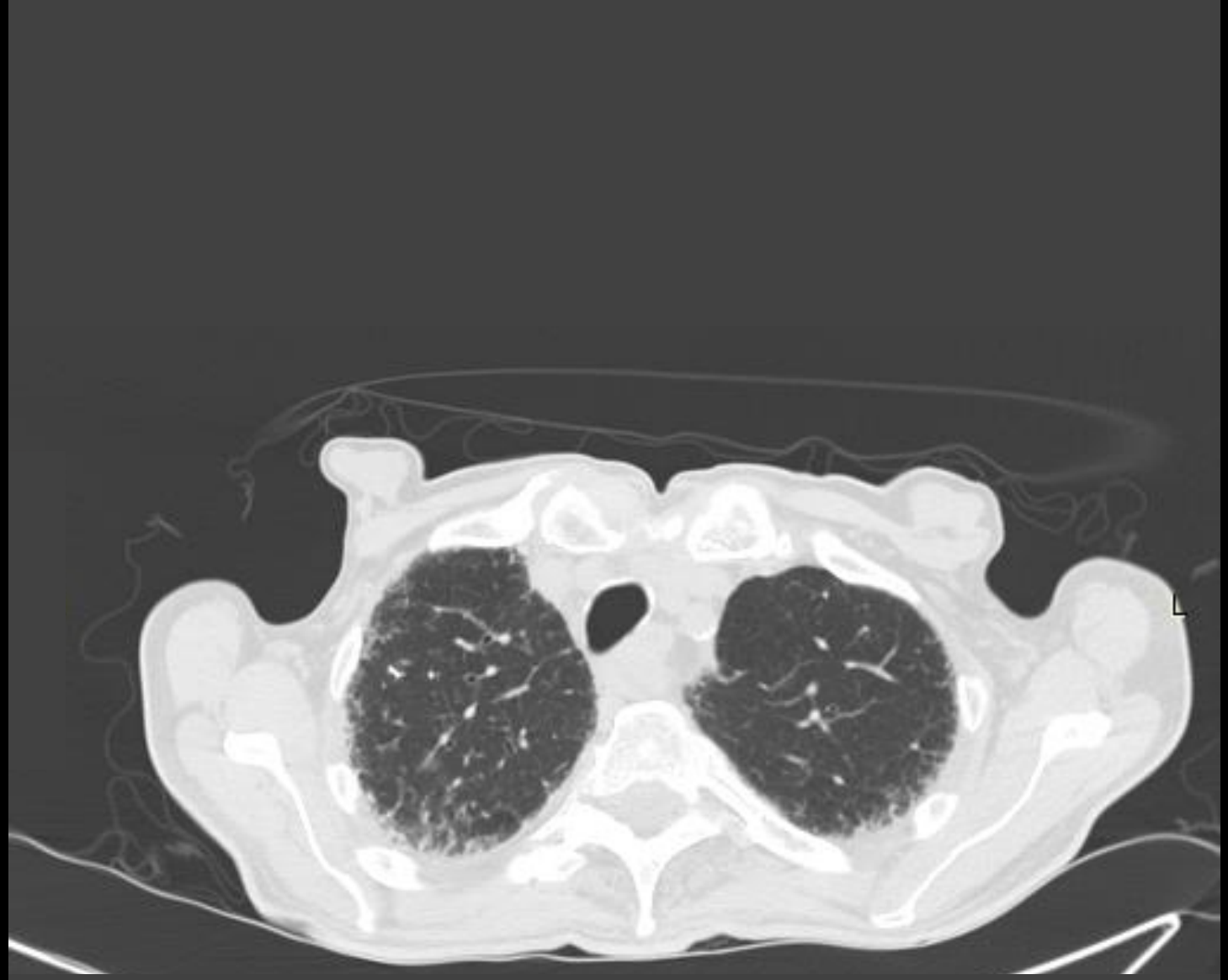
L

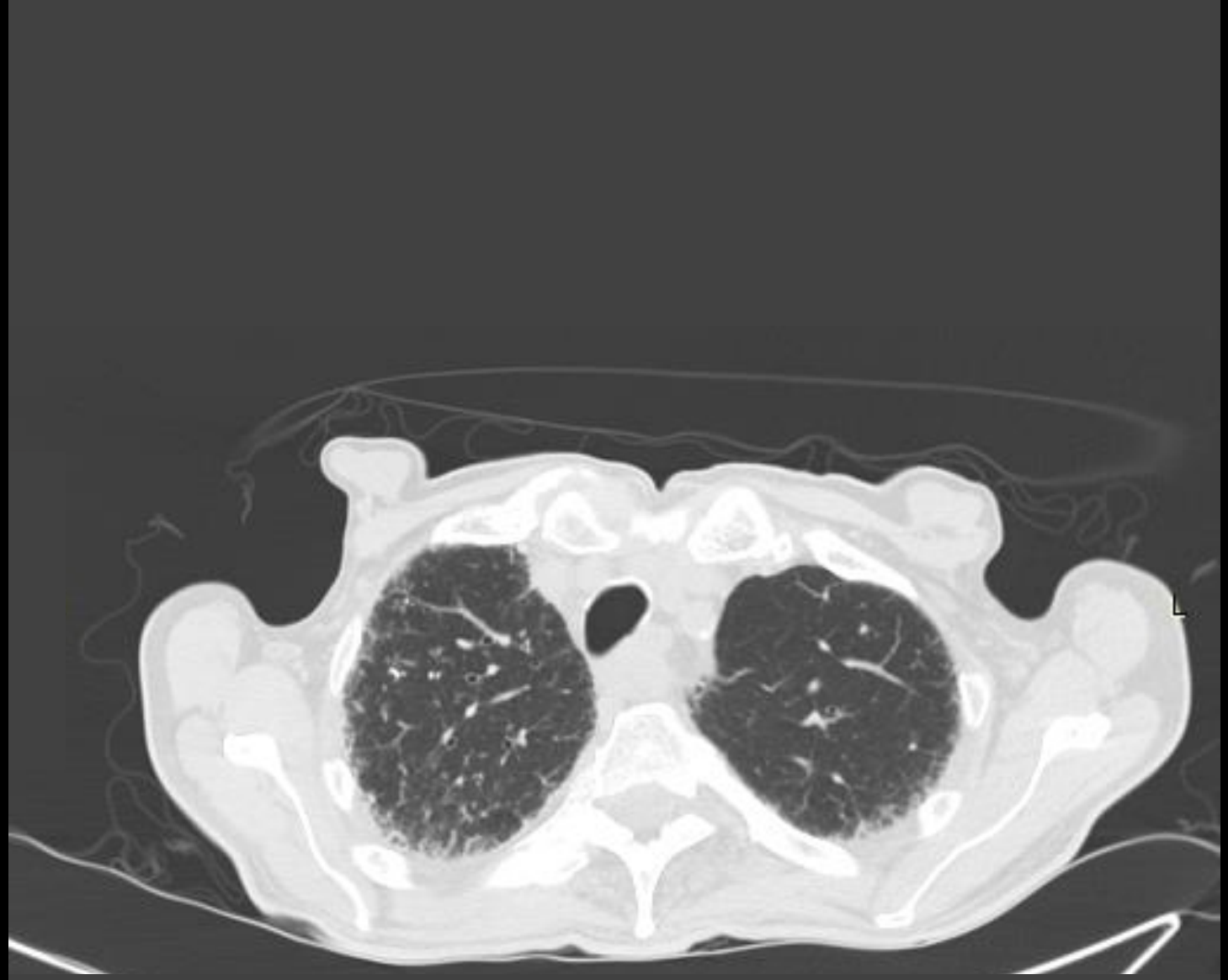
L

L

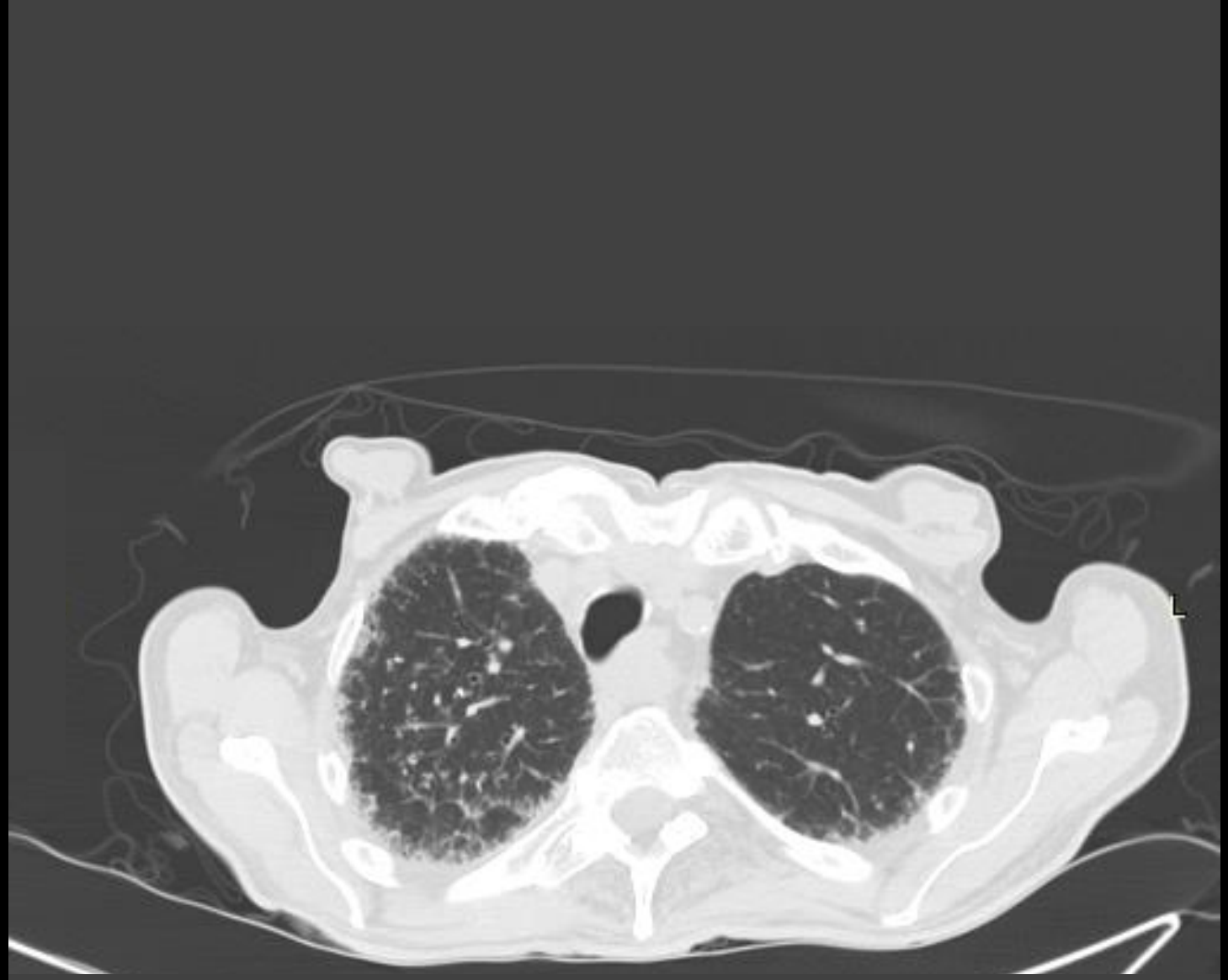
L

L

L

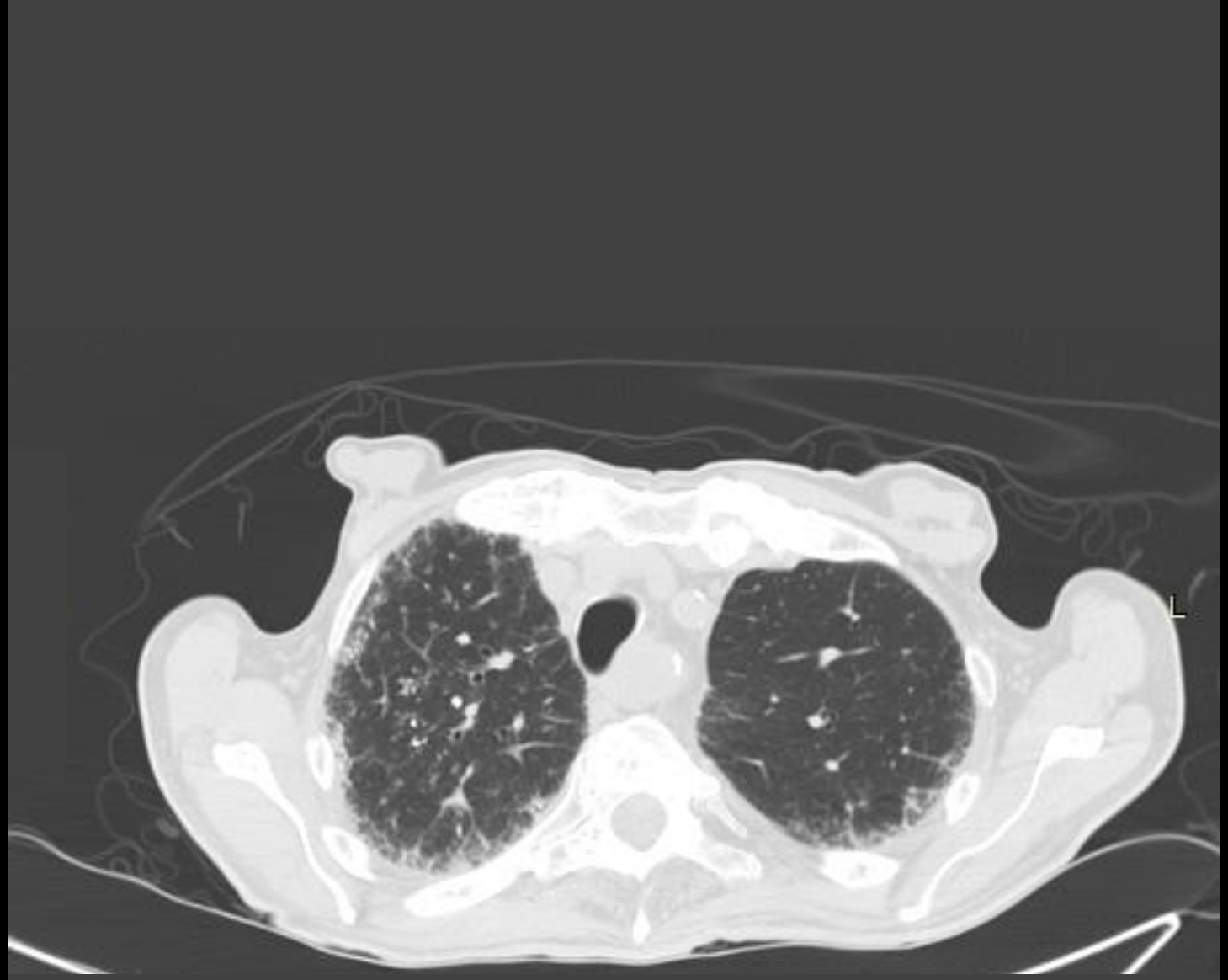
L

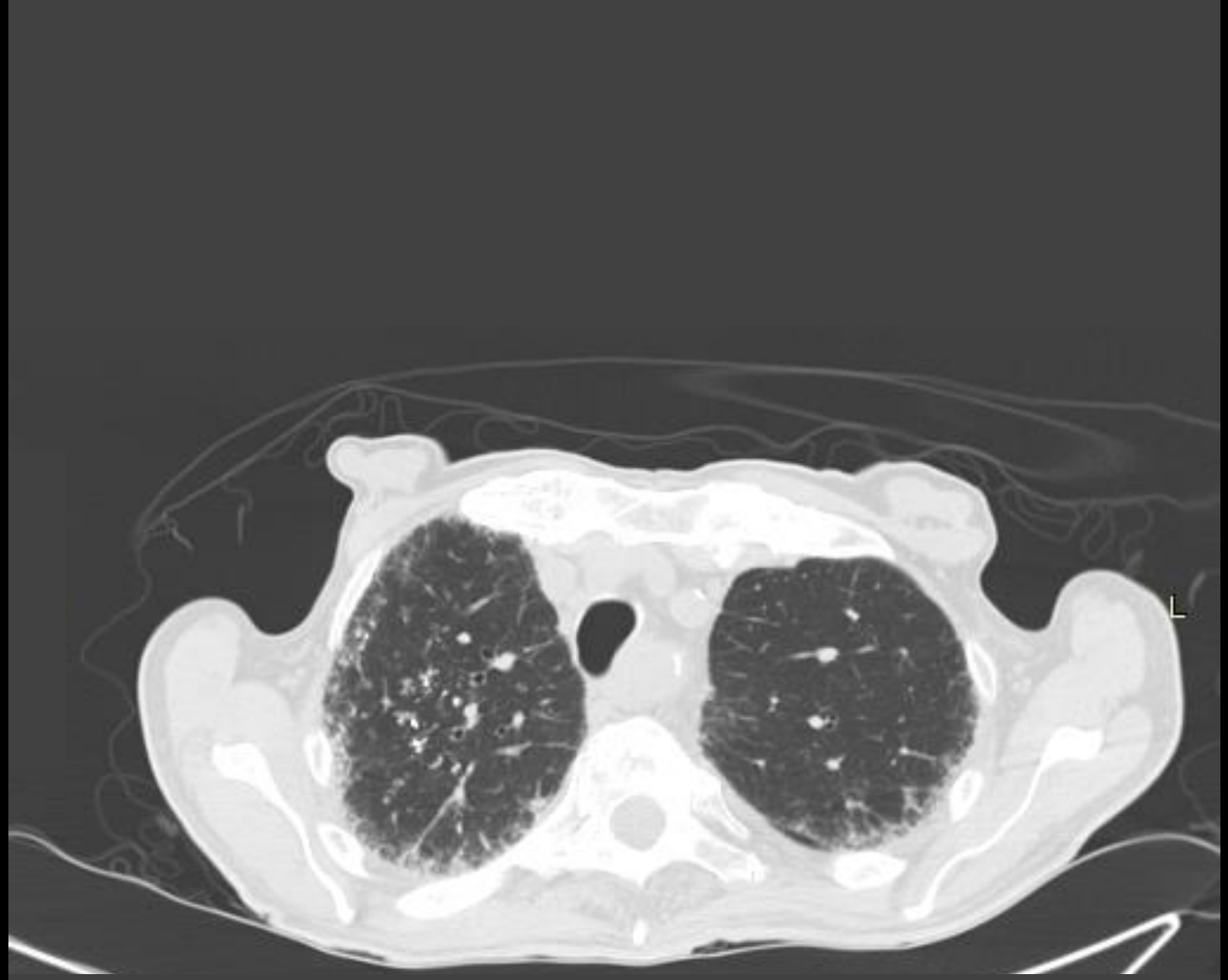
L

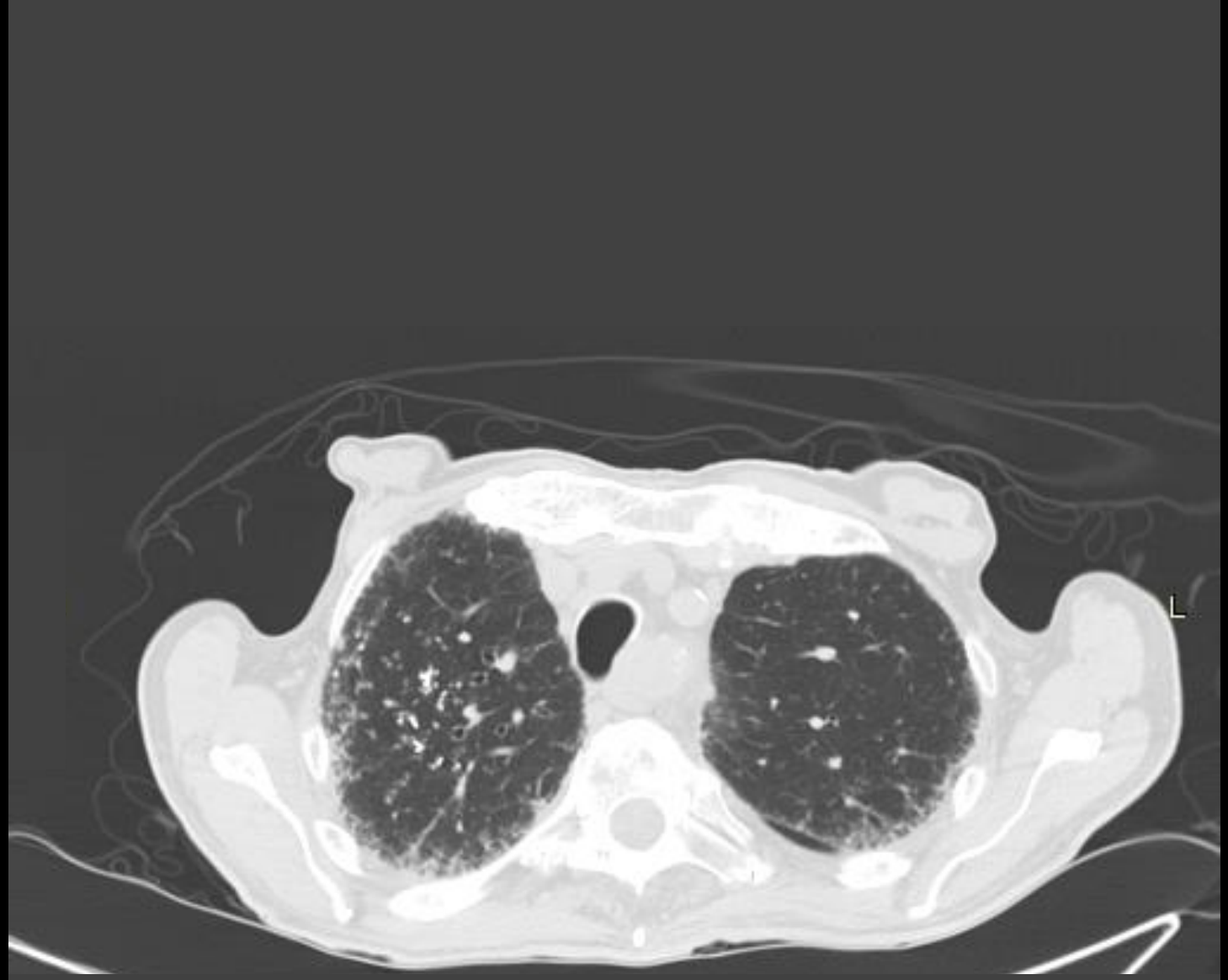
L

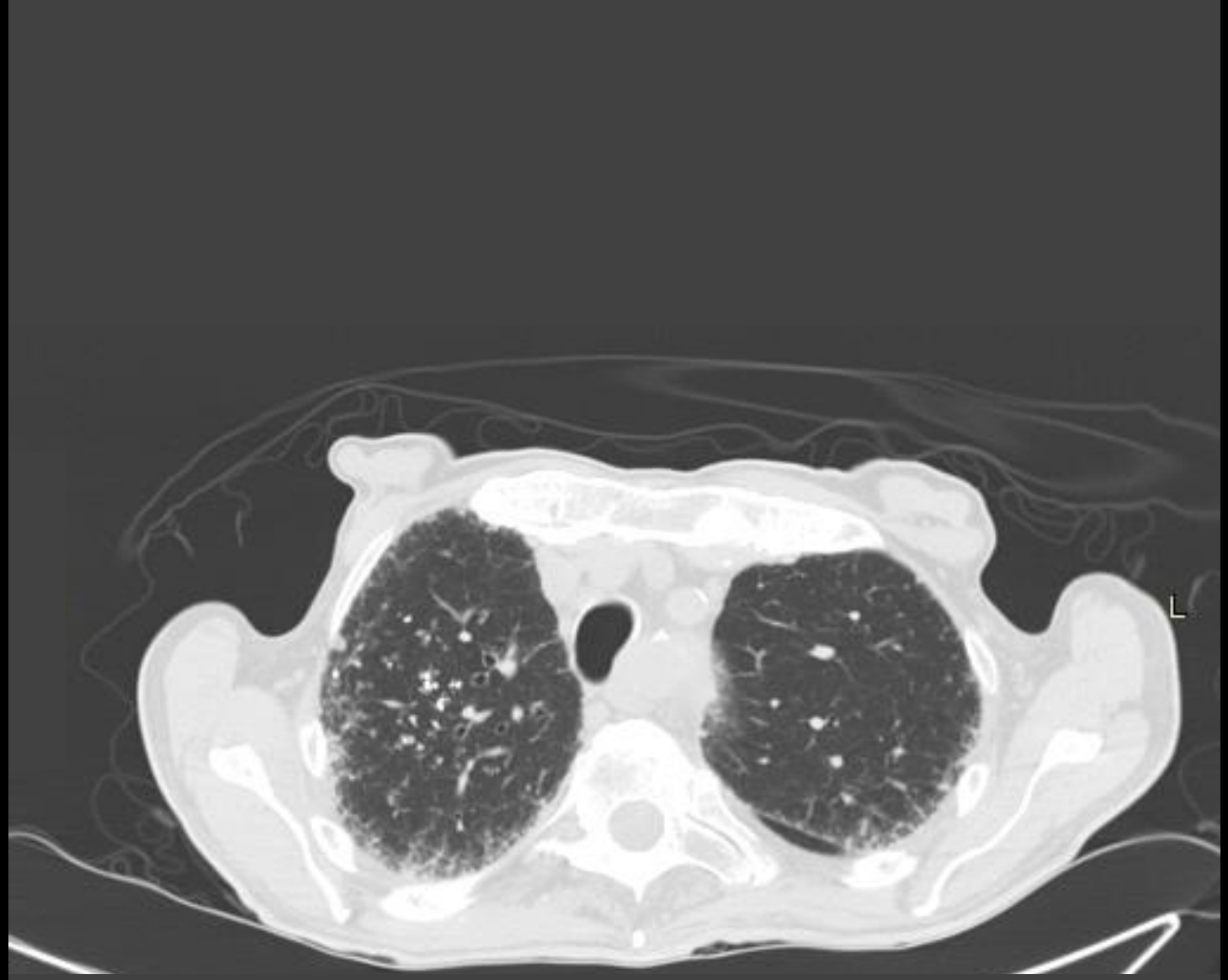
L

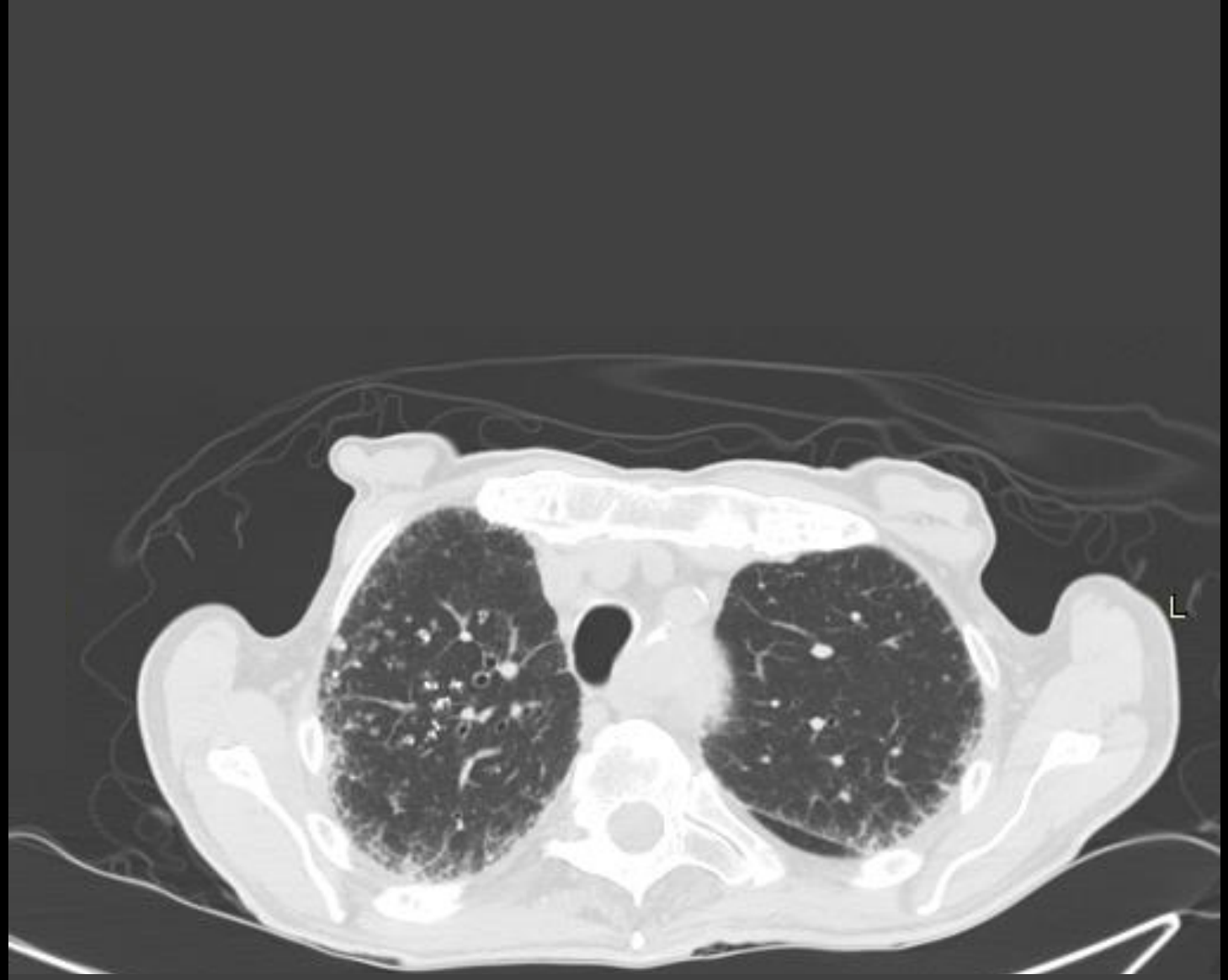
L

L

L

L

L

L

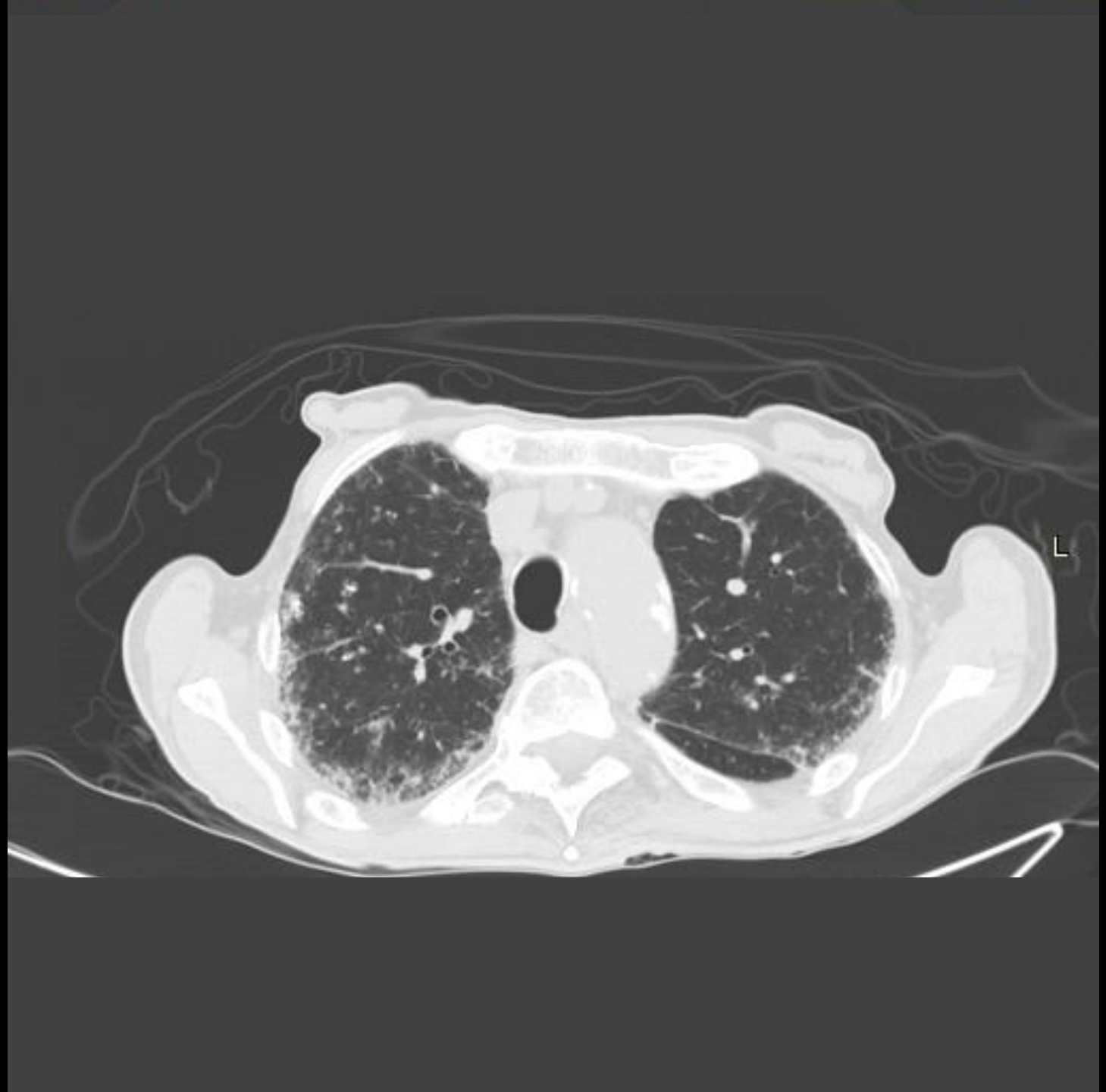
L

L

L

L

L

L

L

L

L

L

L

L

L

L

L

L

L

L

L

L

L

L

L

L

L

L

L

L

L

L

L

L

L

L

L

L

L

L

L

L

L

L

L

L

L

L

L

L

L

L

L

L

L

L

L

L

L

L

L

L

L

L

L

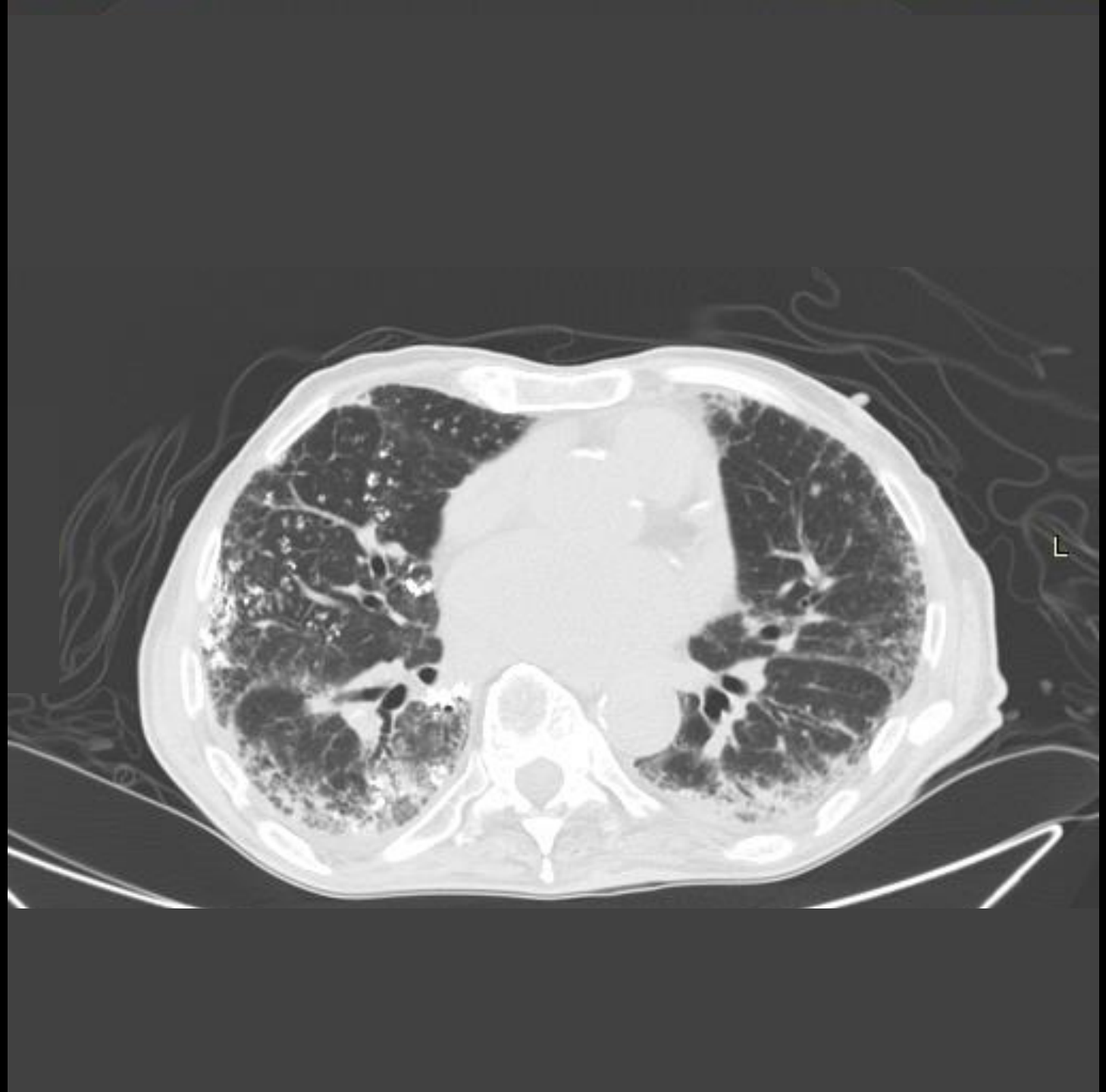
L

L

L

L

L

L

L

L

L

L

L

L

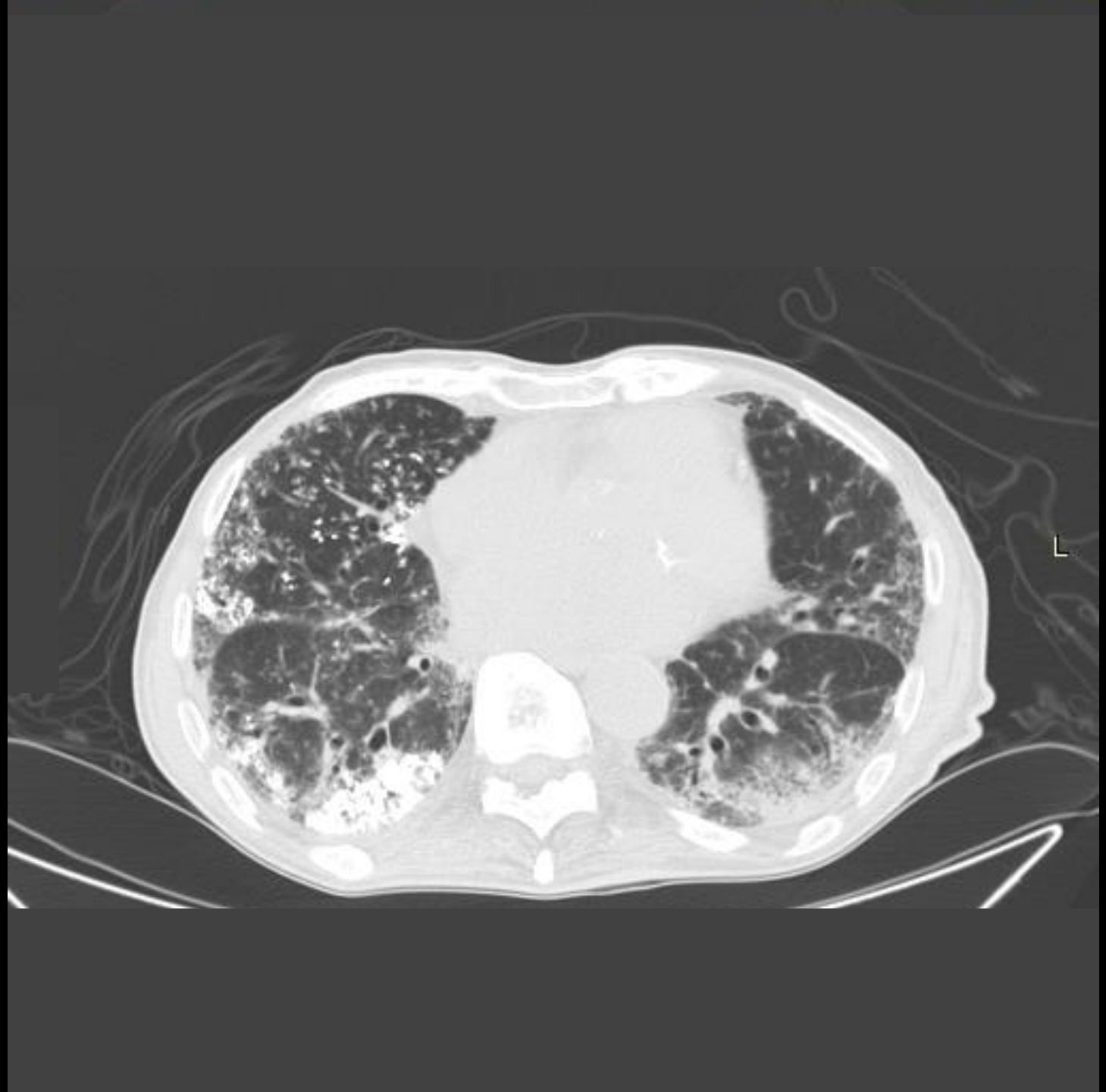
L

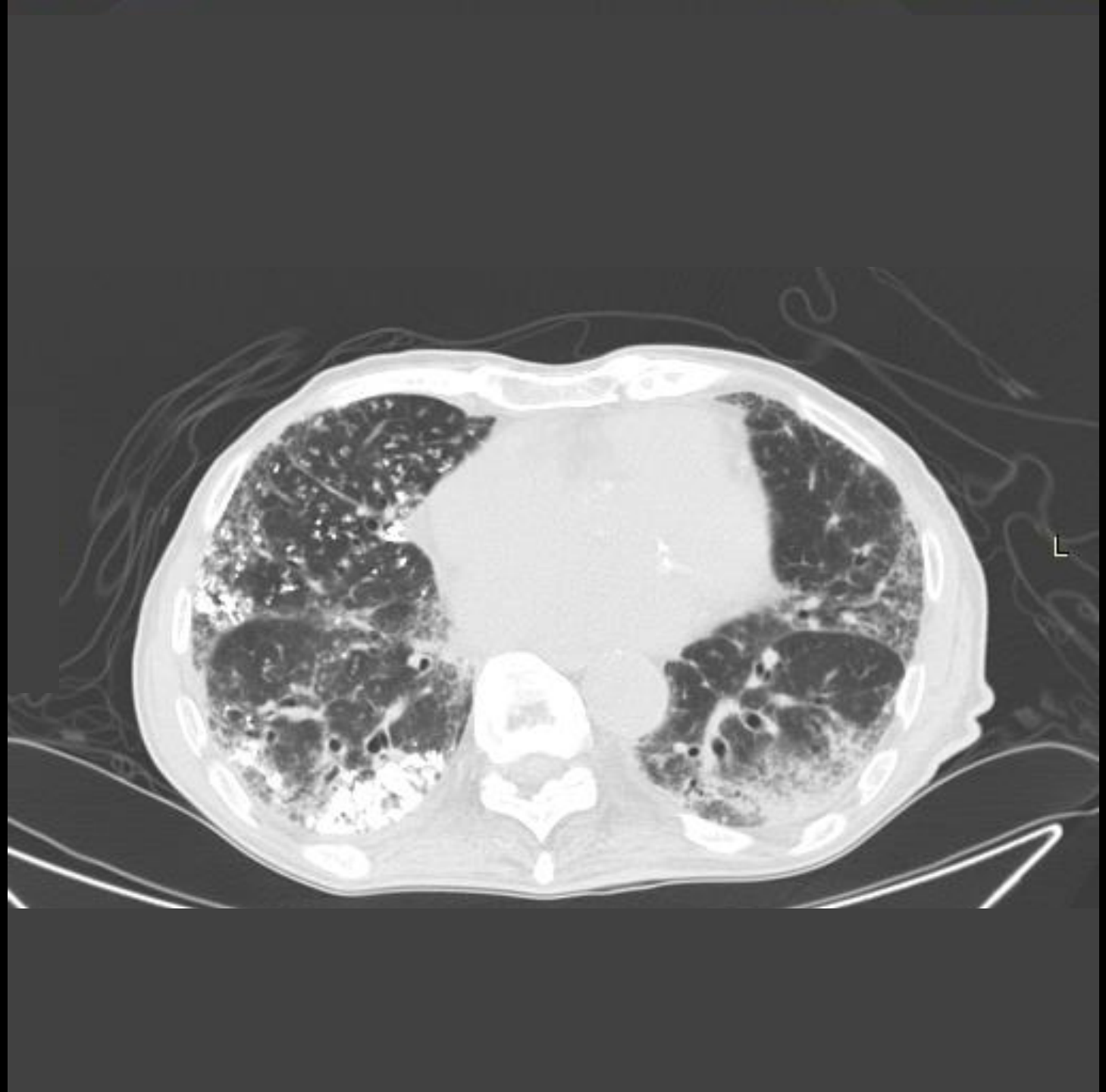
L

L

L

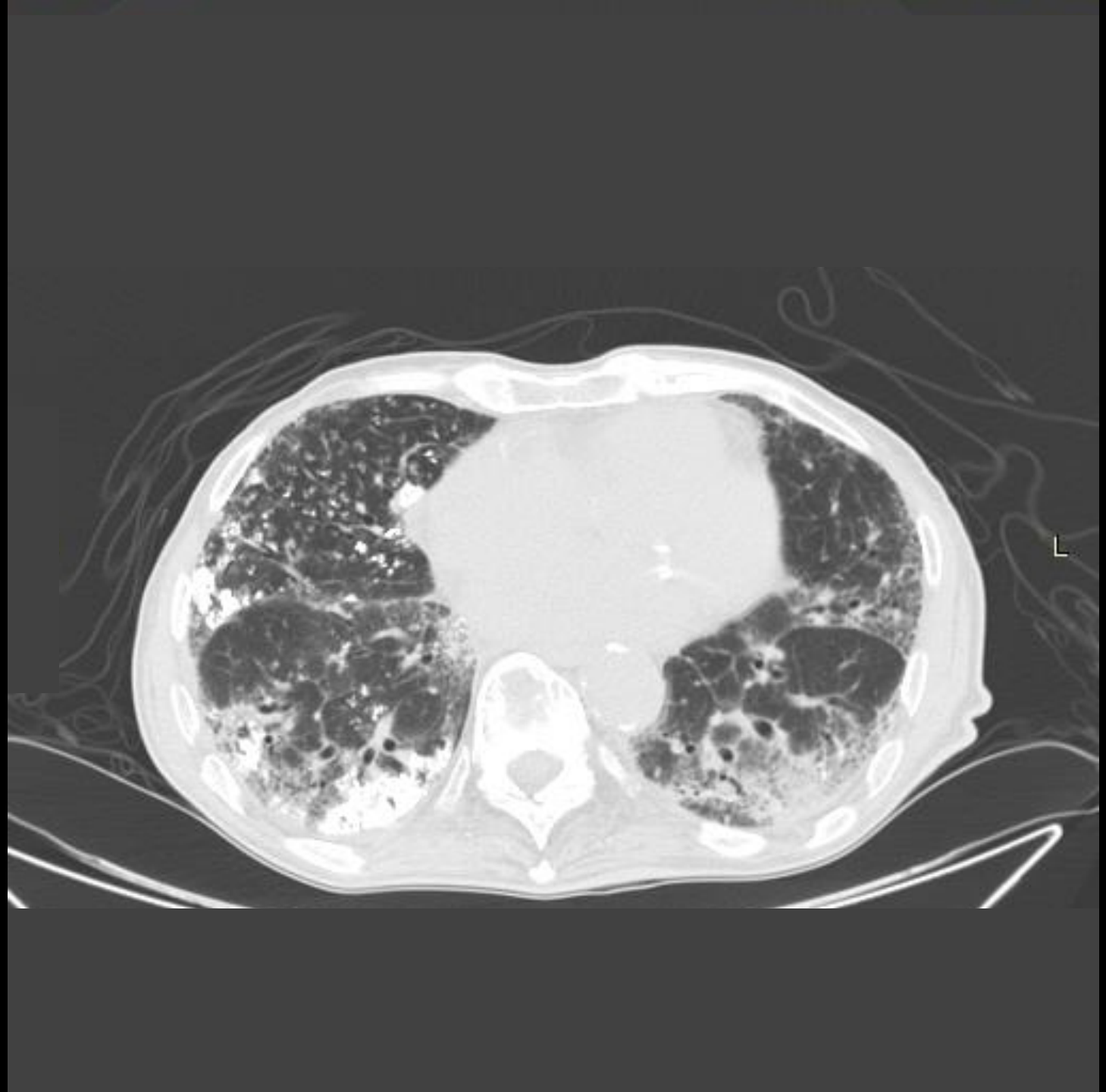
L

L

L

L

L

L

L

L

L

L

L

L

L

L

L

L

L

L

L

L

L

L

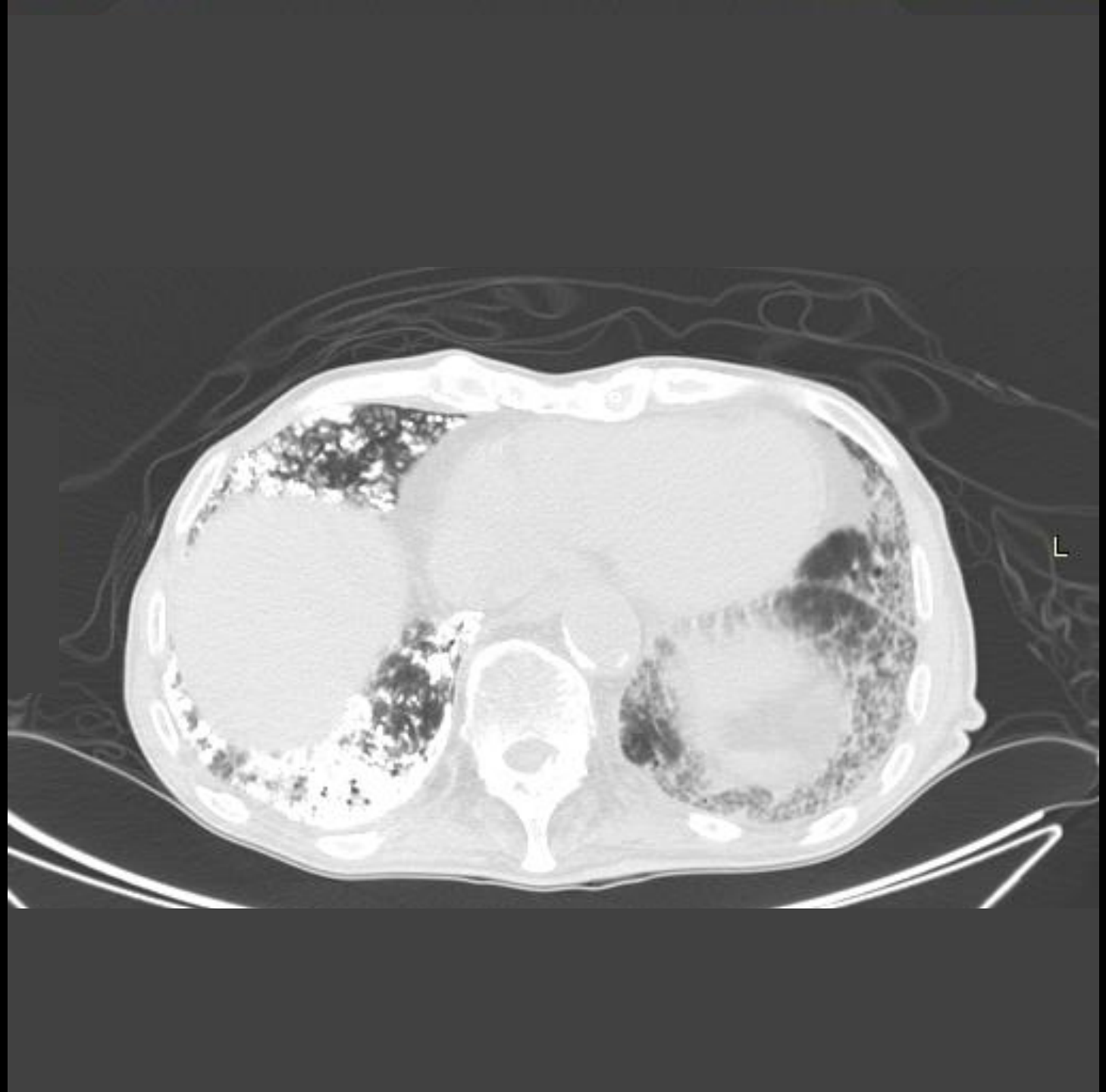
L

L

L

L

L

L

L

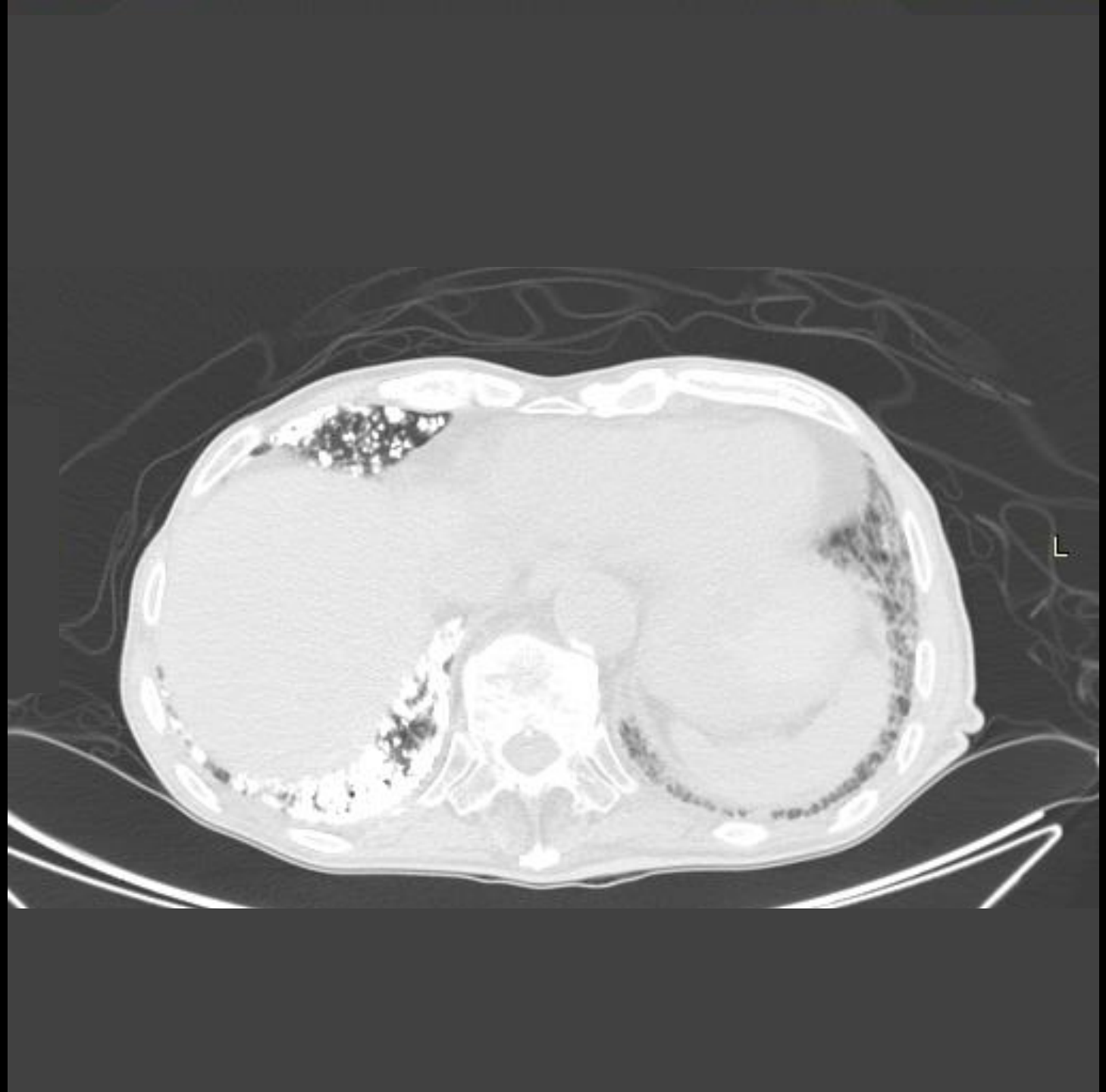
L

L

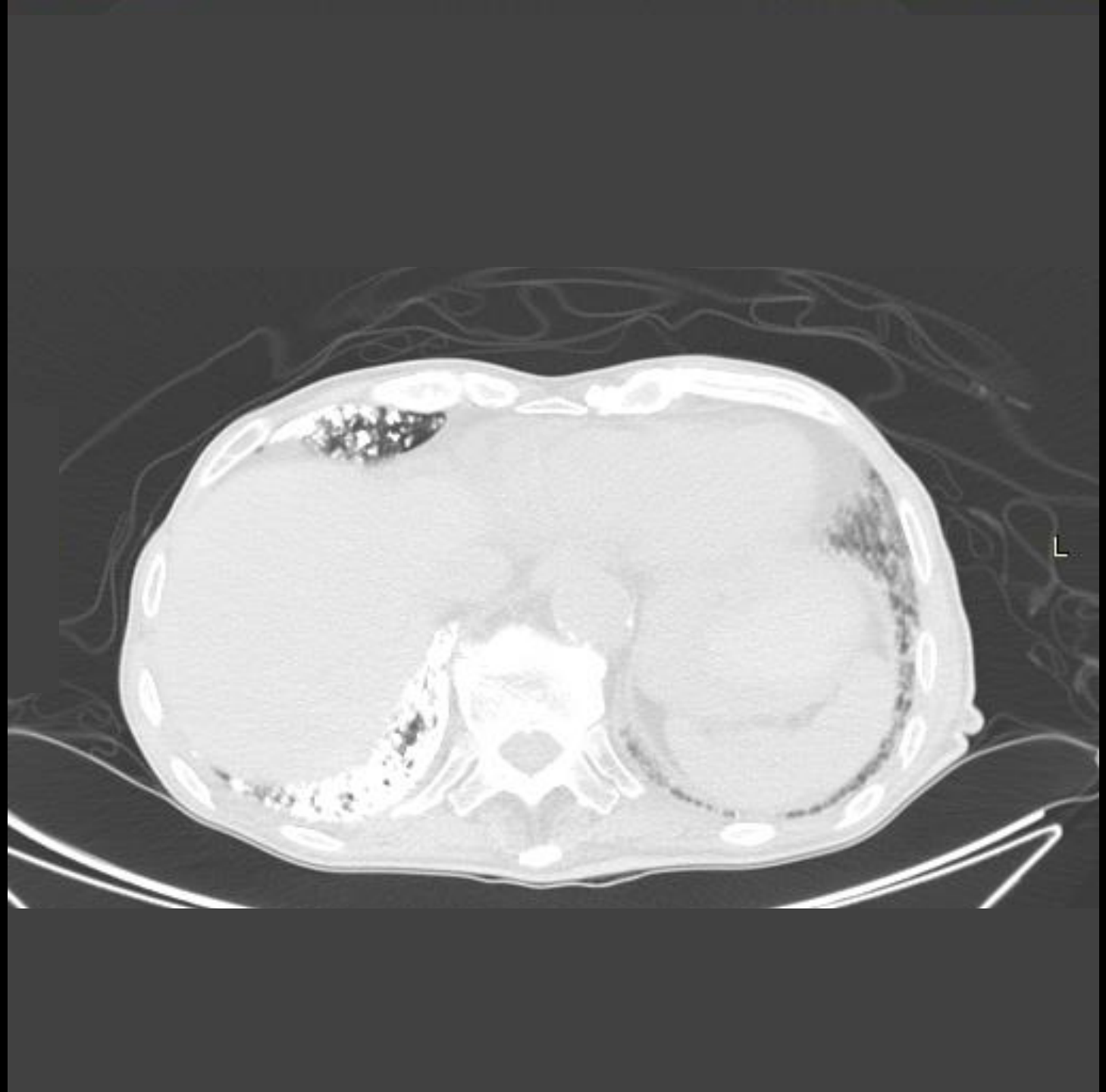
L

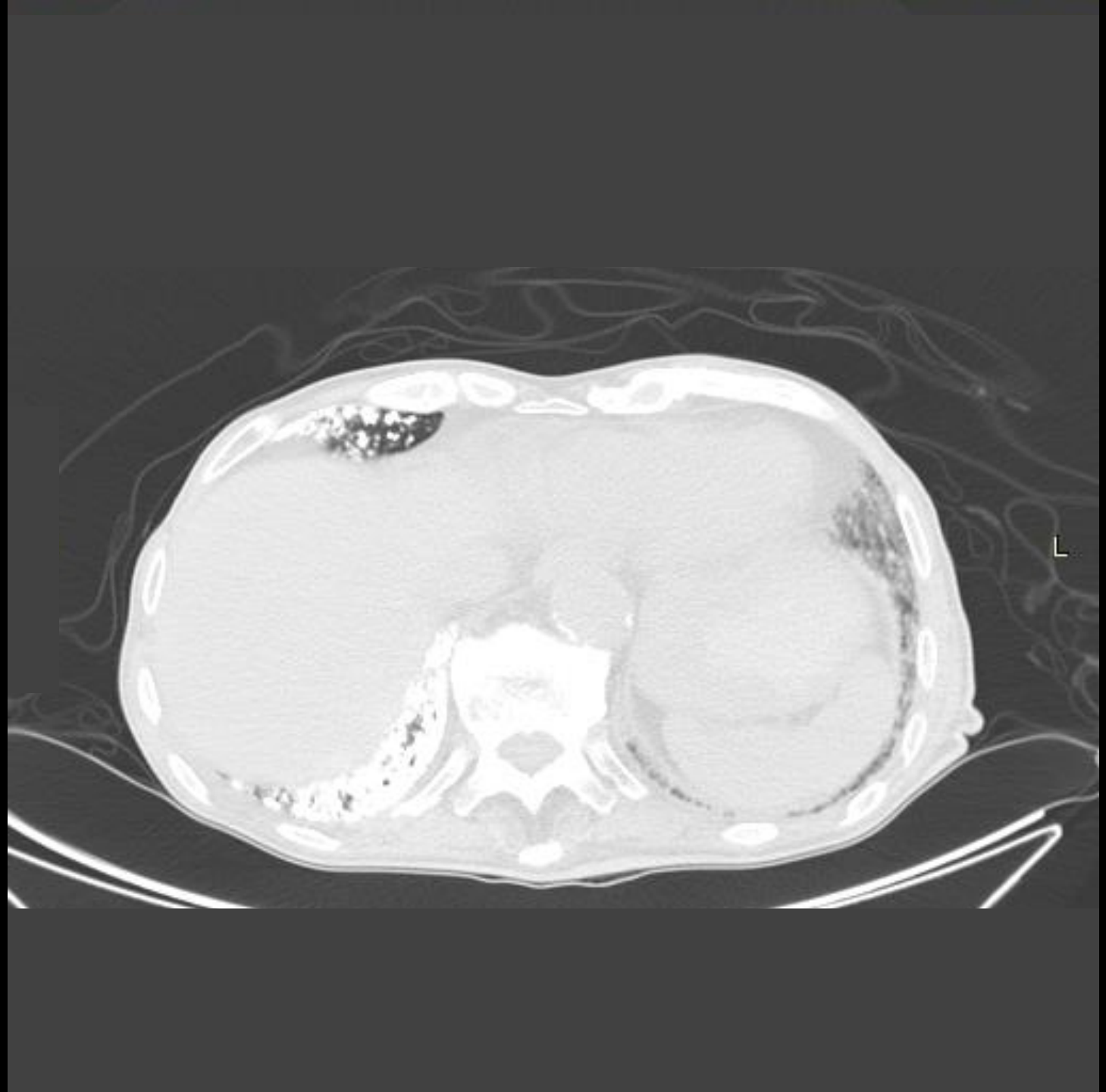
L

L

L

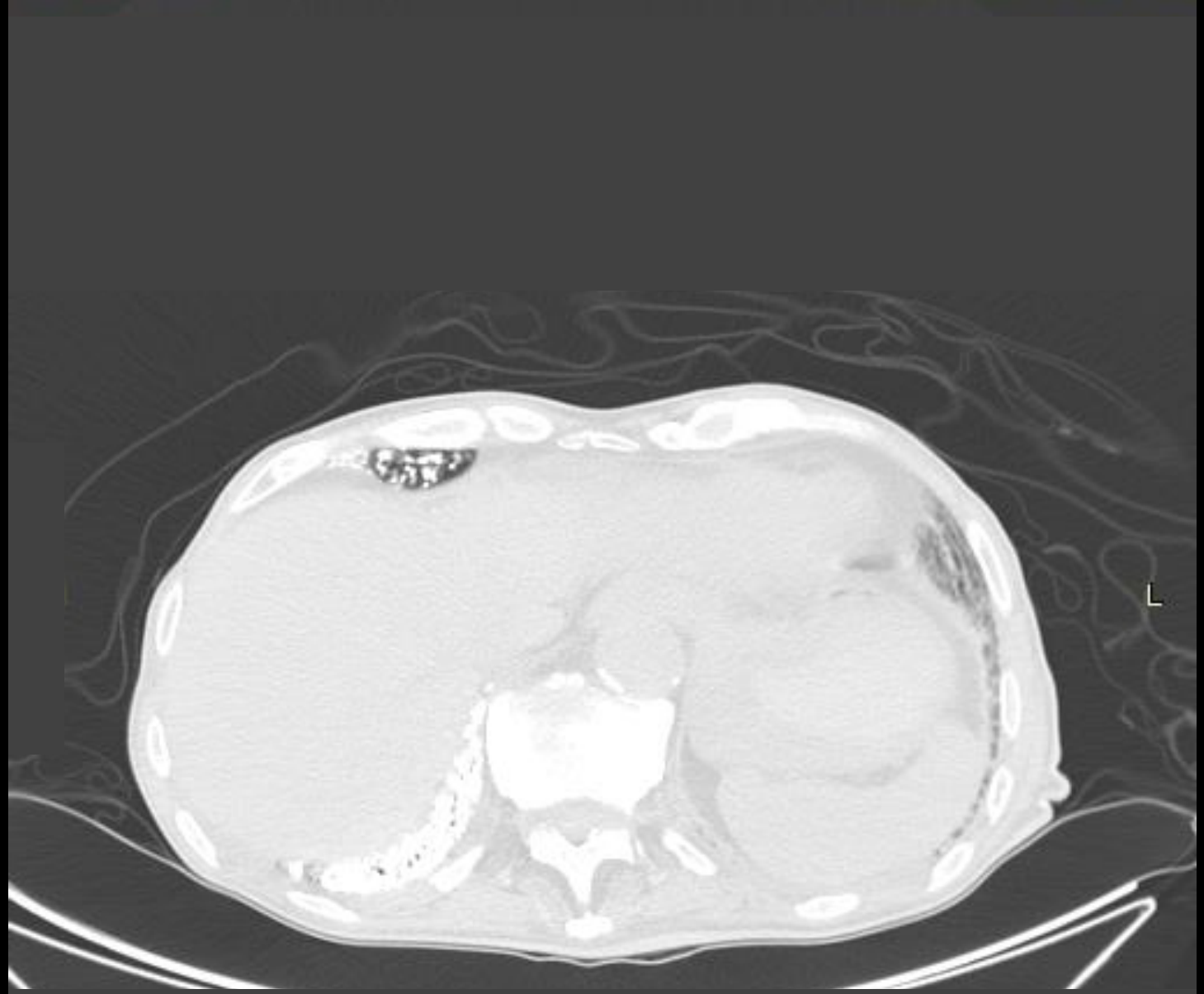
L

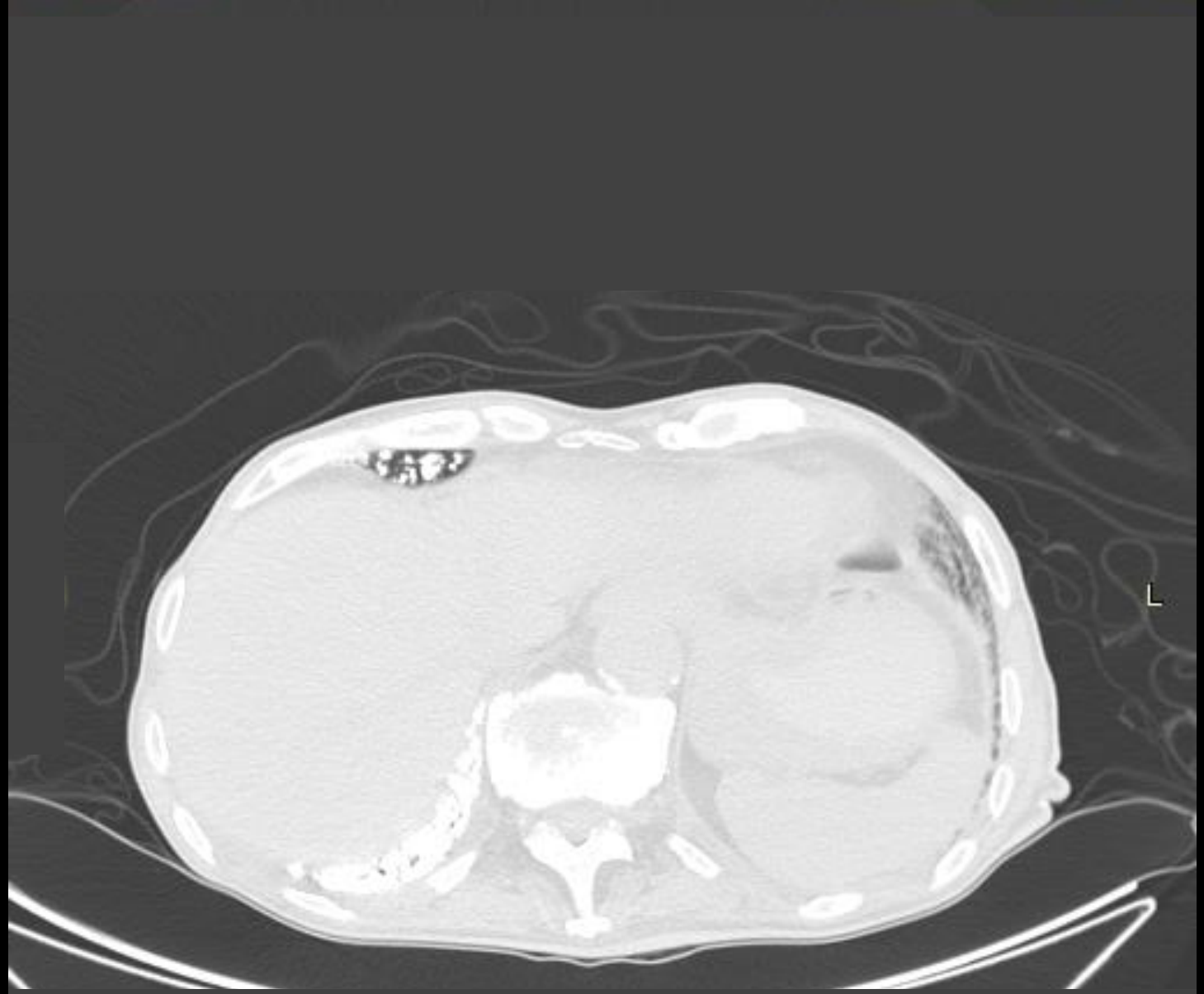
L

S
L

S
L

S
E85KHMA1OJ
TC do torax
CR
L

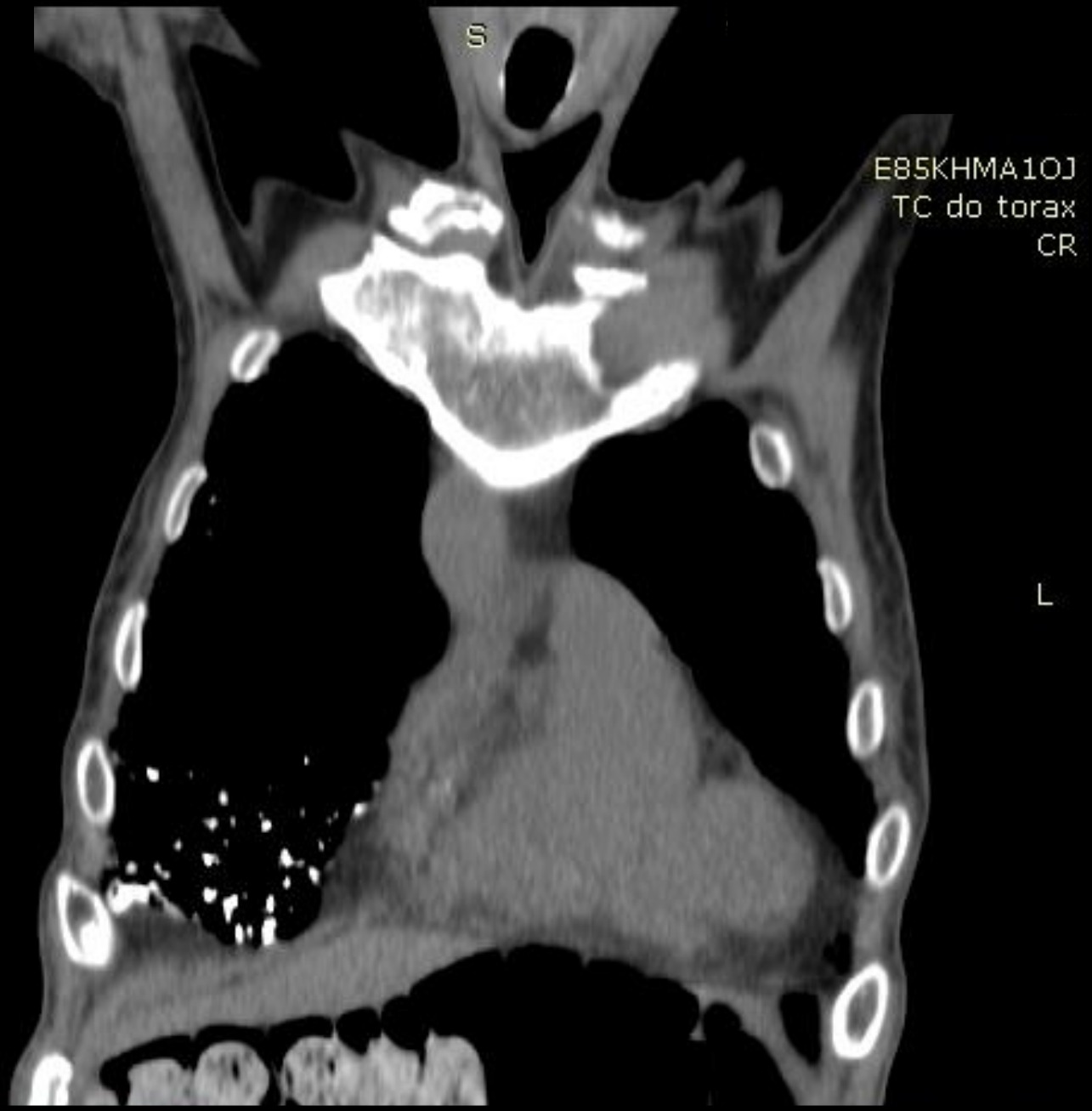
S
E85KHMA1OJ
TC do torax
CR
L

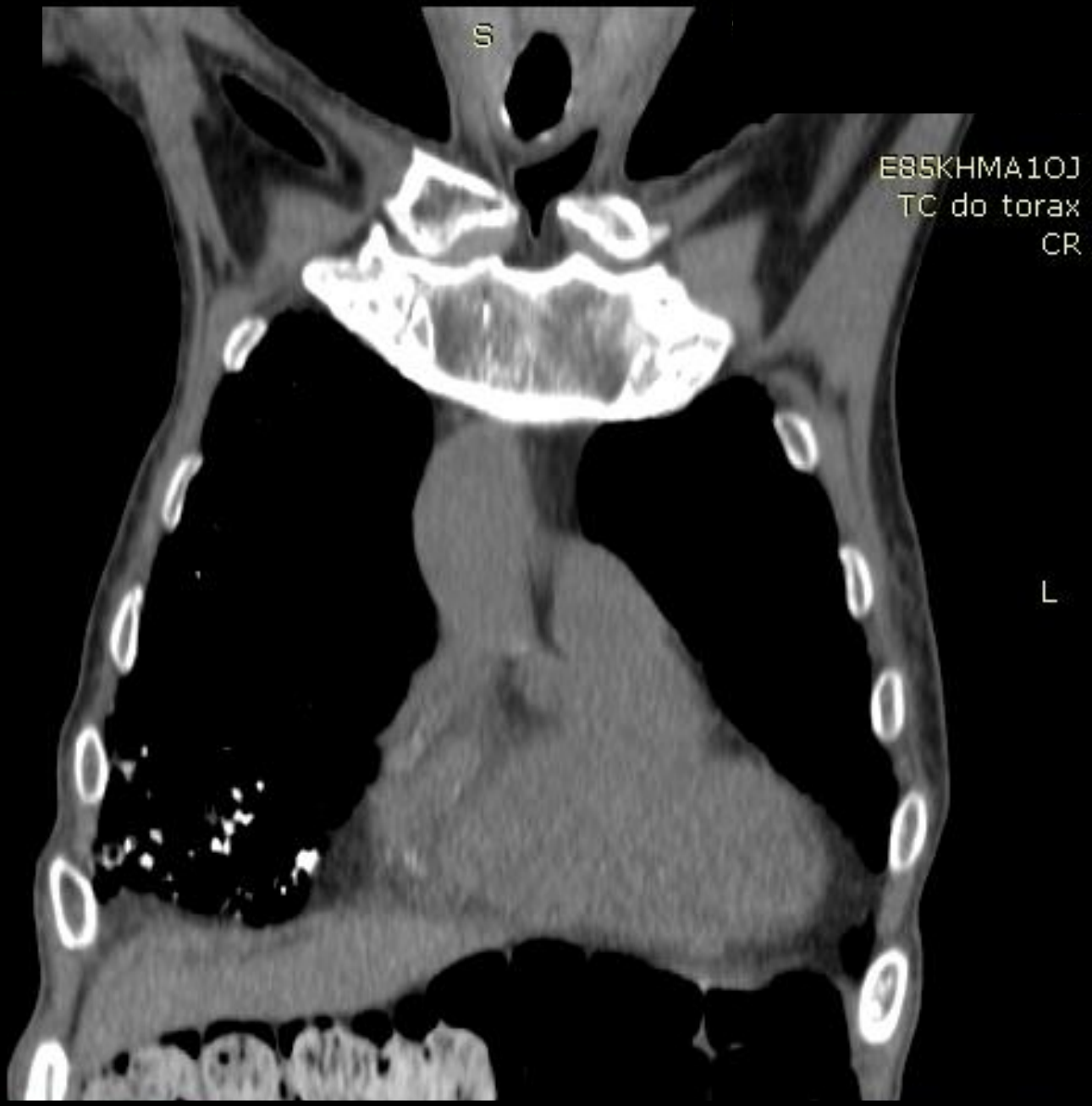
S
E85KHMA1OJ
TC do torax
CR
L

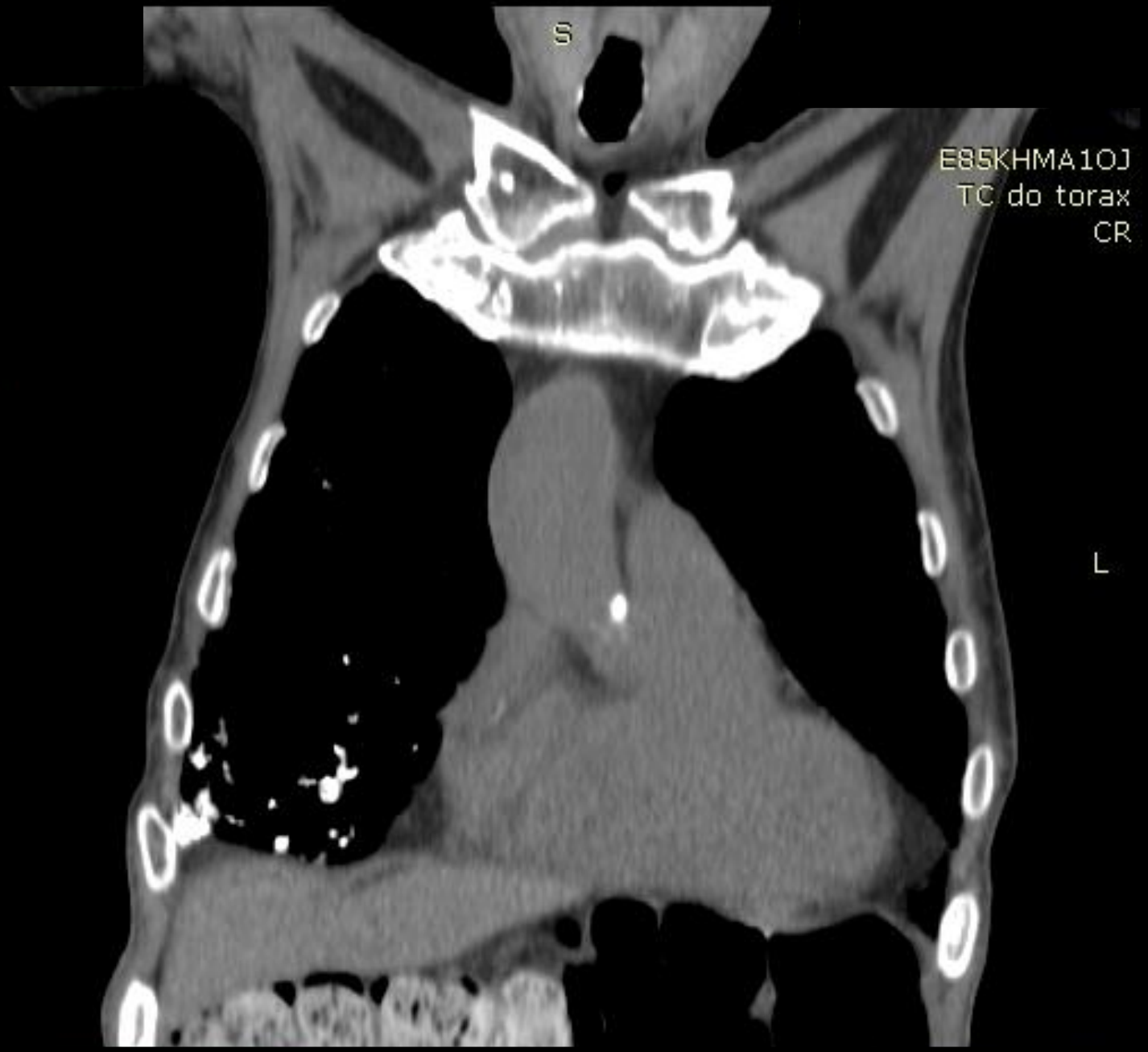
S
E85KHMA1OJ
TC do torax
CR
L

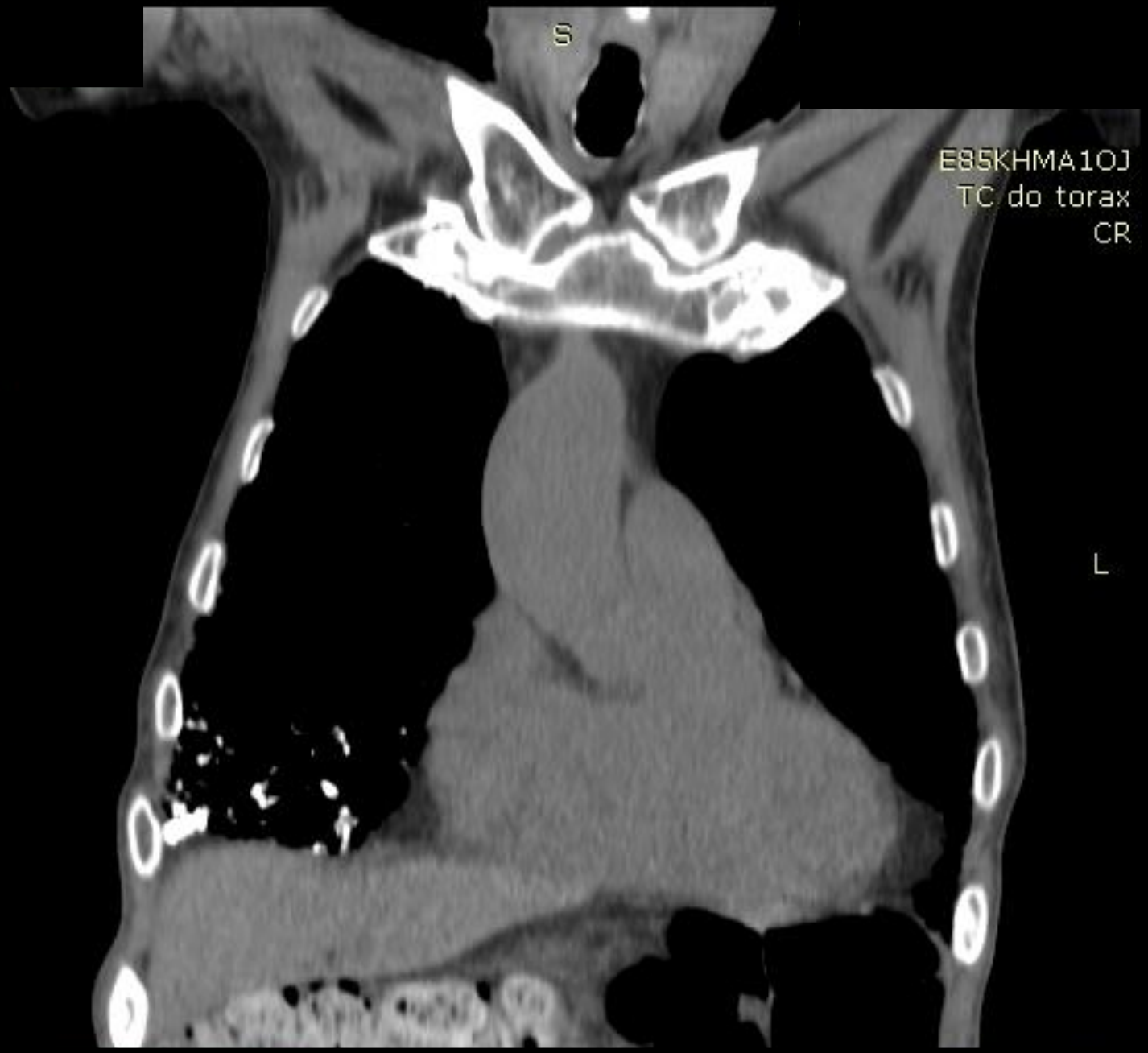
S
E85KHMA1OJ
TC do torax
CR
L

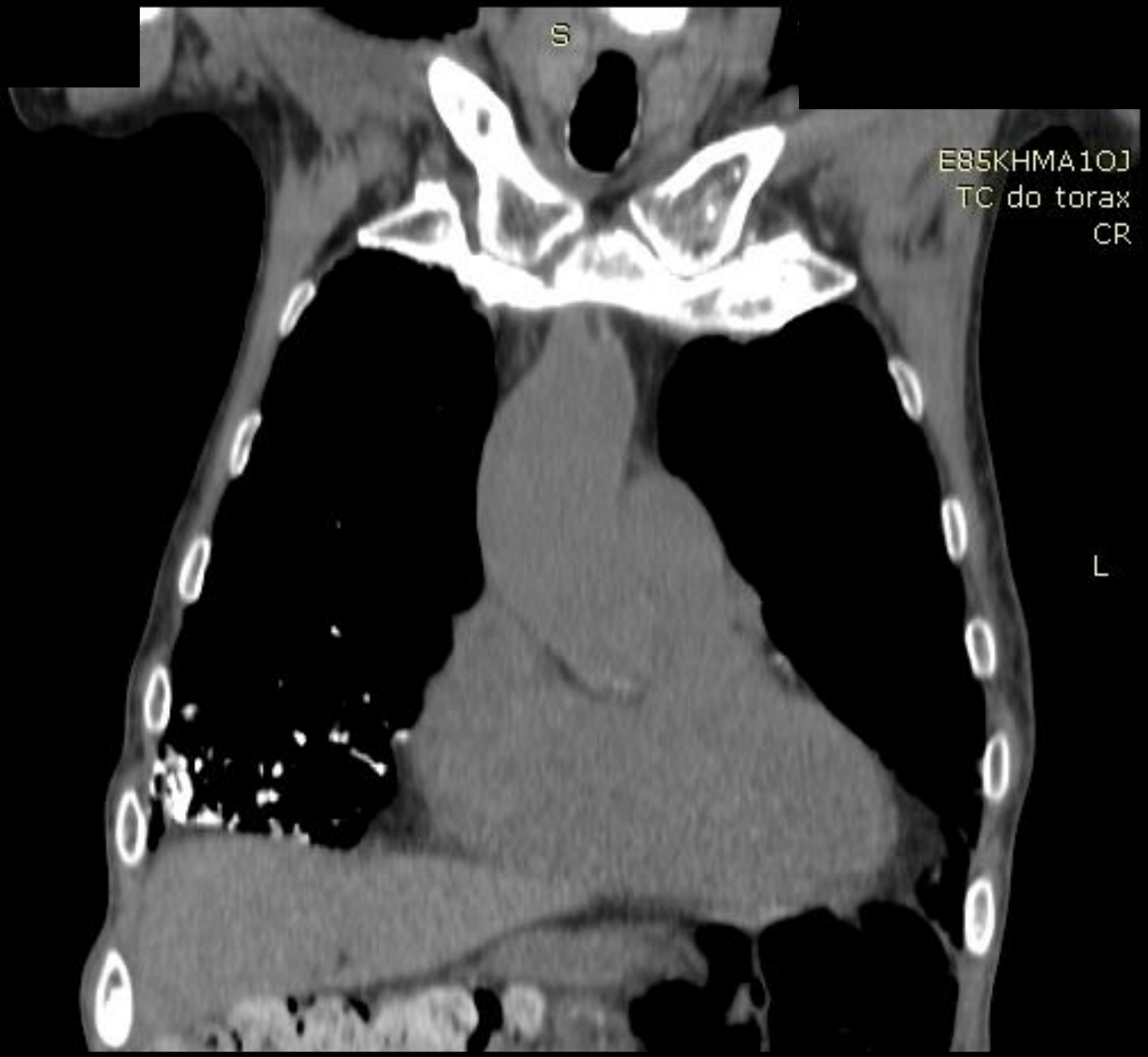
S
E85KHMA1OJ
TC do torax
CR
L

S
E85KHMA1OJ
TC do torax
CR
L

S
E85KHMA1OJ
TC do torax
CR
L

S
E85KHMA1O1
TC do torax
CR
L

S
E85KHMA1OJ
TC do torax
CR
L

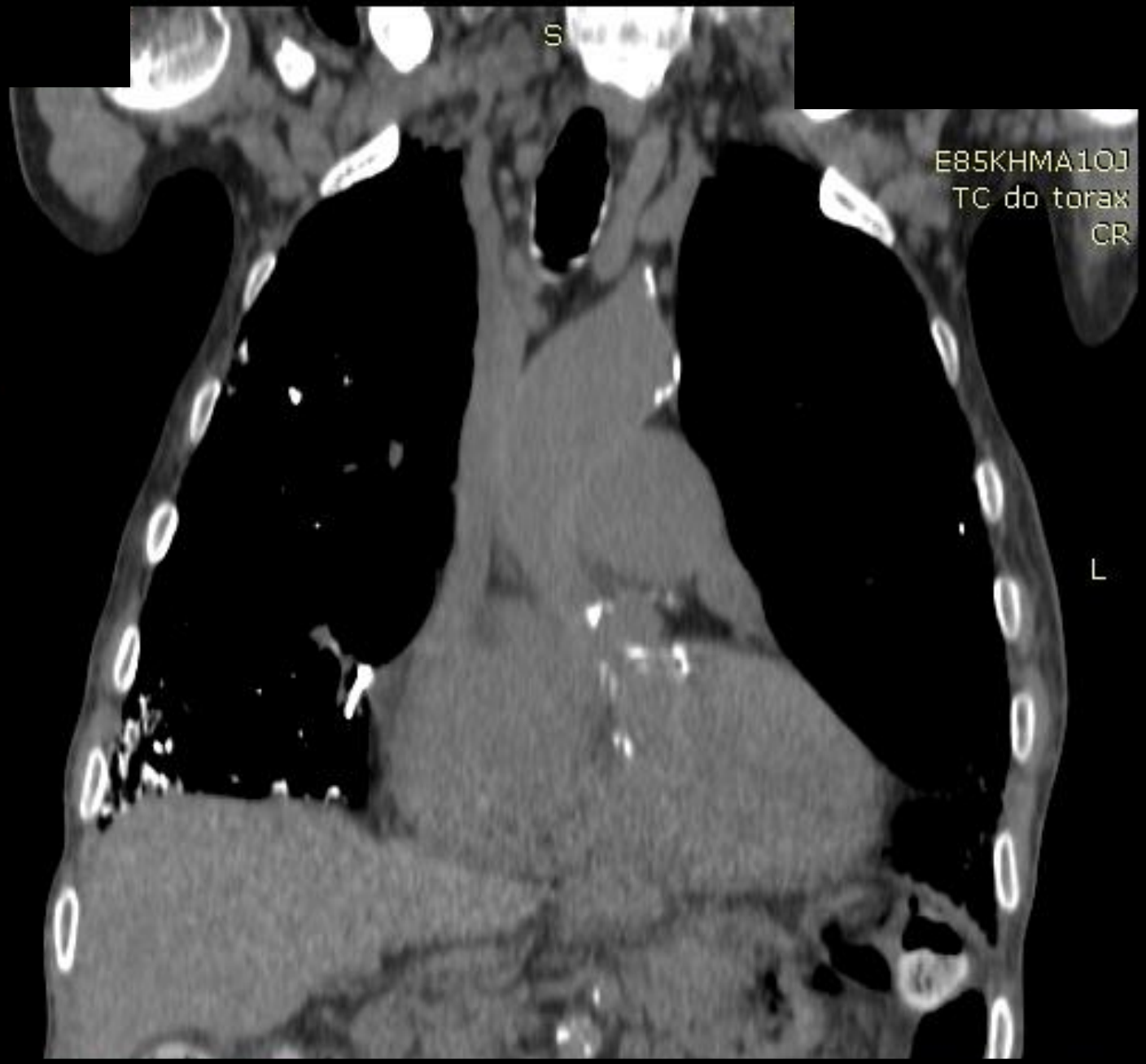
S
E85KHMA1OJ
TC do torax
CR
L

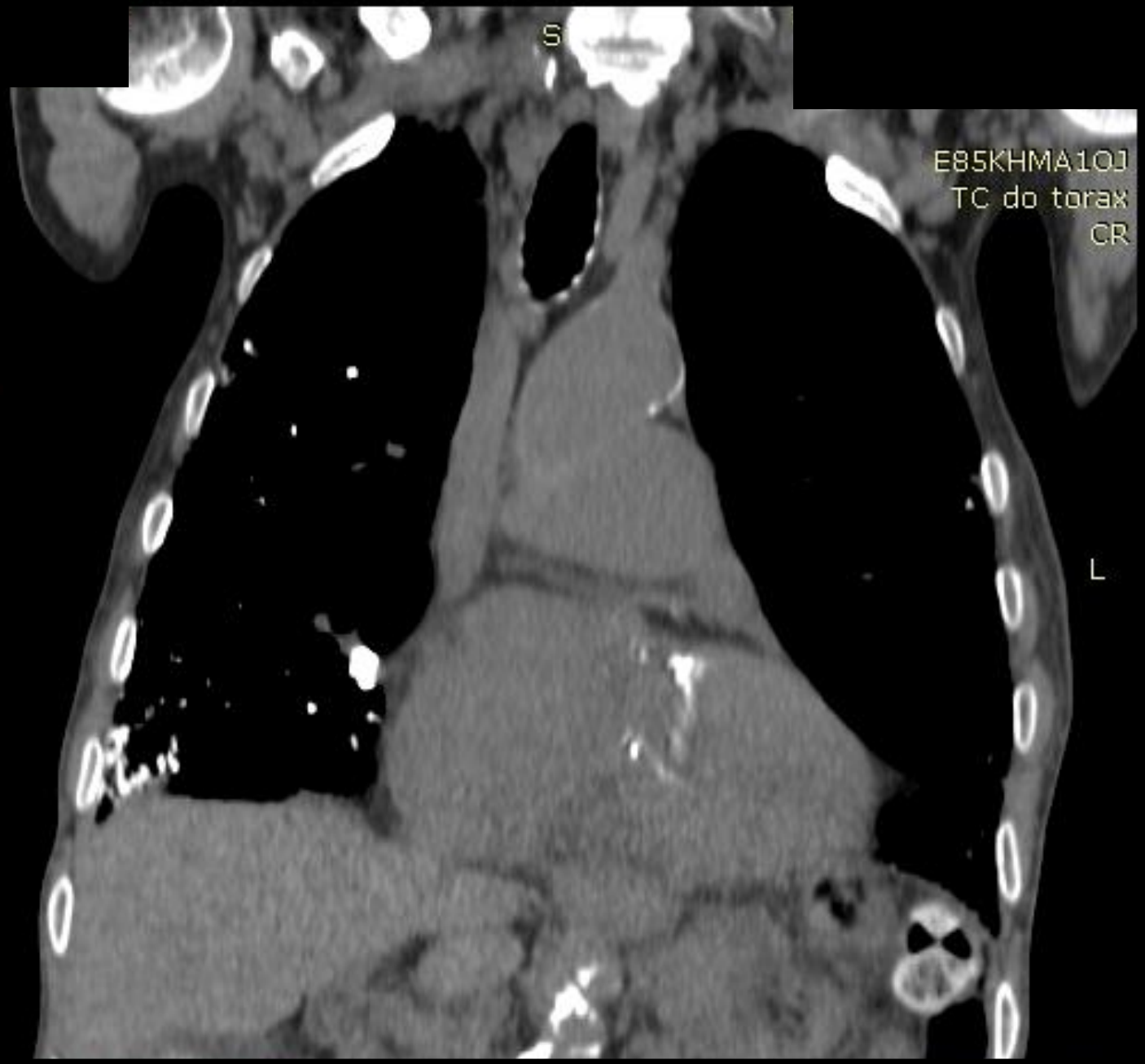
S
E85KHMA1OJ
TC do torax
CR
L

S
E85KHMA1OJ
TC do torax
CR
L

S
E85KHMA1OJ
TC do torax
CR
L

S
E85KHMA1OJ
TC do torax
CR
L

S
E85KHMA101
TC do torax
CR
L

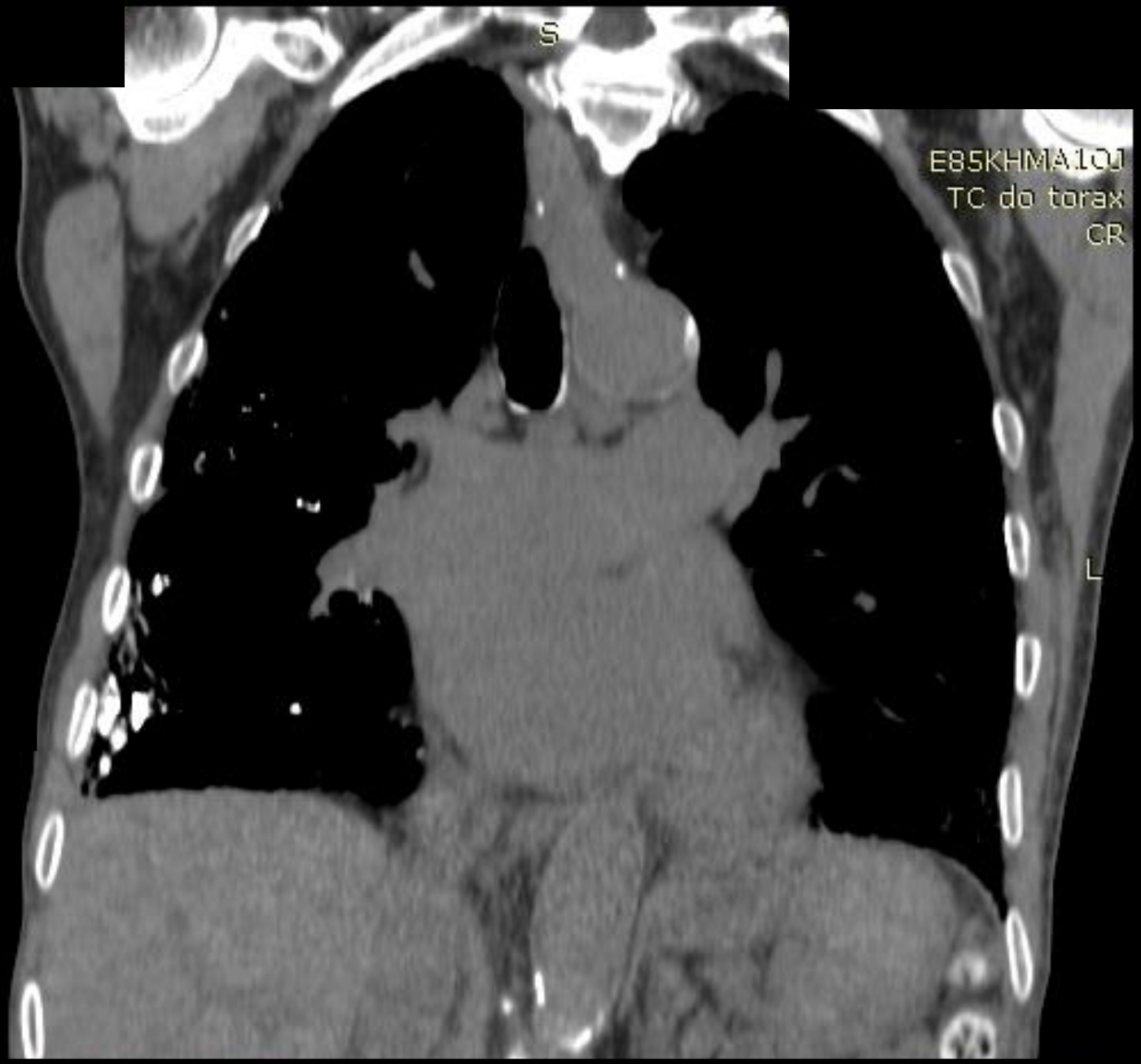
S
E85KHMA1OJ
TC do torax
CR
L

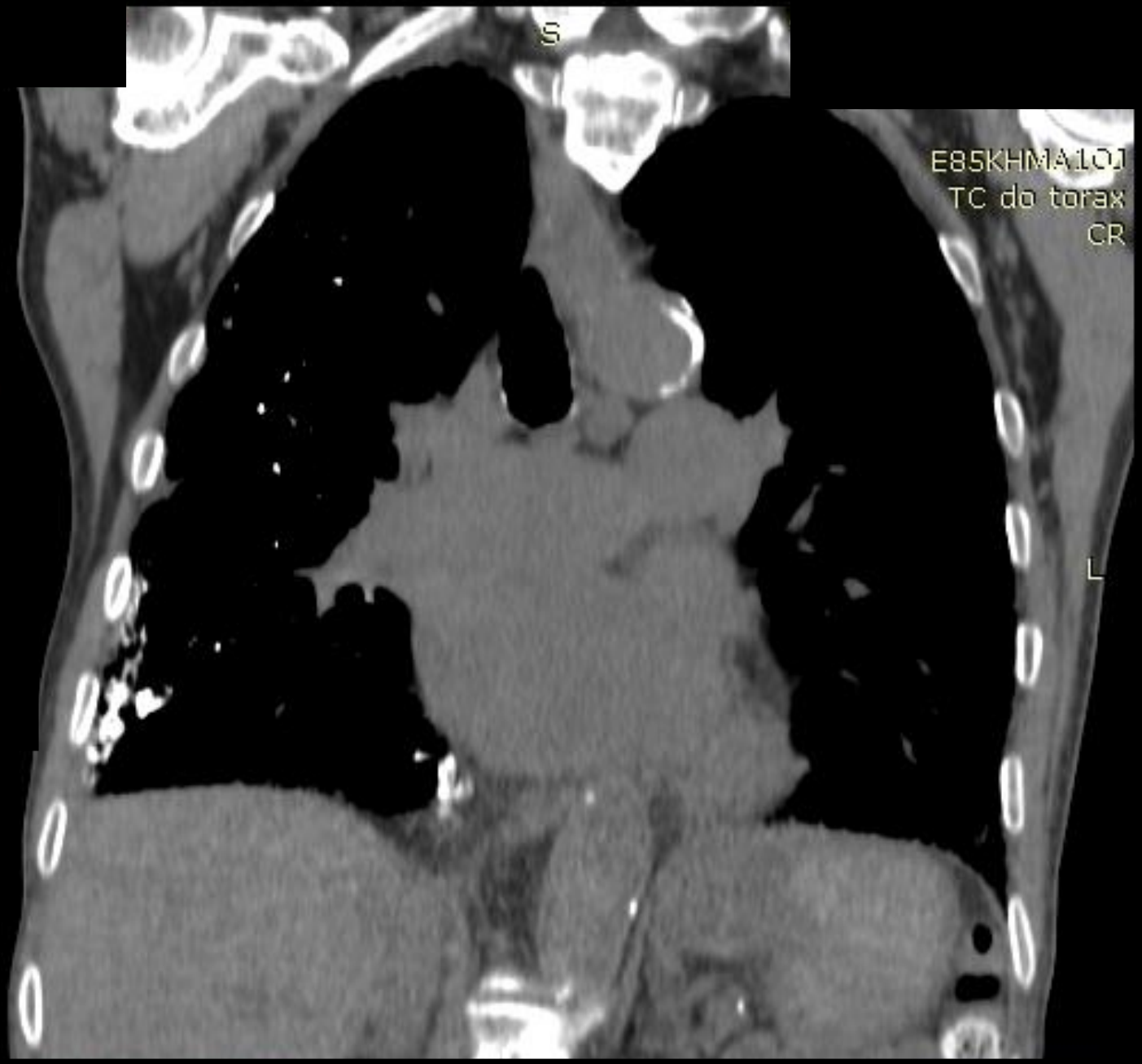
S
E85KHMA1O1
TC do torax
CR
L

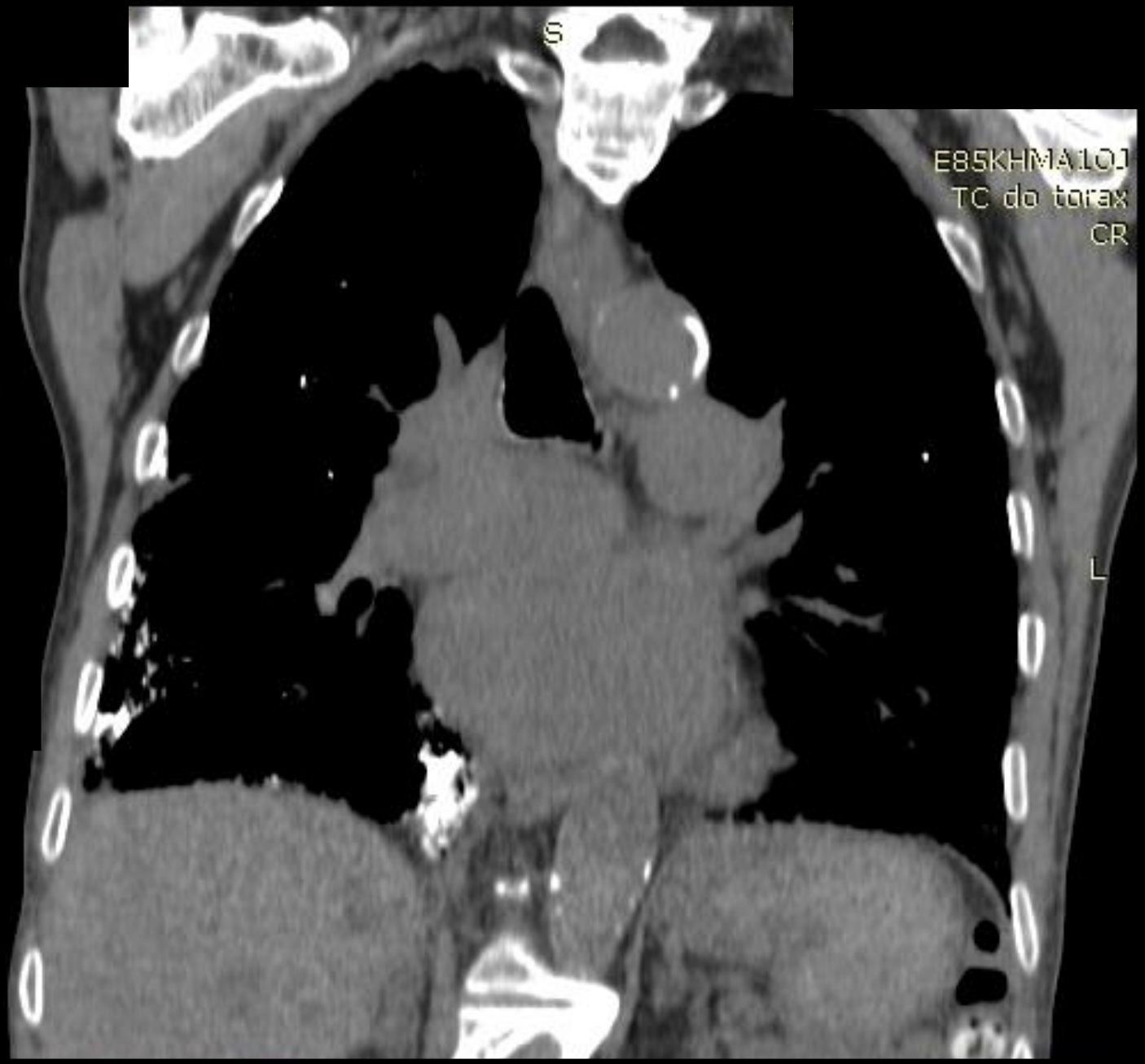
S
E85KHMA101
TC do torax
CR
L

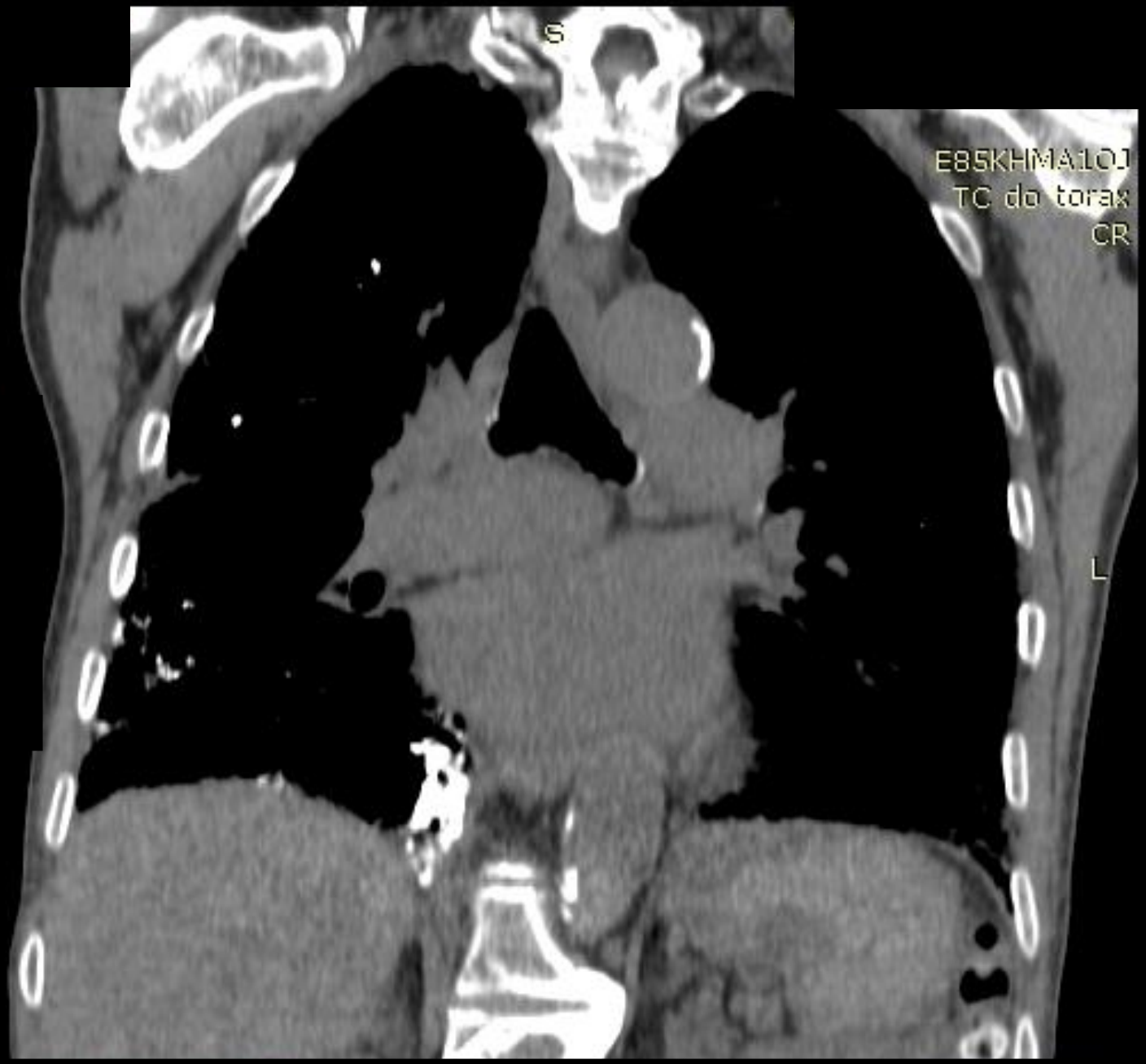
S
E85KHMA1OJ
TC do torax
CR
L

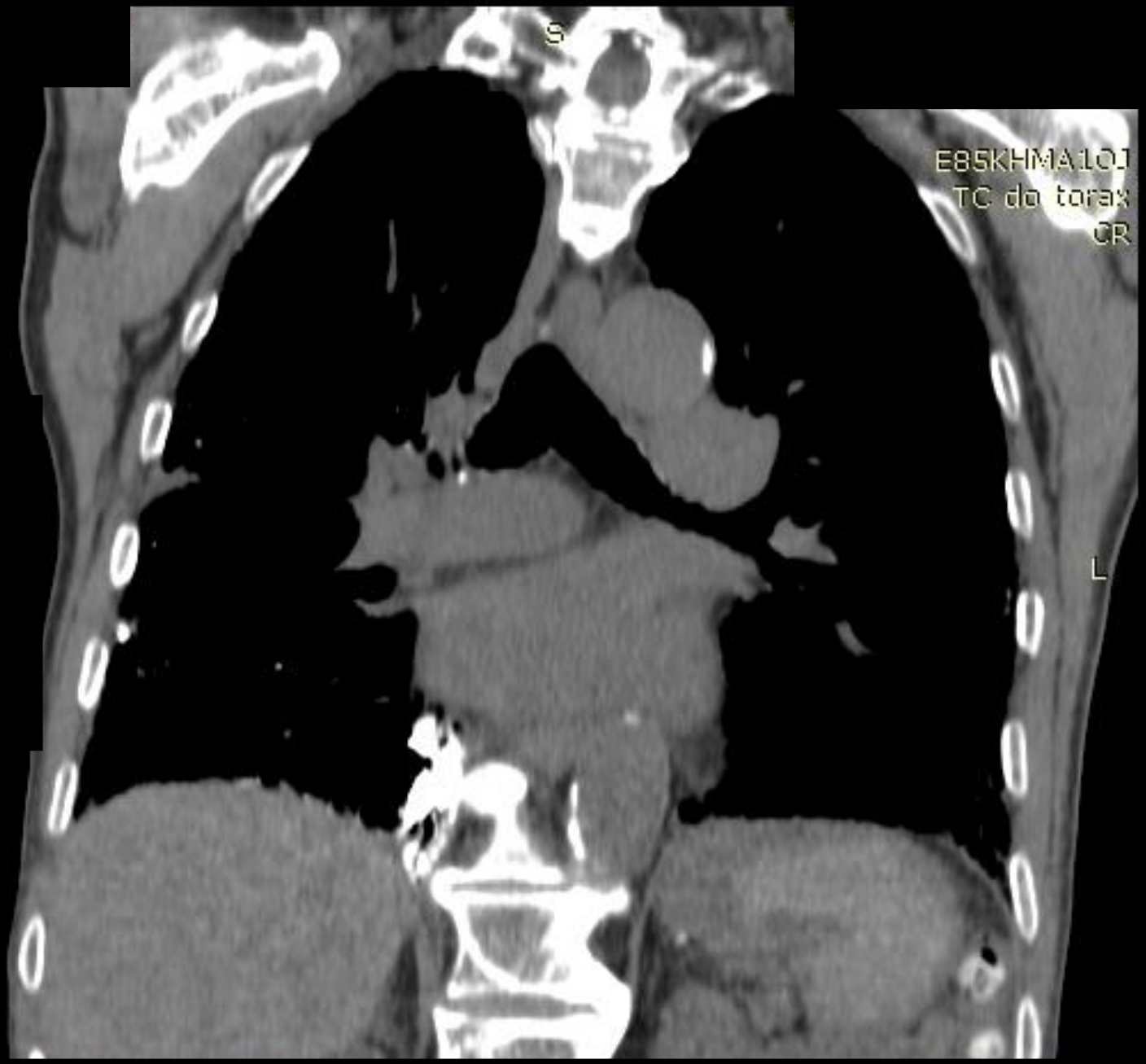
S
E85KHMA101
TC do torax
CR
L

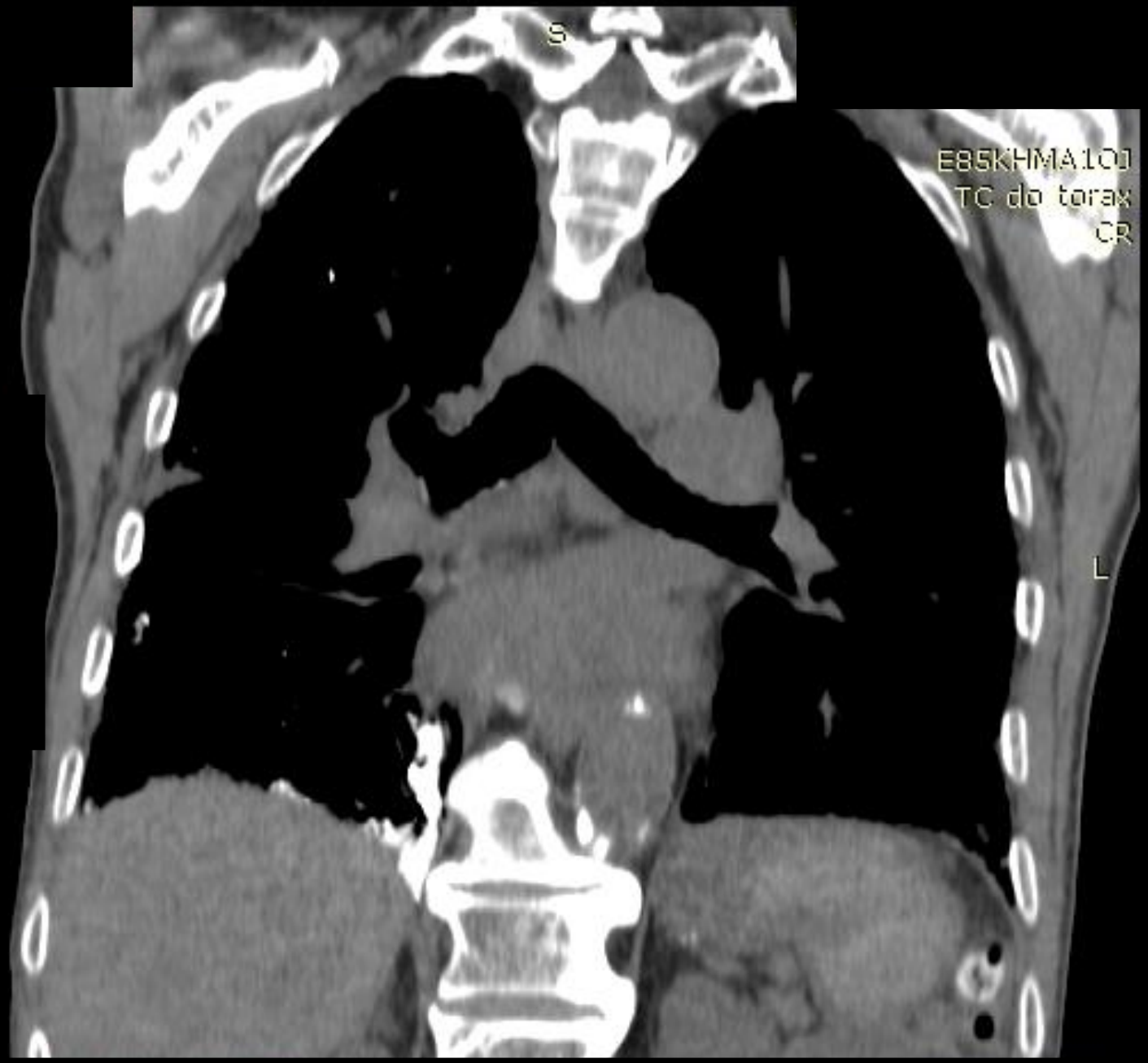
S
E85KHMA101
TC do torax
CR
L

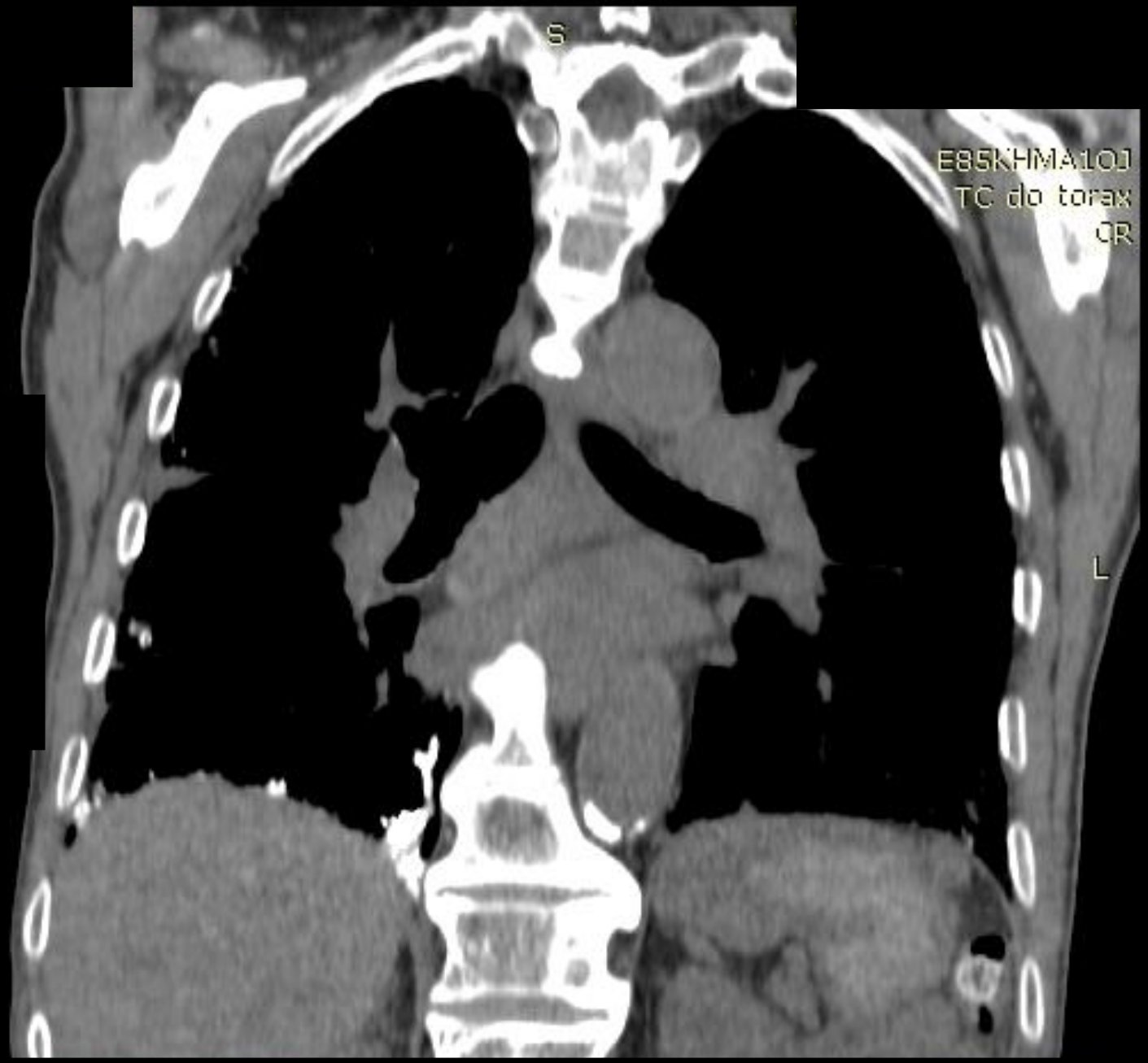
S
E85KHMA101
TC do torax
CR
L

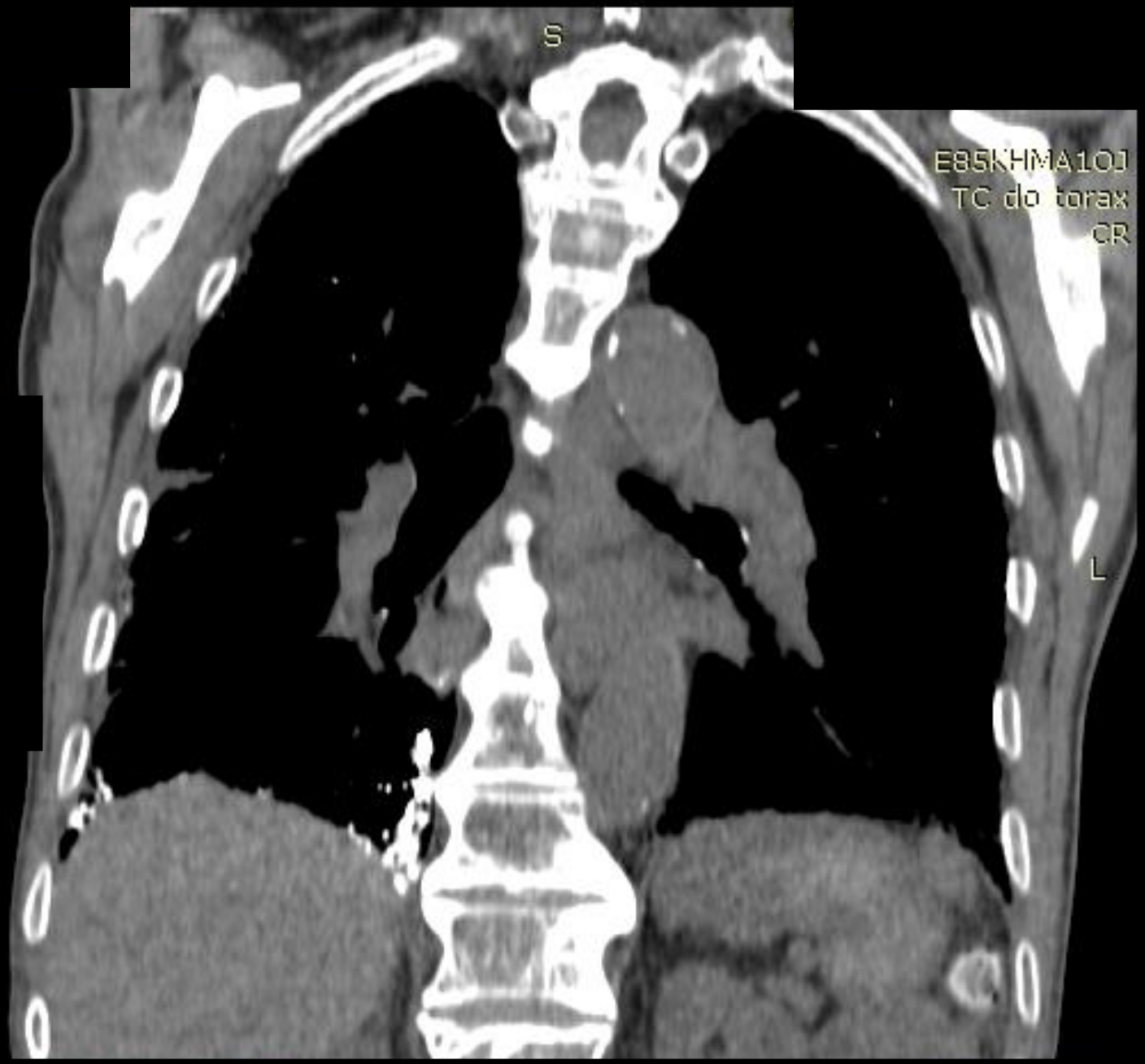
S
E85KHMA101
TC do torax
CR
L

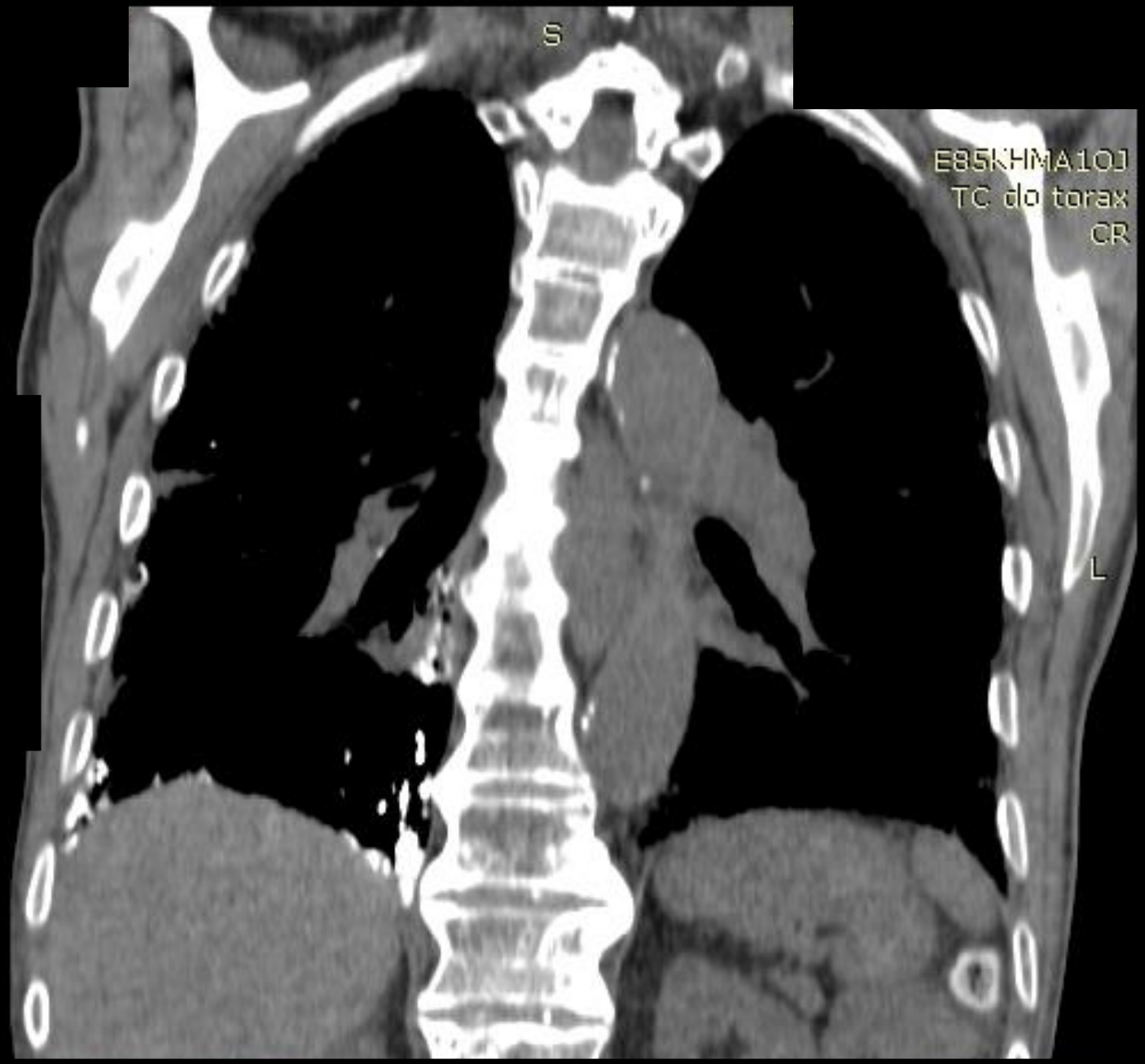
S
E85KHMA101
TC do torax
CR
L

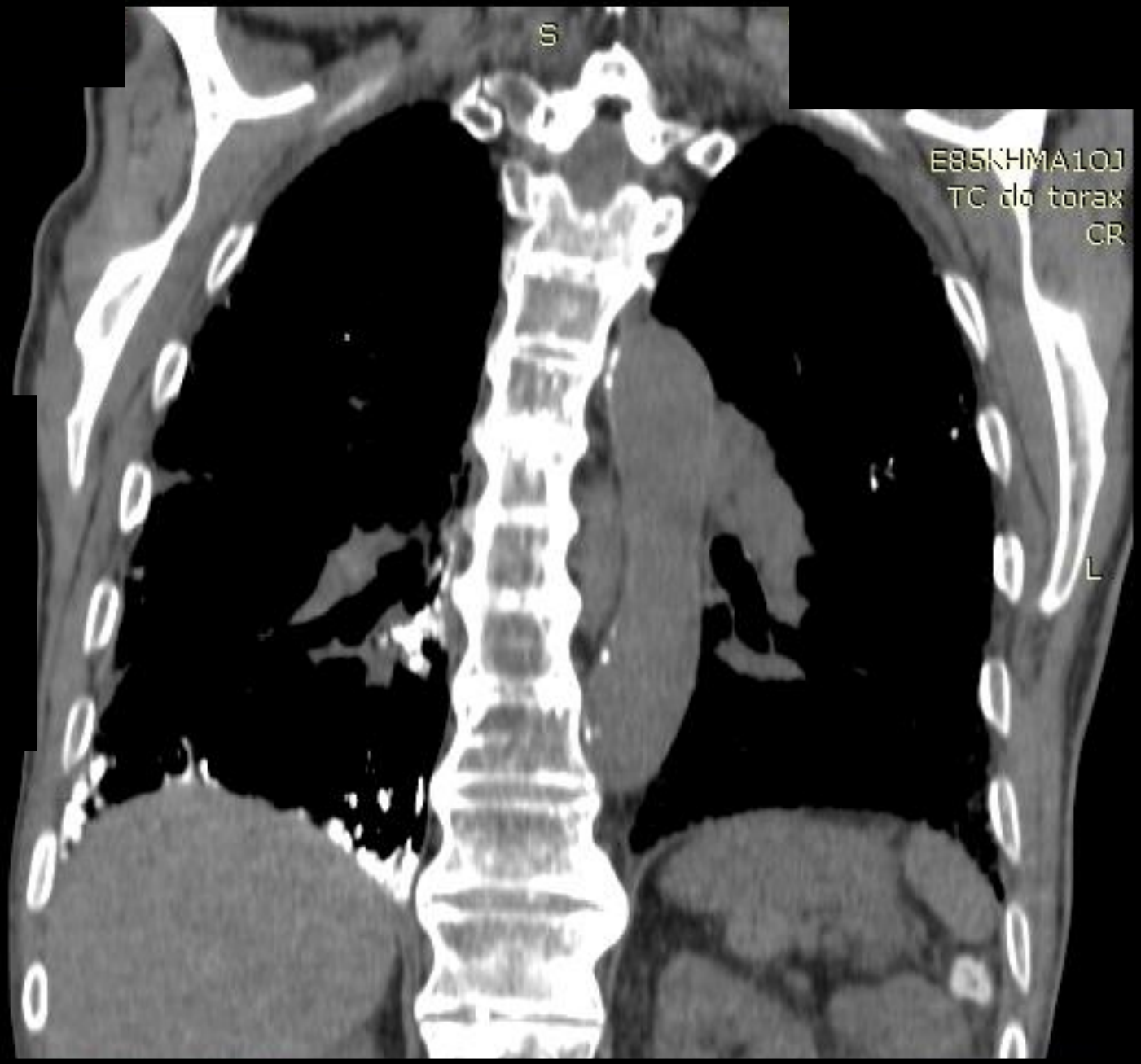
S
E85KHMA101
TC do torax
CR
L

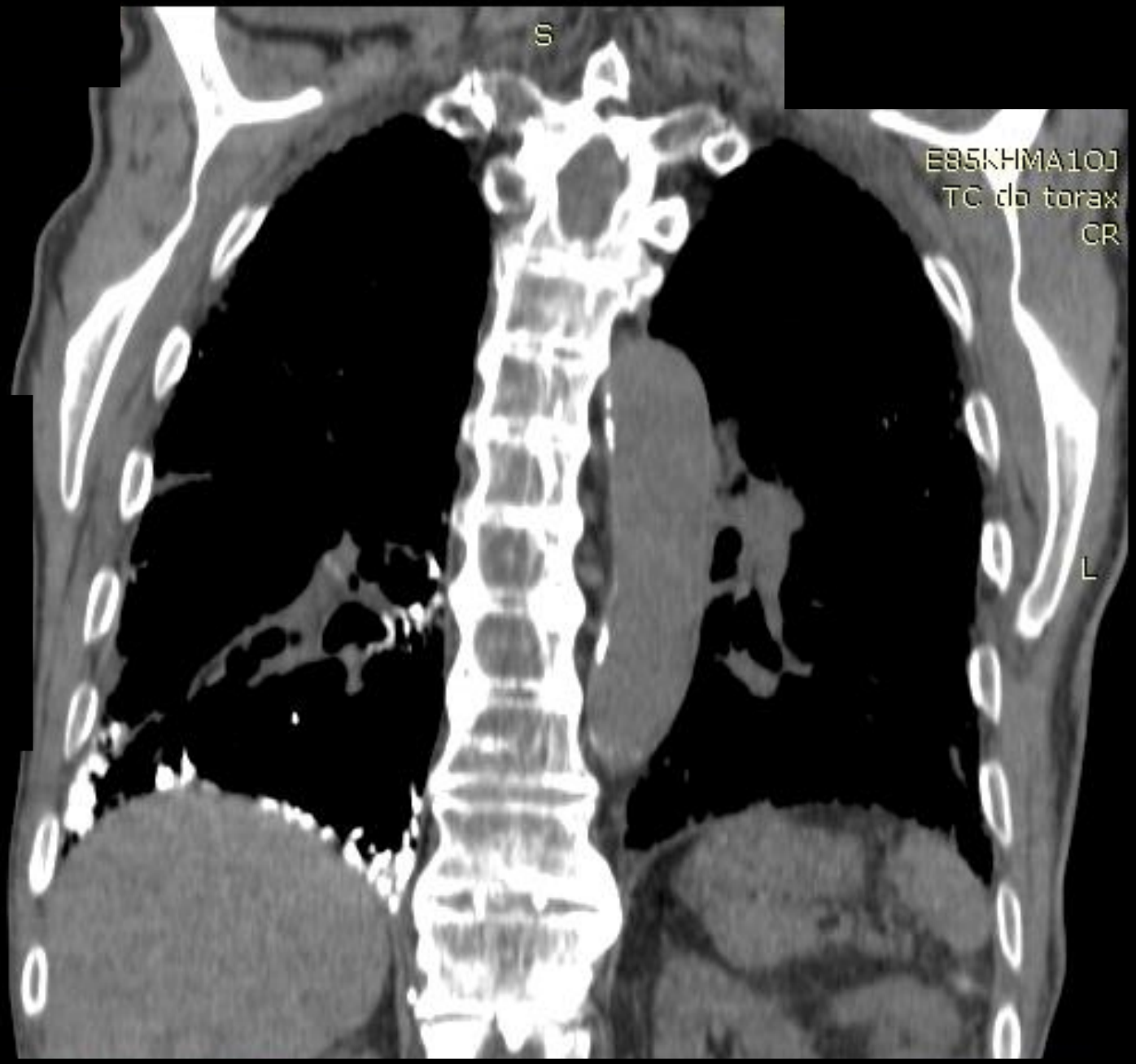
S
E85KHMA1OJ
TC do torax
CR
L

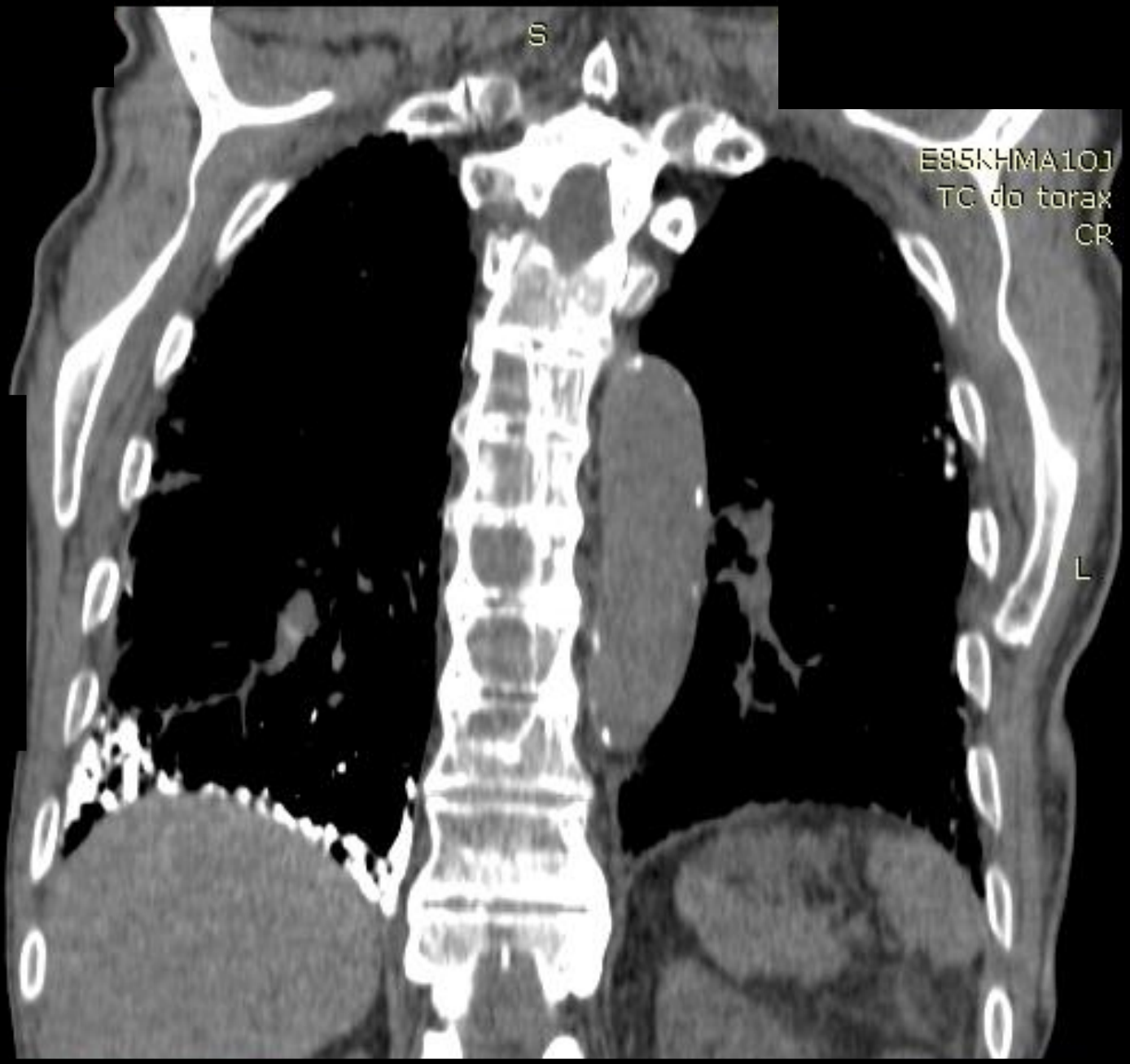
S
E85KHMA101
TC do torax
CR
L

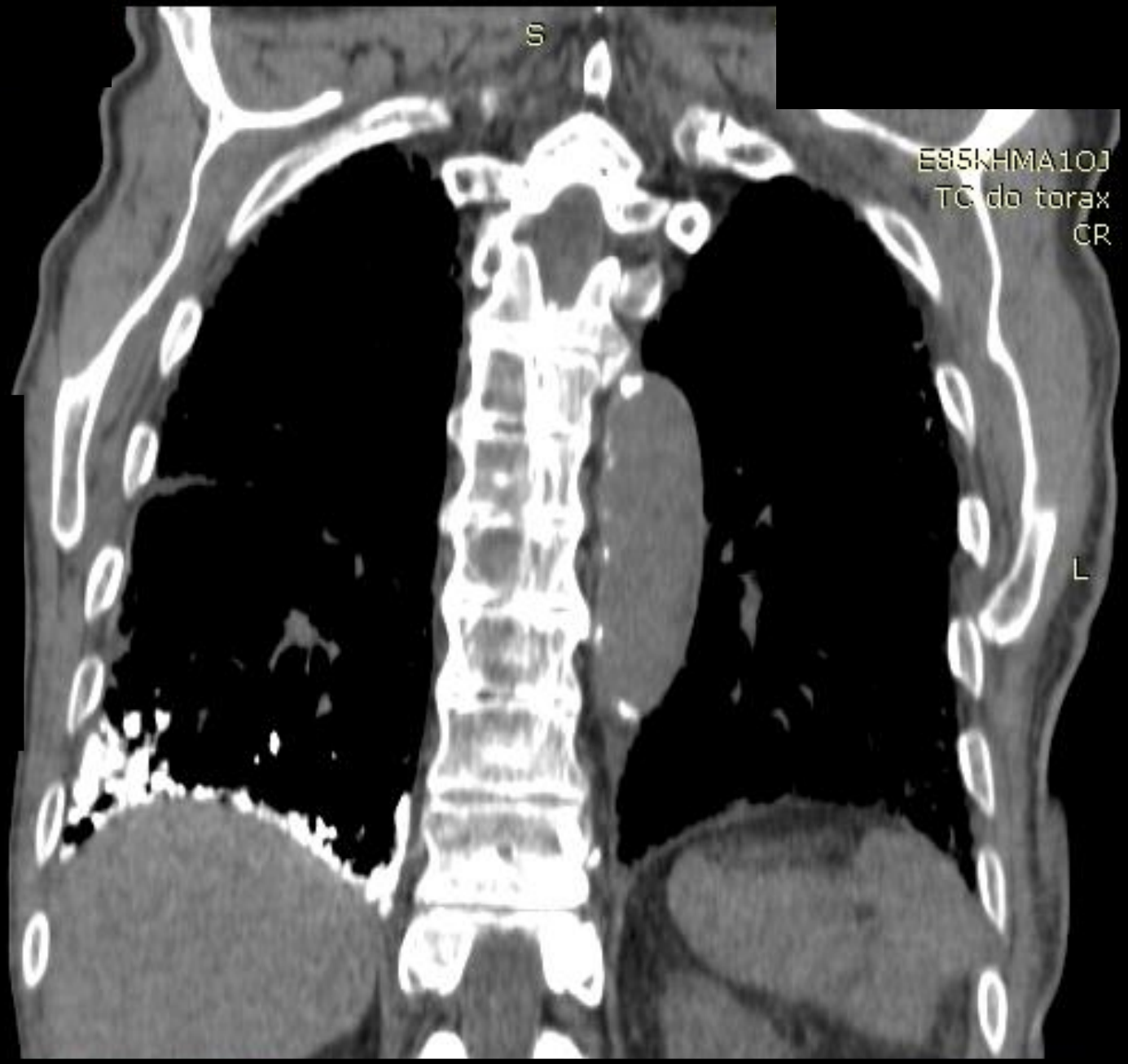
S
E85KHMA1OJ
TC do torax
CR
L

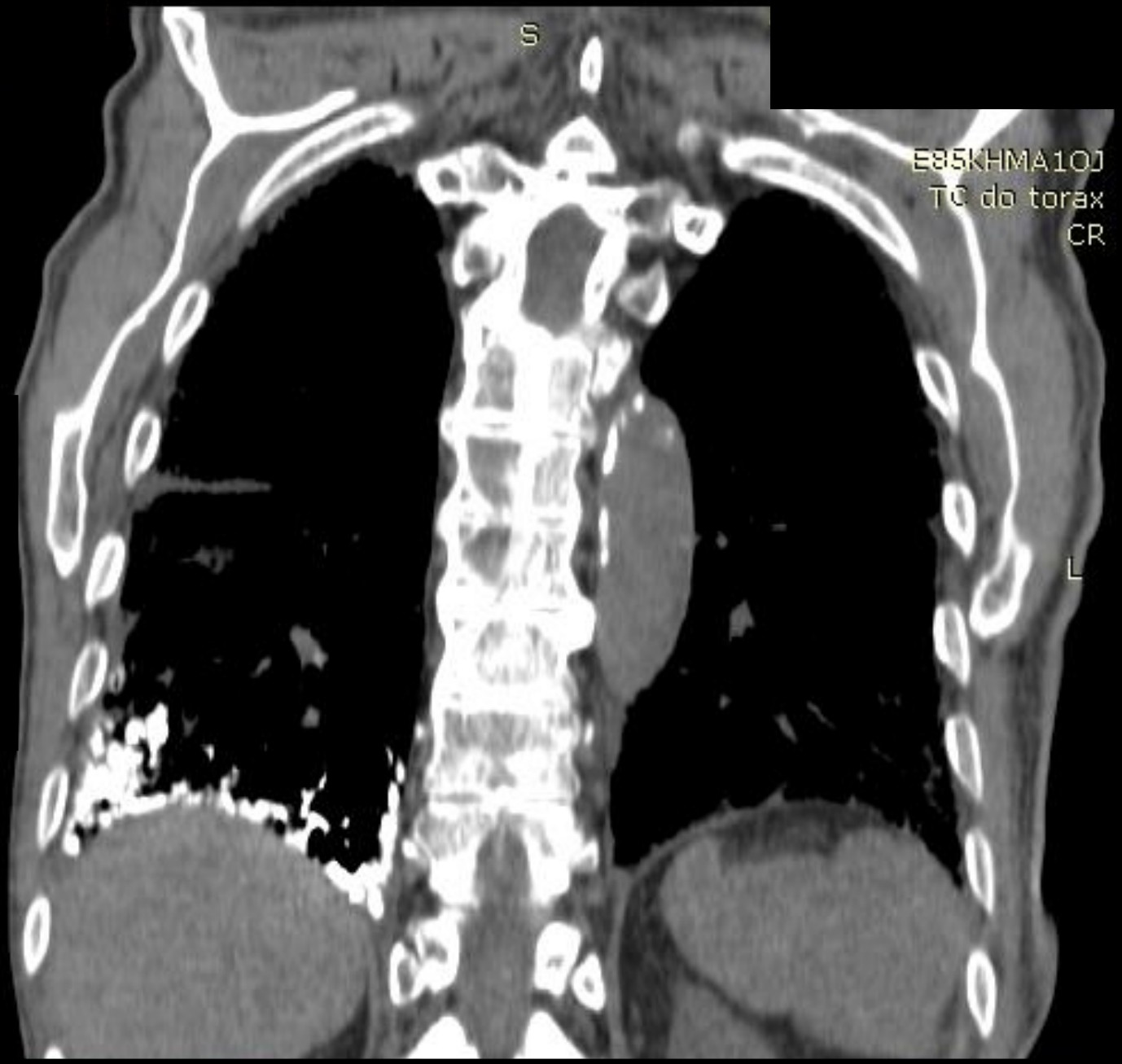
S
E85KHMA1OJ
TC do torax
CR
L

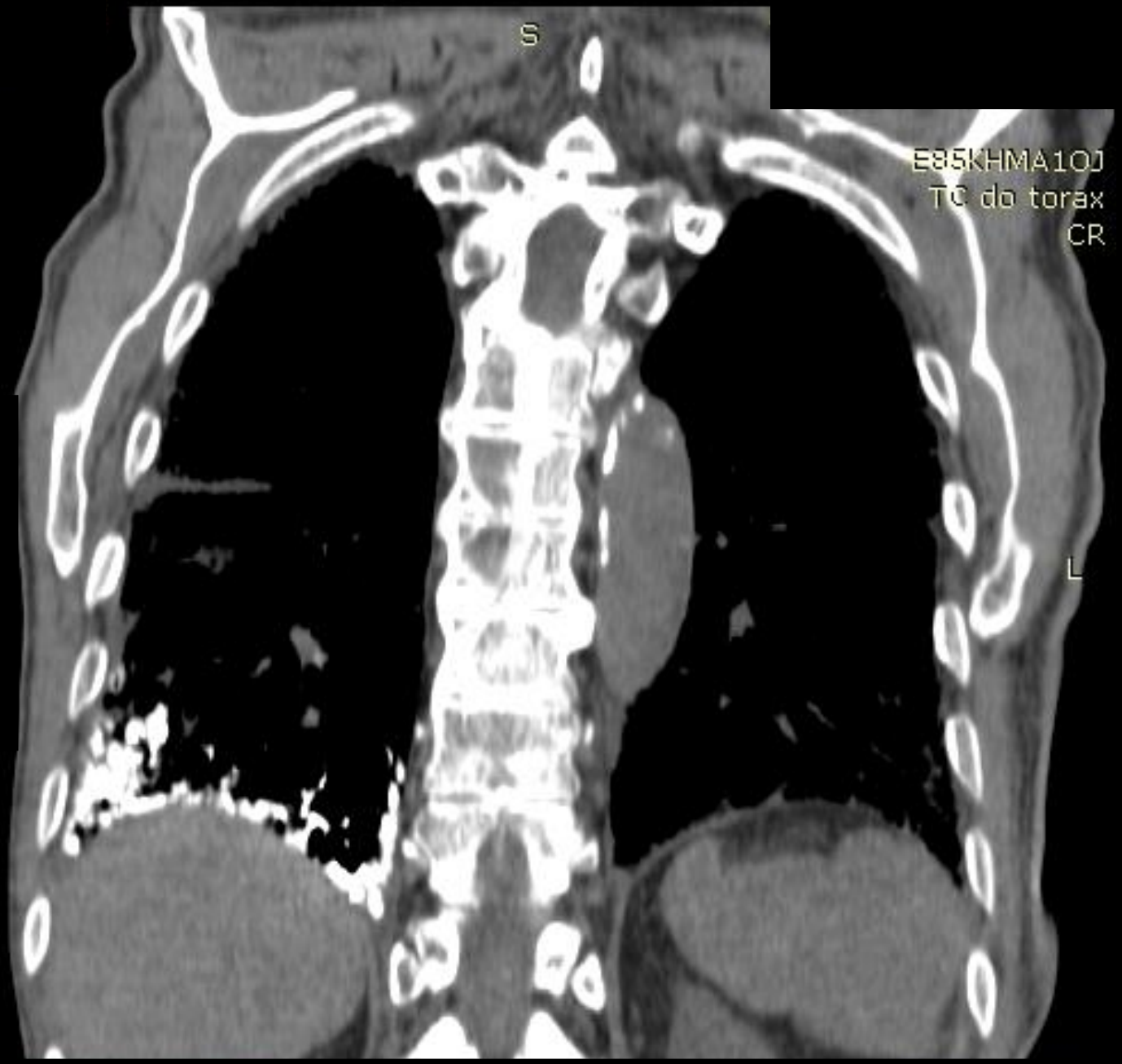
S
E85KHMA1OJ
TC do torax
CR
L

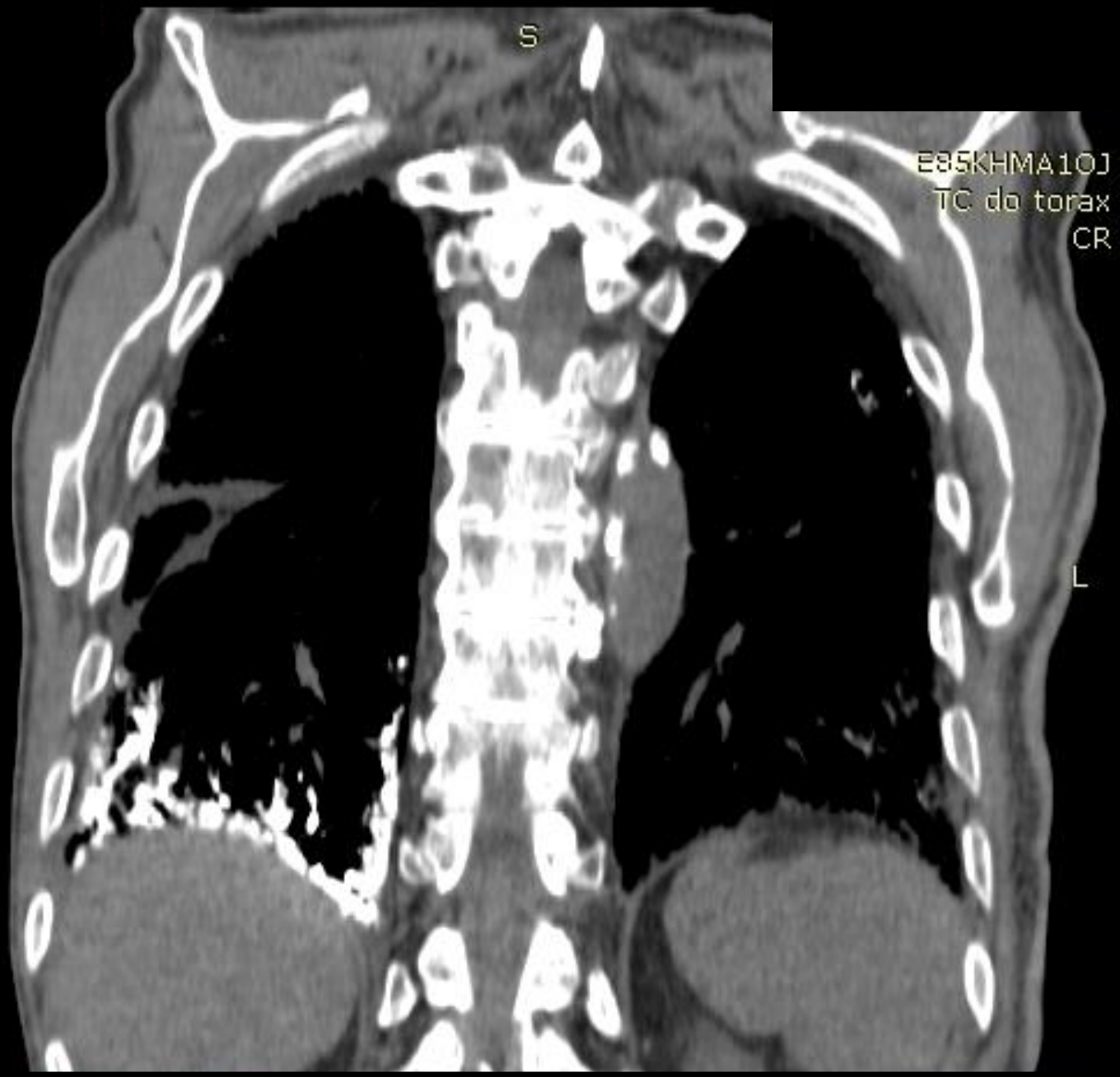
S
E85KHMA1OJ
TC do torax
CR
L

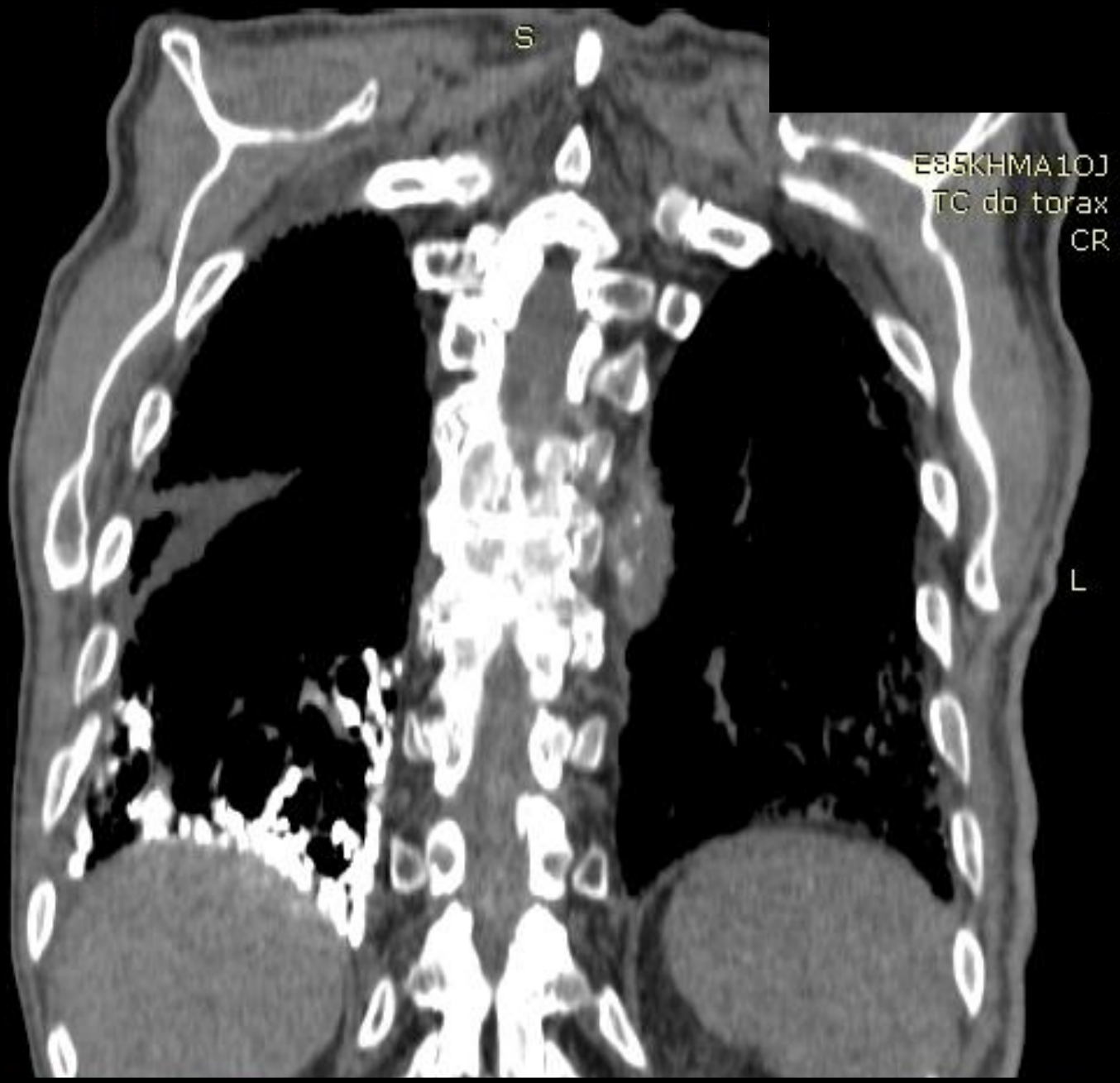
S
E85KHMA1OJ
TC do torax
CR
L

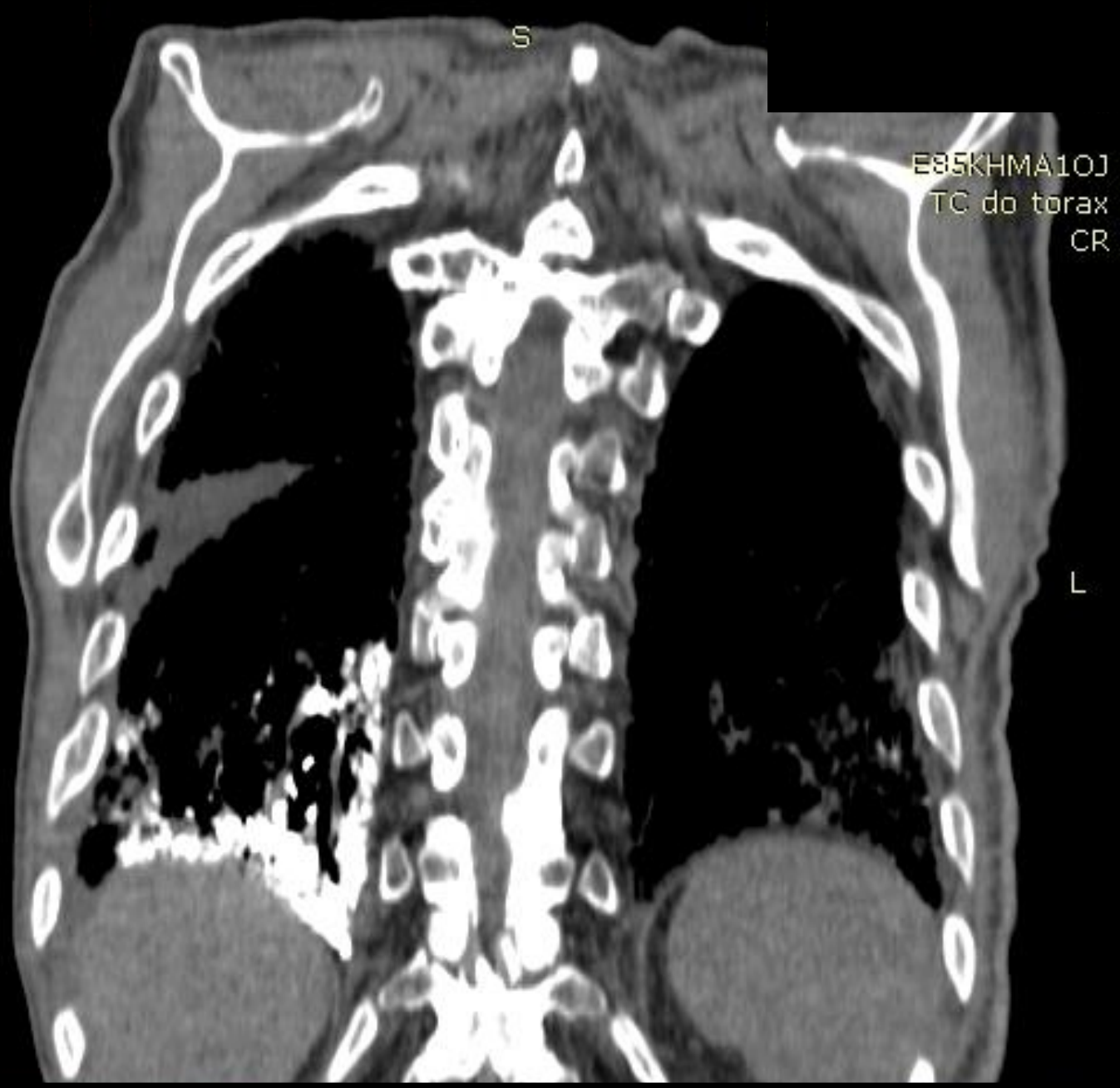
S
E85KHMA1OJ
TC do torax
CR
L

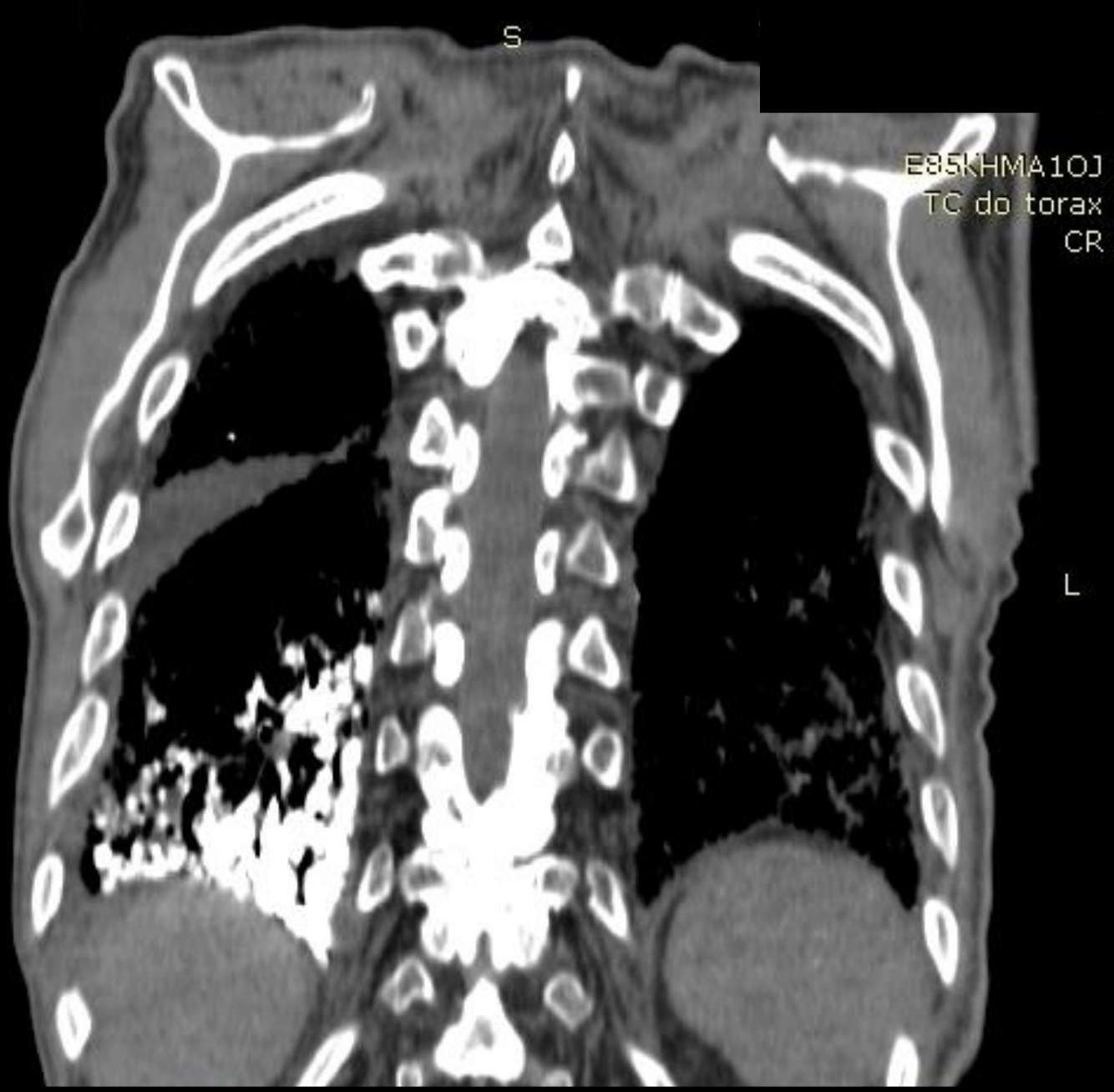
S
E85KHMA1OJ
TC do torax
CR
L

S
E85KHMA1OJ
TC do torax
CR
L

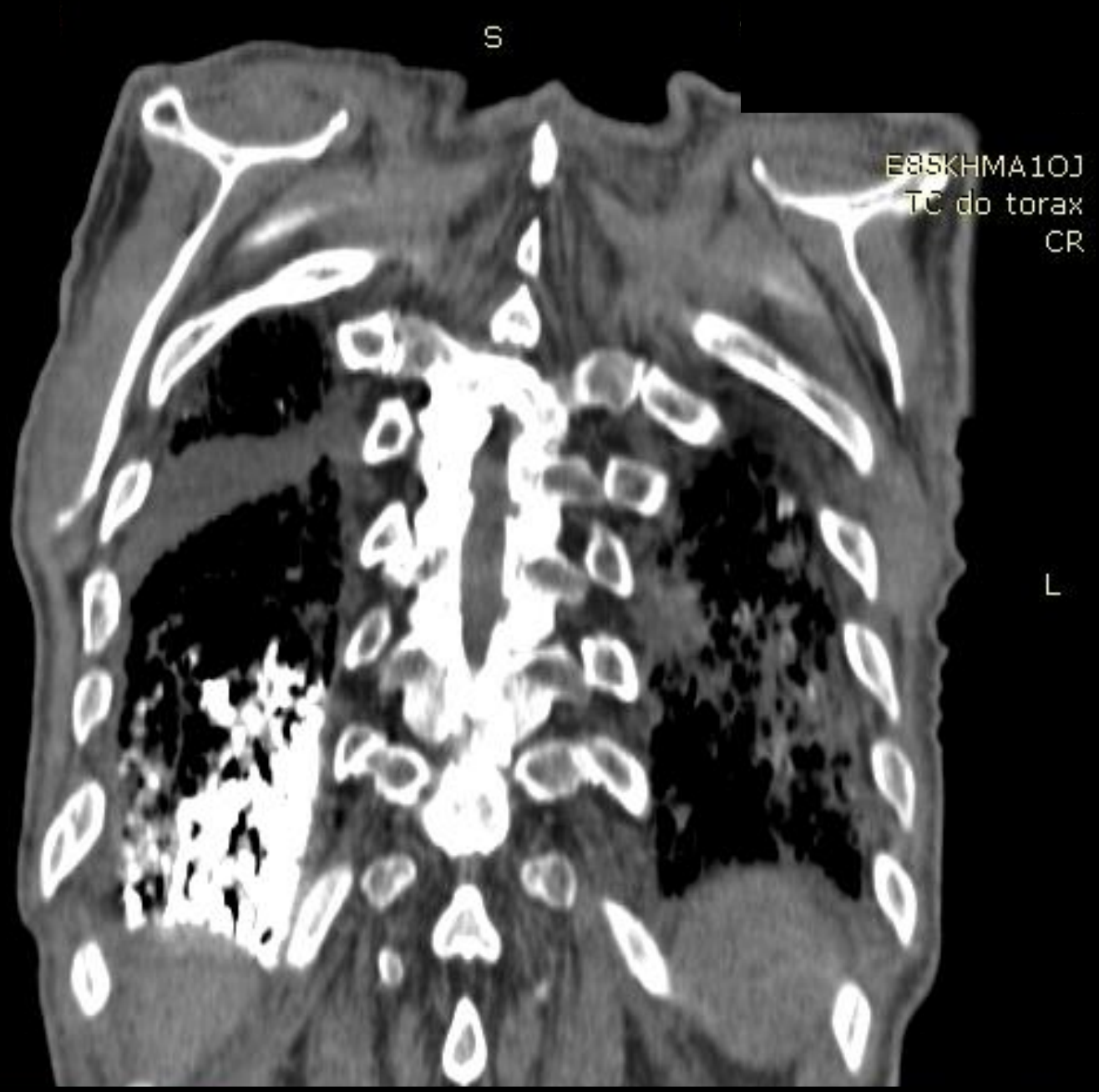
S
E85KHMA1OJ
TC do torax
CR
L

S
E85KHMA1OJ
TC do torax
CR
L

S
E85KHMA1OJ
TC do torax
CR
L

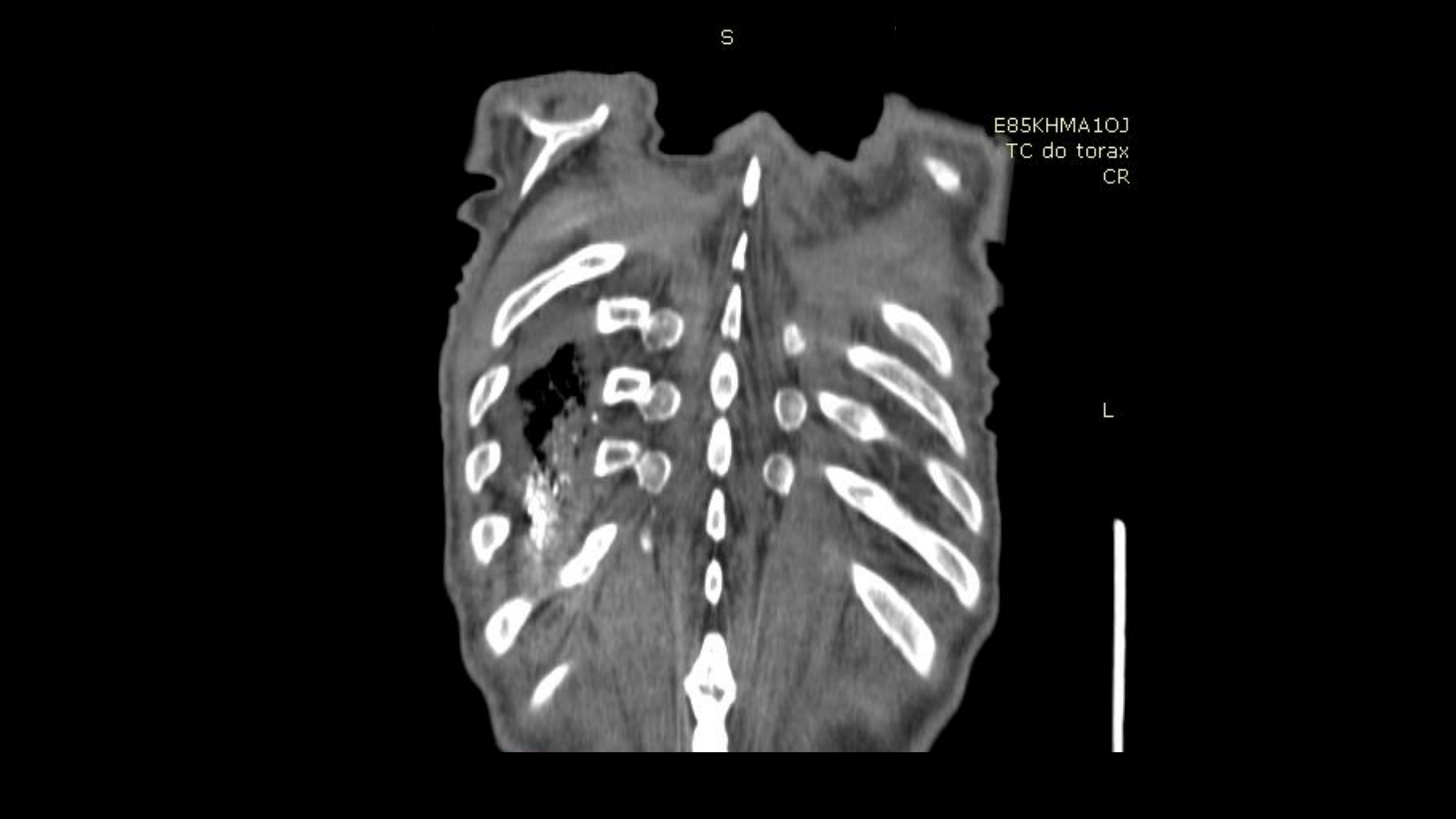
S
E85KHMA1OJ
TC do torax
CR
L

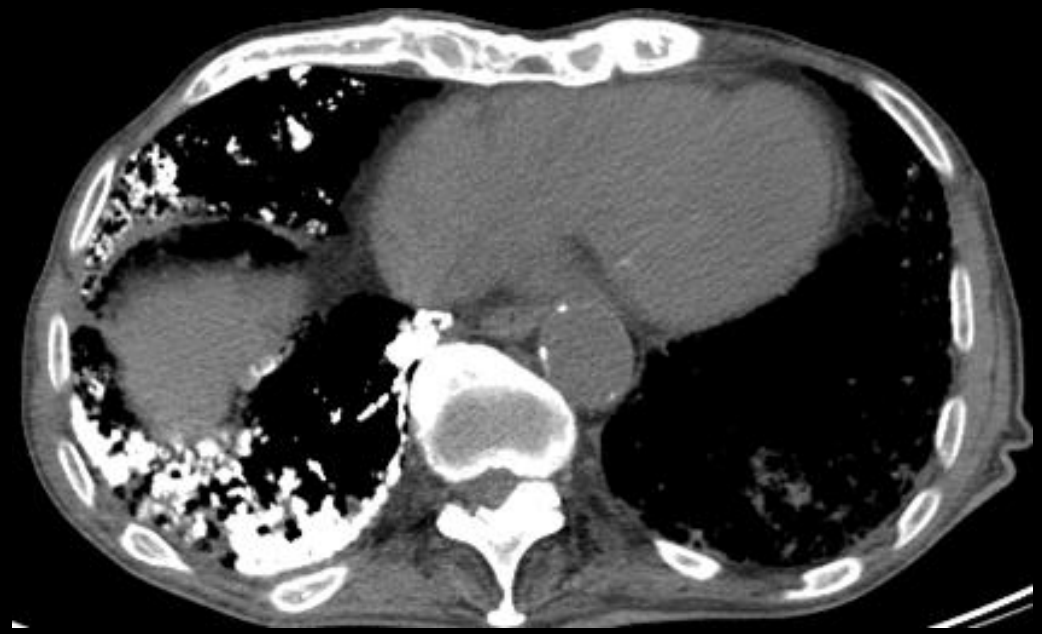

Descrição

Destaca-se a presença de microcalcificações arredondadas bilaterais, mais exuberantes no lobo inferior direito

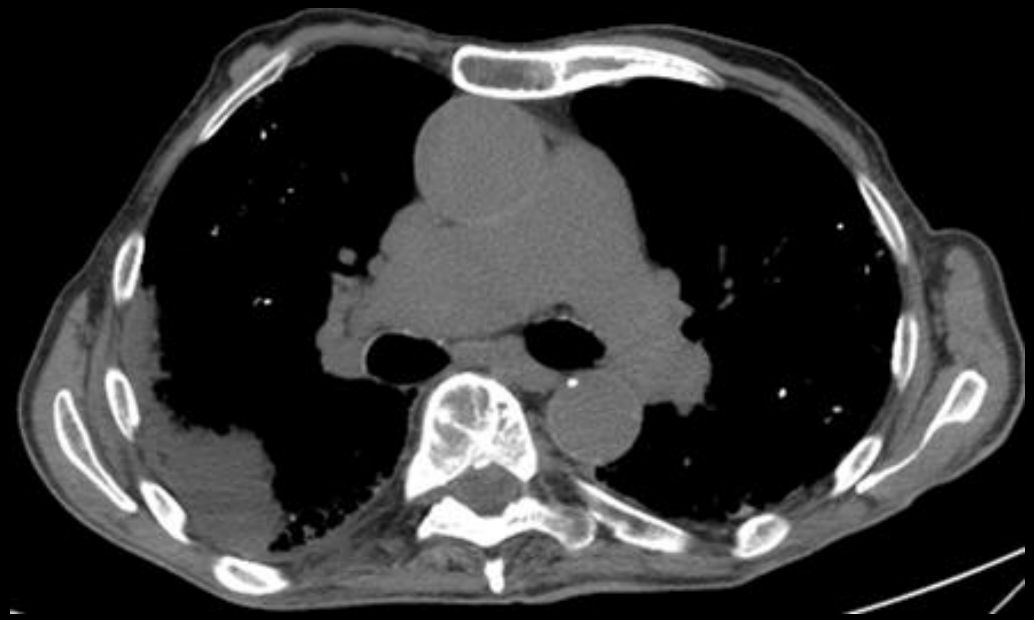

Descrição

Presença de bronquiectasias sub-pleurais

Há ainda derrame pleural organizado

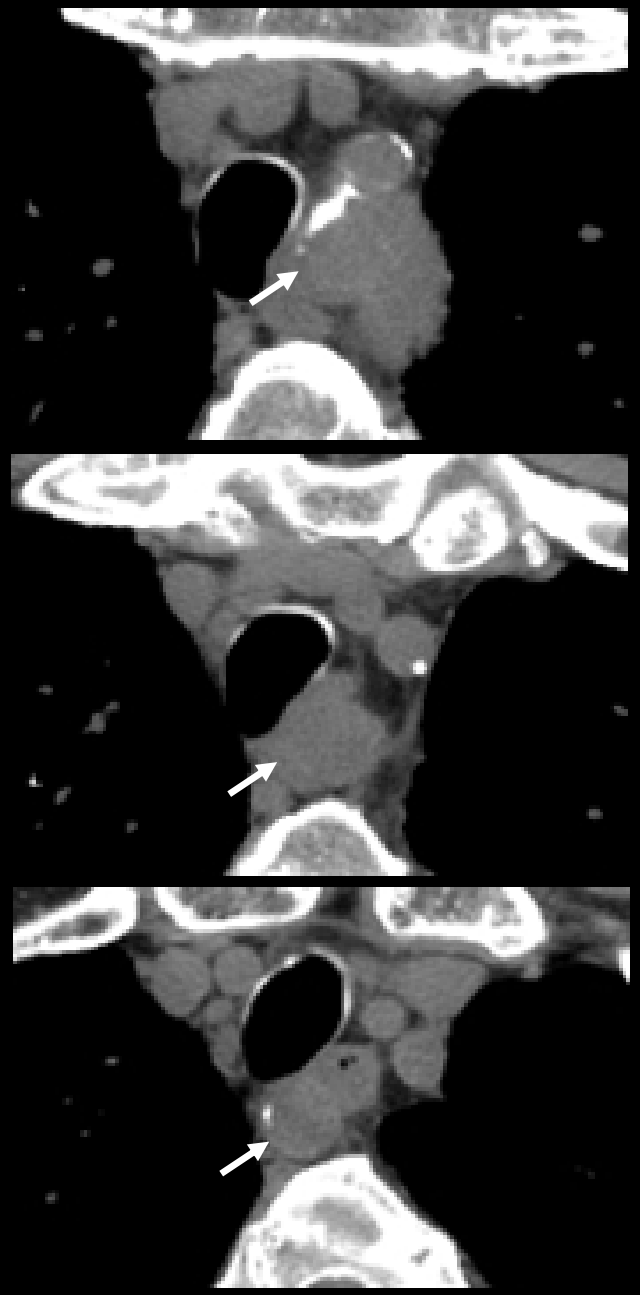

Descrição

Identifica-se artéria subclávia direita aberrante – variante do normal

Diagnóstico diferencial

?

Diagnóstico diferencial

- Microlitíase alveolar pulmonar
- Ossificação pulmonar difusa
- Silicose
- Calcificação metastática
- Metástases pulmonares com calcificações
- Infecciosas
  - TB
  - Varicela
- Amiloidose

Microlitíase Alveolar Pulmonar MAP

Presença de numerosas calcificações intra-alveolares dispersas **micrólitos**

Incidência

- 30-50 anos
- História familiar de MAP
  - Transmissão AR

Clínica

- Assintomático

Níveis séricos de cálcio e fósforo normais

Microlitíase Alveolar Pulmonar MAP

Imagiologia

Radiografia

- Calcificações finas – **“Tempestade de areia”**
  - **Andares pulmonares inferiores (vascularização)**
  - Bilaterais e simétricas
  - Obliteração dos bordos cardíacos
  - **Black pleura sign**

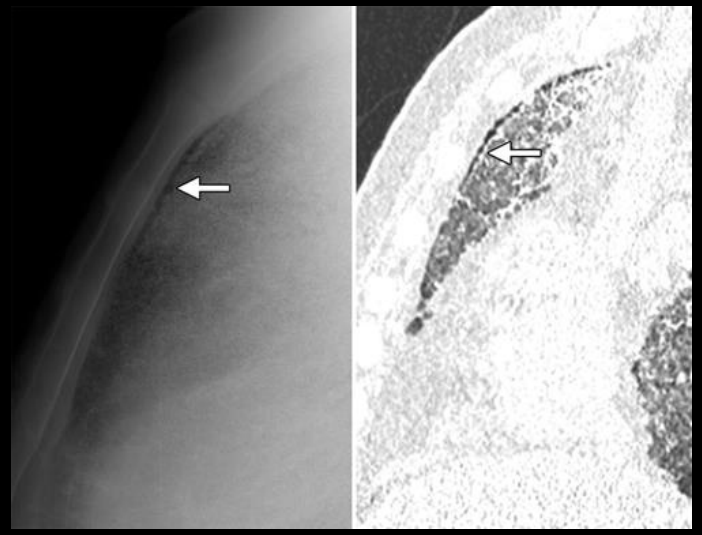

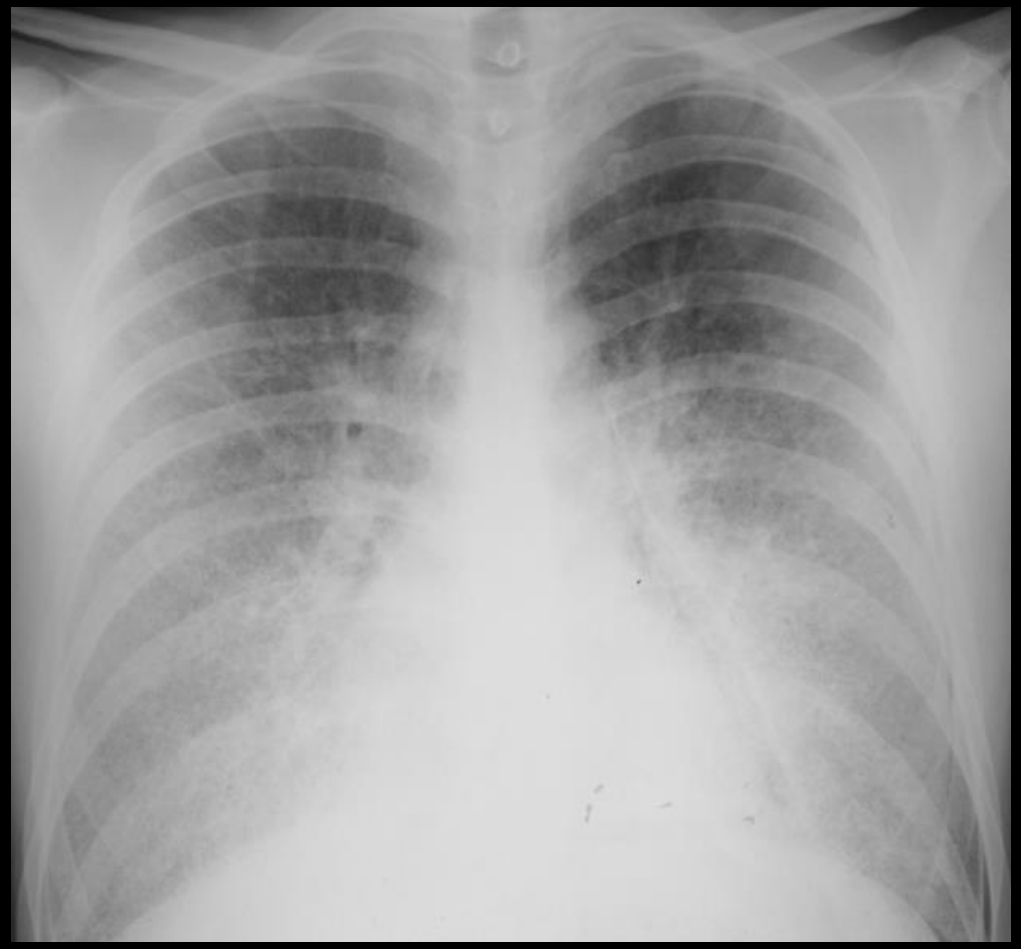

Serviço de Imagem Médica, CHUC

Microlitíase Alveolar Pulmonar MAP

Imagiologia

TC

- Calcificações finas (< 1 mm)
- **Lobos inferiores (segmentos posteriores)**
- Espessamento dos septos interlobulares
- Calcificações pleurais
- Quistos subpleurais

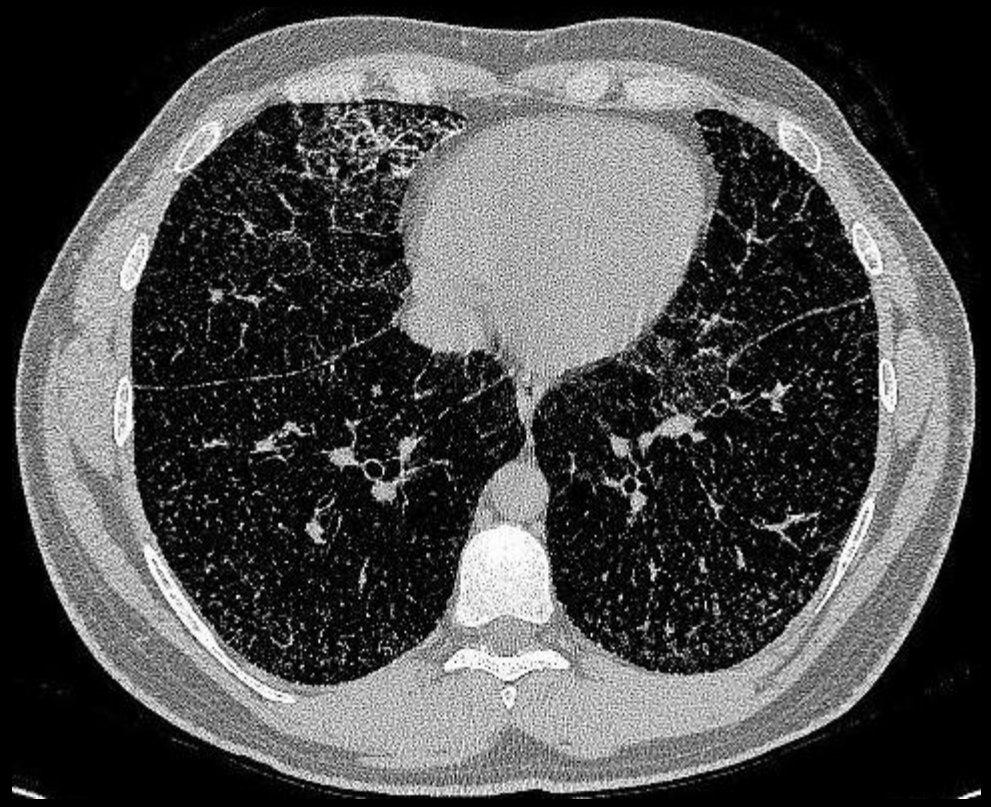

Serviço de Imagem Médica, CHUC

Ossificação pulmonar difusa OPD

Deposição de osso heterotópico maduro no parênquima pulmonar

- ♂
- 2ª-4ª década de vida

Mais frequente na **estenose mitral**

- Complicação tardia

Clínica

- Assintomática
- Semelhante a estenose mitral
  - Dispneia e edema dos membros inferiores
  - Hemoptises (raras)



Ossificação pulmonar difusa

Imagiologia

Radiografia

- Sinais de aumento da AE
- Opacidades micronodulares calcificadas no parênquima pulmonar
  - Andares inferiores
  - Assimétricas

TC

TC alta resolução

- Calcificações punctiformes
  - Andares inferiores (assimétricas)
  - Sub-pleurais
  - Podem confluir em trabéculas

Silicose

Pneumoconiose que resulta da inalação de **Sílica** SiO_2

- Risco dose-dependente
- Após 10 a 20 anos de início da exposição

Classificação

- Aguda vs Crónica
- Simples vs Complicada

Clinica

- Dispneia, tosse e febre (Aguda)

Complicações: Carcinoma e Tuberculose

Silicose

Imagiologia

Silicose simples

Apresentação imagiológica semelhante à **Pneumoconiose dos trabalhadores do carvão**

Radiografia

- Micronódulos bem delimitados
  - Distribuição difusa ou predominando nos **lobos superiores**
  - Podem calcificar
- Hilos de contornos polilobulados

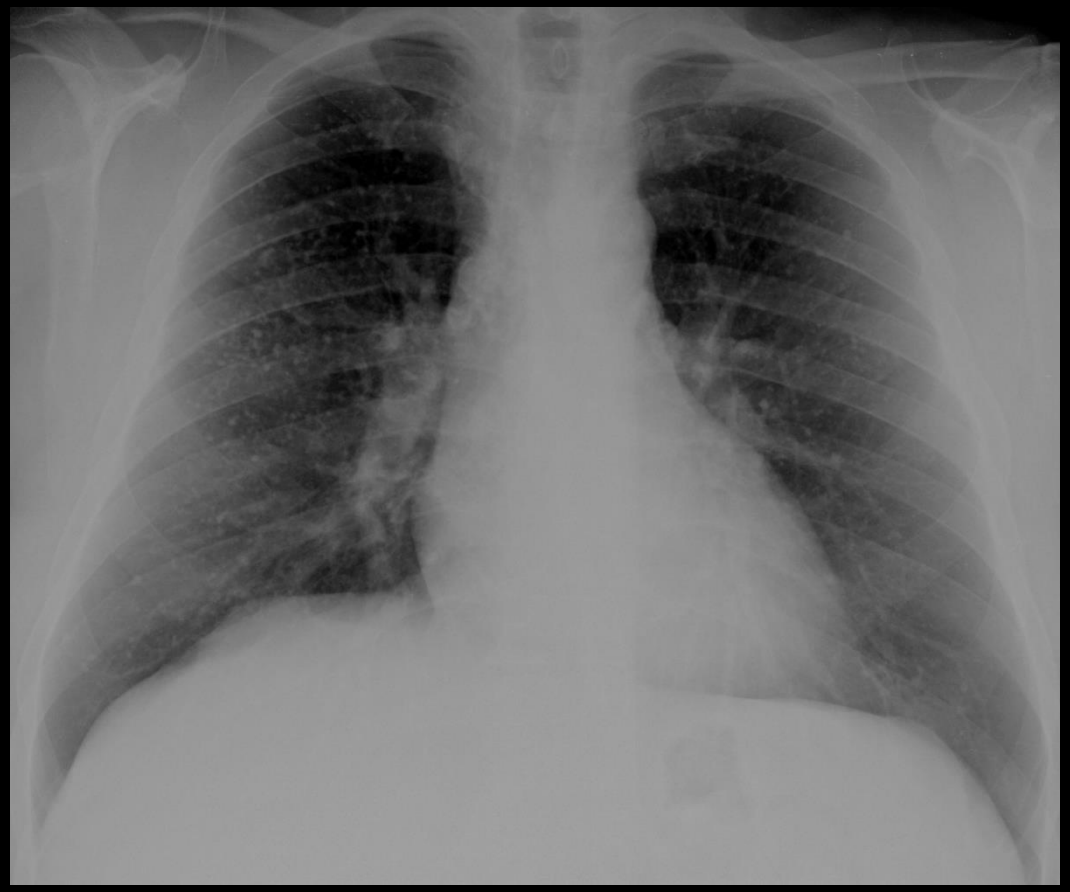

Serviço de Imagem Médica, CHUC

Silicose

Imagiologia

Silicose simples

TC **TC alta resolução**

Maior sensibilidade

- Múltiplas opacidades (1-10 mm)
  - Subpleurais ou centrilobulares
  - Predomínio nos **lobos superiores (porção posterior)**
  - Calcificam em 10-20%
- Adenopatias hilares ou mediastínicas
  - Calcificam frequentemente à periferia – **“em casca de ovo”**

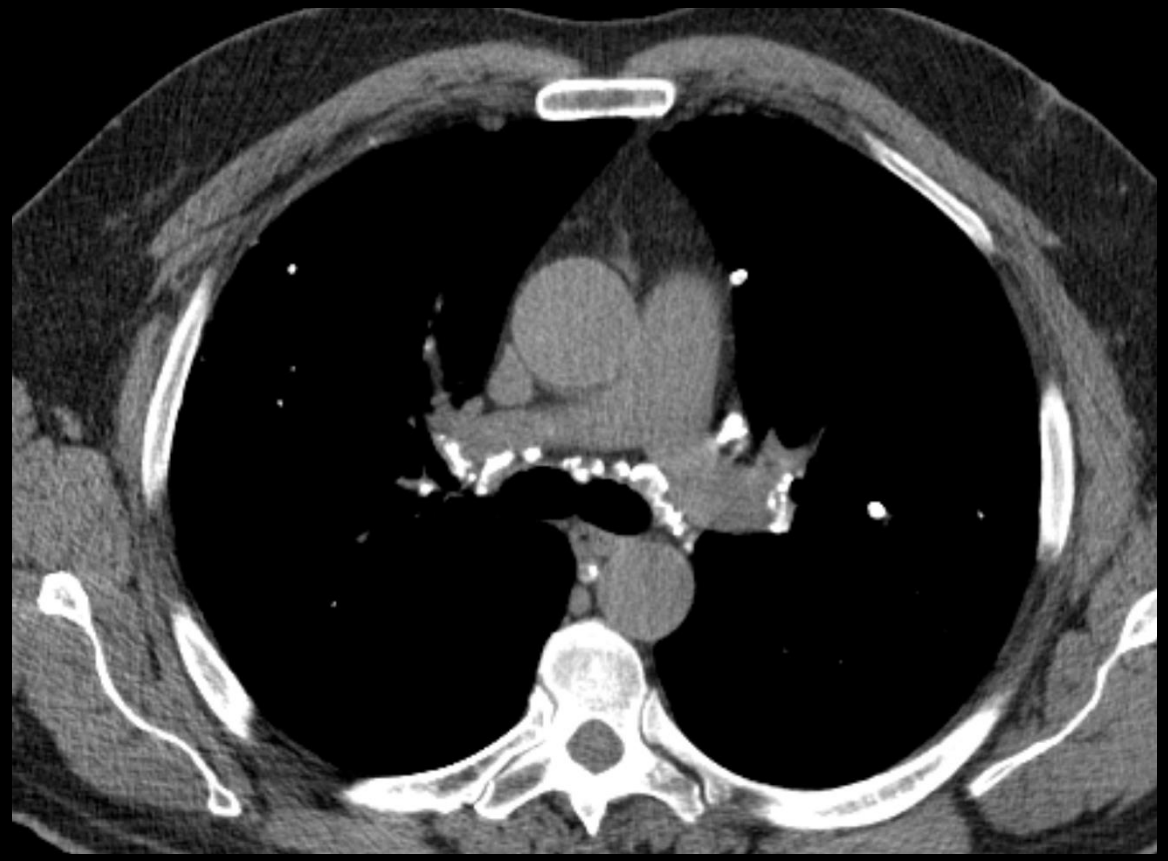

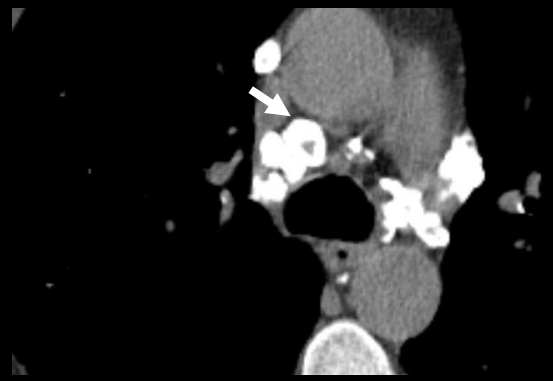

Serviço de Imagem Médica, CHUC

Calcificação metastática

Deposição de cálcio em tecido normal
- **Pulmão** é dos locais mais frequentes

- Etiologia
  - **DRC**
  - Hiperparatiroidismo primário
  - Hipervitaminose D
- Clinica
  - Assintomática
  - Insuficiência Respiratória
  - Sintomas não se correlacionam com grau de alterações imagiológicas
- **Elevação sérica do cálcio e fósforo**

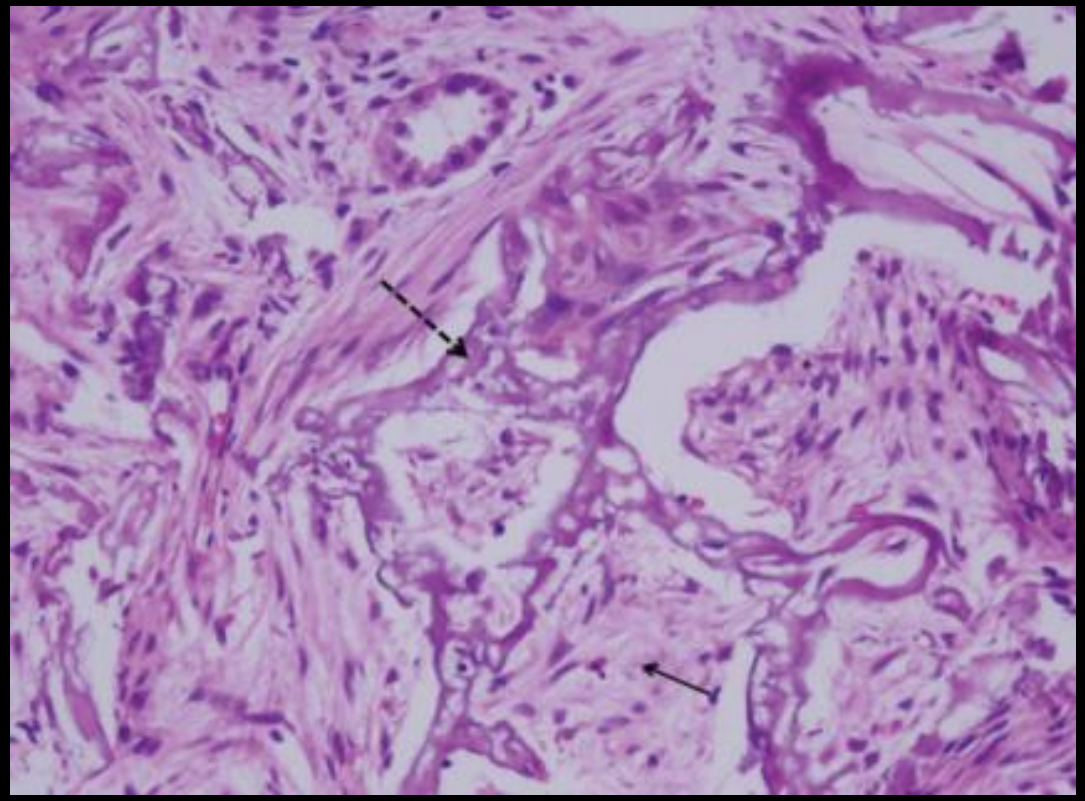

Calcificação metastática

Imagiologia

Radiografia

Baixa sensibilidade (< 15%)

- Frequentemente normal ou achados não específicos
  - Infiltrado intersticial
  - Opacidades alveolares confluentes ou dispersas

- Alterações imagiológicas potencialmente reversíveis

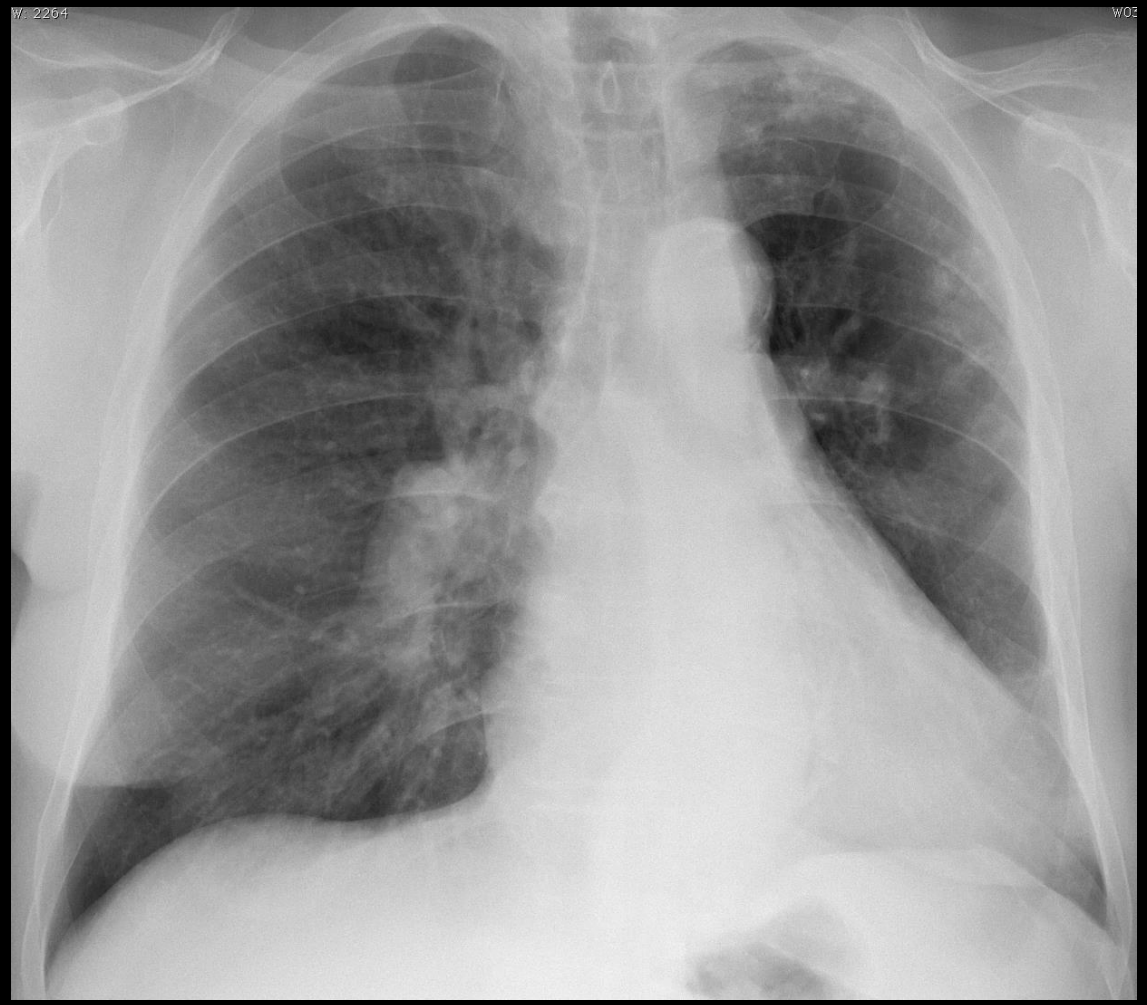

Serviço de Imagem Médica, CHUC

Calcificação metastática

Imagiologia

TC

TC de alta resolução

Excelente sensibilidade

- Múltiplos nódulos calcificados por todo o pulmão ou apenas nos ápices
- Associado a calcificações das paredes brônquicas, miocárdio ou dos vasos da parede torácica

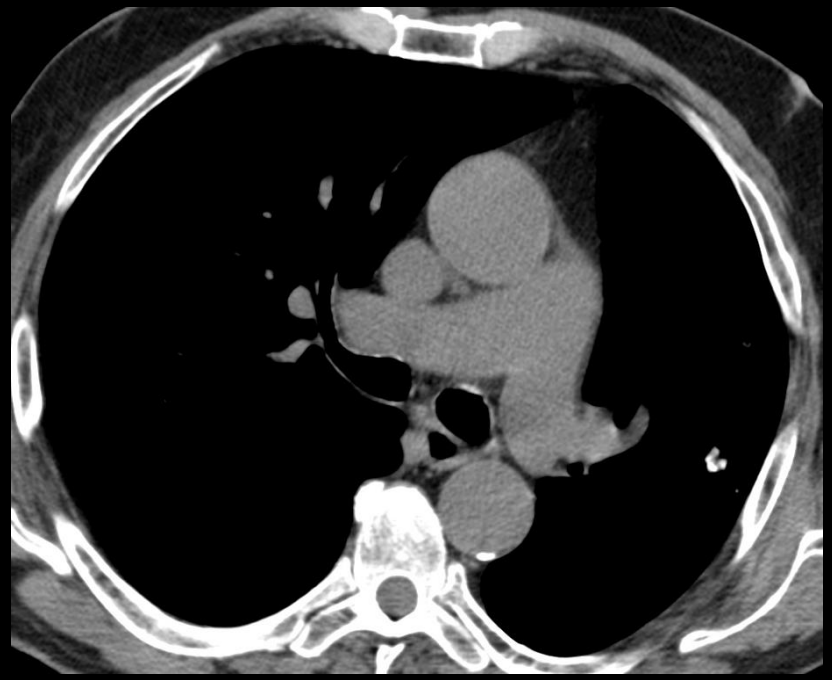

Serviço de Imagem Médica, CHUC

Metástases pulmonares com calcificações

Tumores ósseos

- Osteosarcoma
- Condrosarcoma
- Tumor de células gigantes

Outros

- Tiróide (Papilar)
- Cólon
- Ovário
- Mama

Metástases pulmonares com calcificações

Osteosarcoma

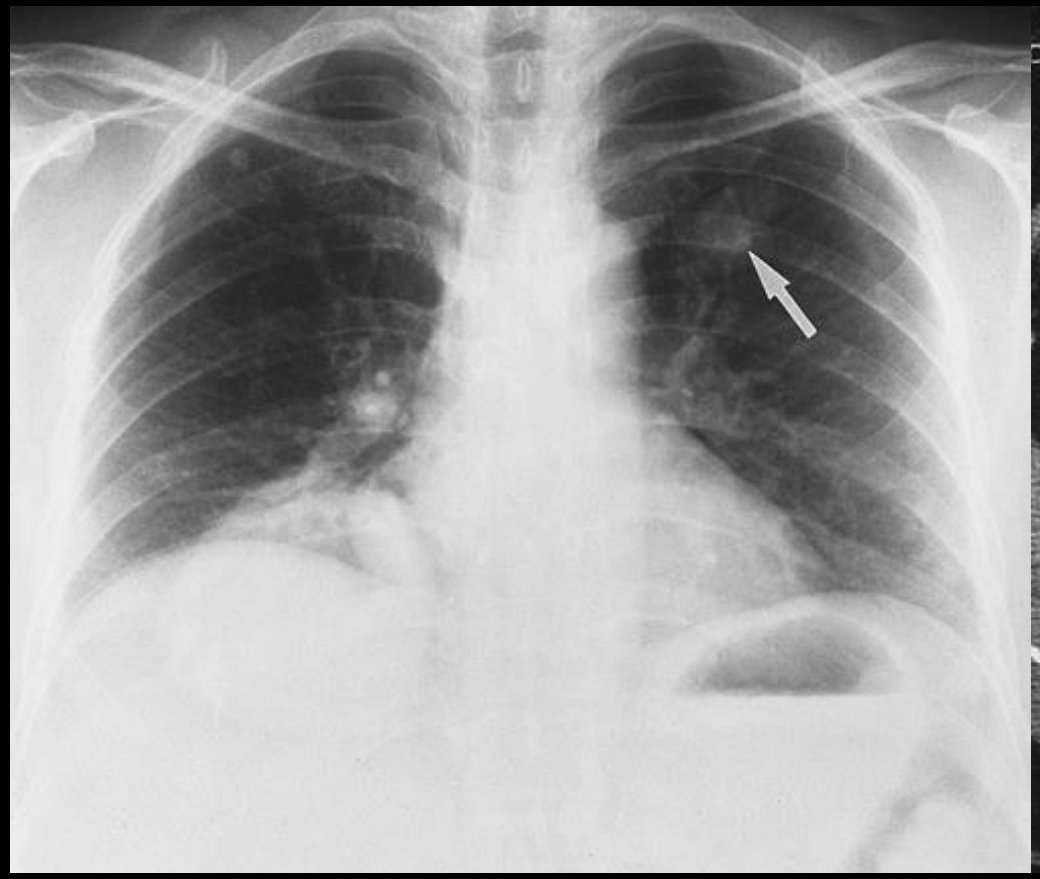

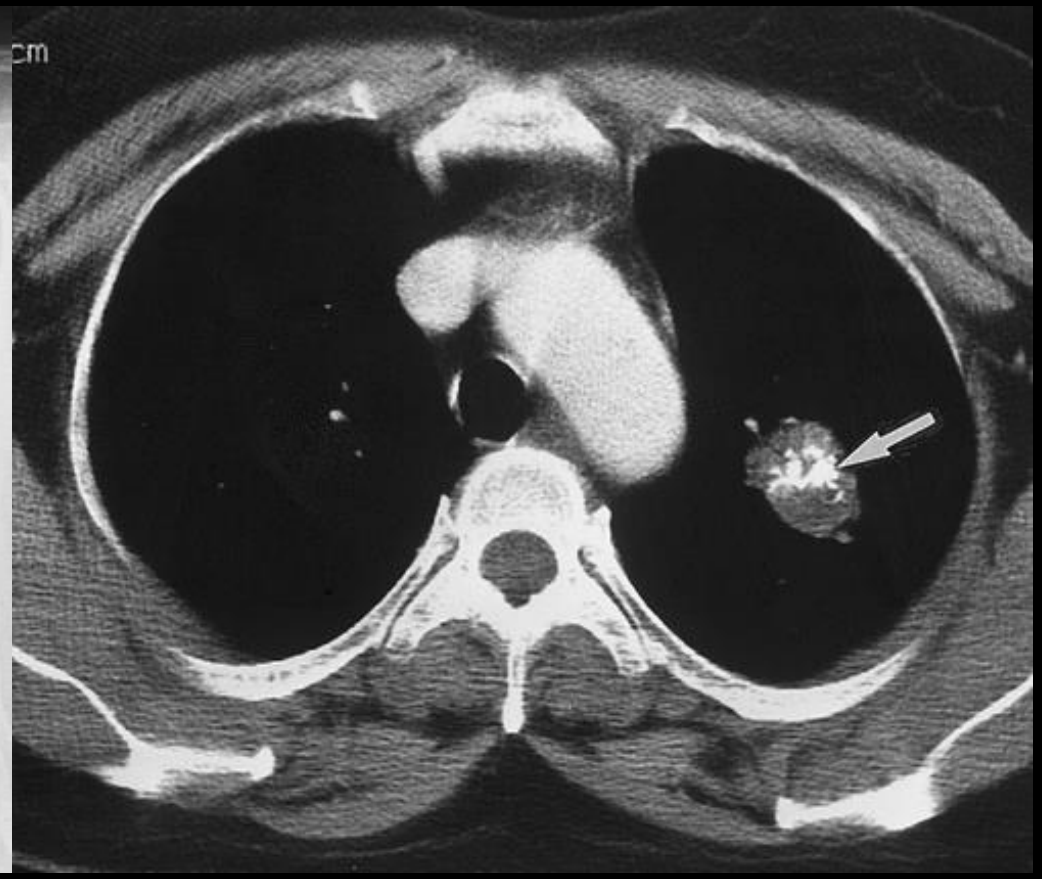

Metástases pulmonares com calcificações

Adenocarcinoma do recto

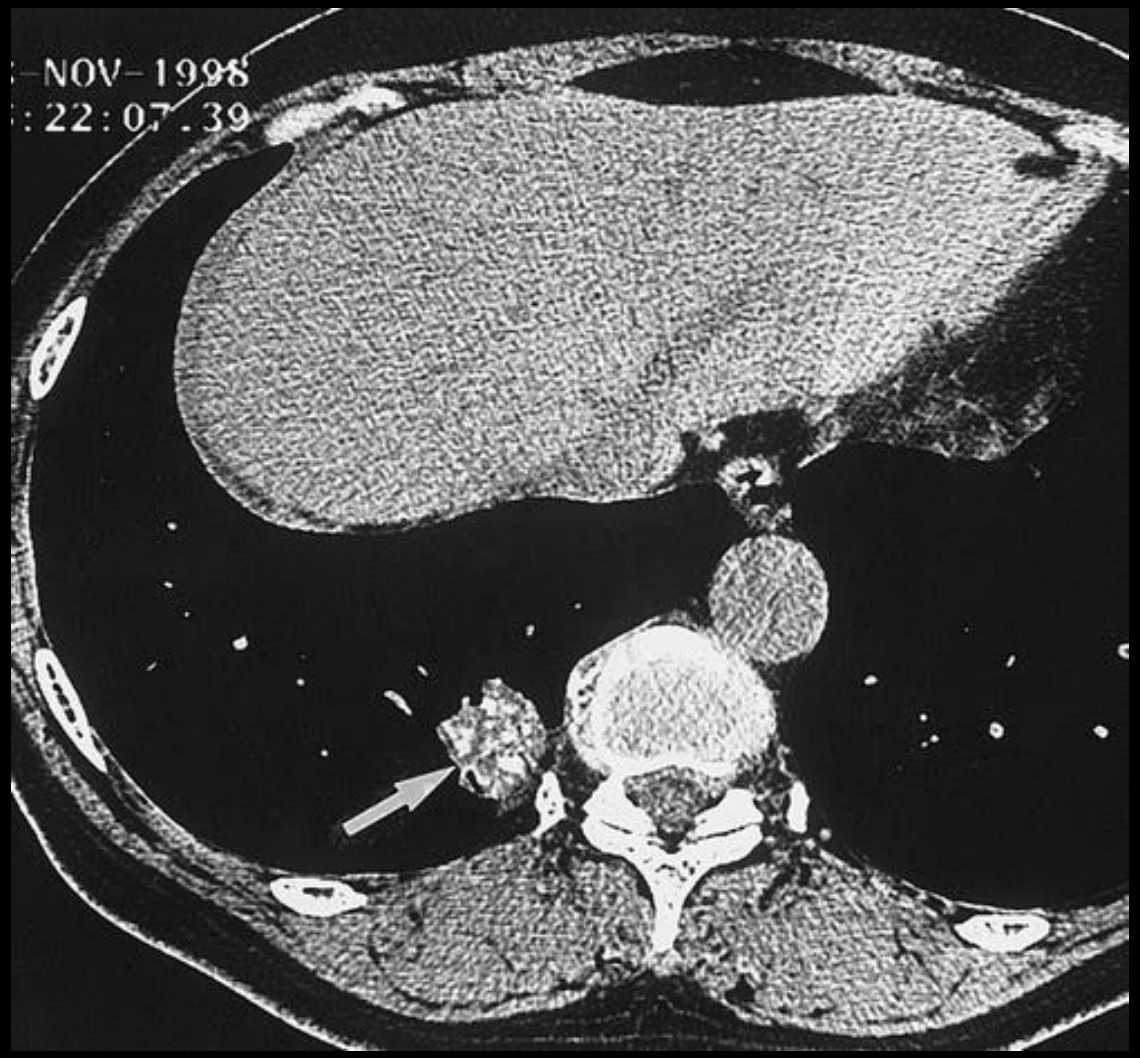

Pneumonia por Varicela

No adulto

- Mais frequente em doentes **imunocomprometidos**
- Fumadores

Clínica

- **1 a 6 dias aparecimento do rash**
- Dispneia, tosse e febre
- Dor pleurítica

Mortalidade

- Até 22 % nos imunocomprometidos

Pneumonia por Varicela

Imagiologia

Com a cicatrização de lesões cutâneas as alterações imagiológicas desaparecem (semanas a meses)

- Podem **permanecer até 2 % dos casos**

Radiografia

- Opacidades nodulares de limites mal definidos
  - Dispersas
- Opacidades reticulares
  - Periferia (++)
- Adenopatias hilares
- Derrame pleural (30%)

Pneumonia por Varicela

Imagiologia

TC

- Nódulos (5-10 mm)
  - Distribuição miliar
  - Podem coalescer
  - Rodeados por opacidade em vidro despolido – **sinal do halo**

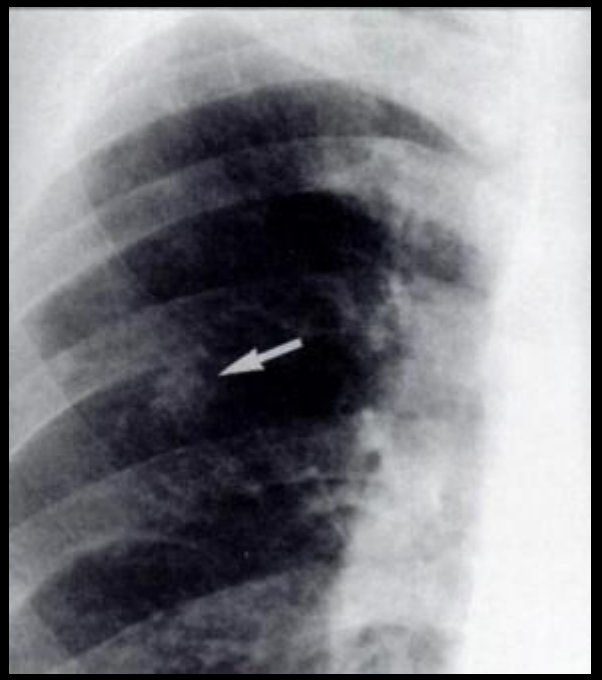

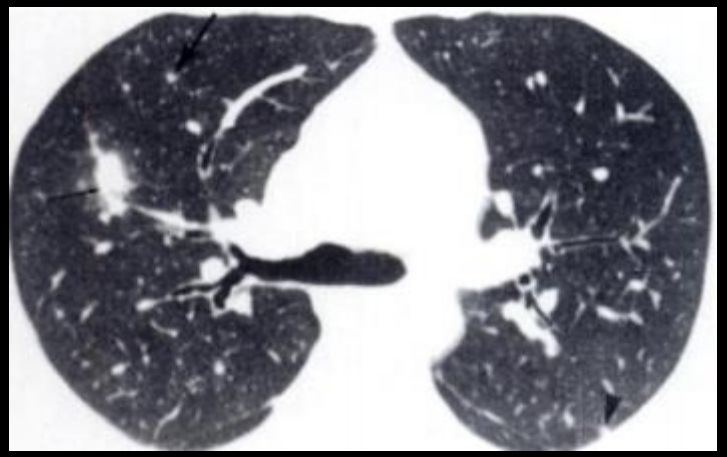

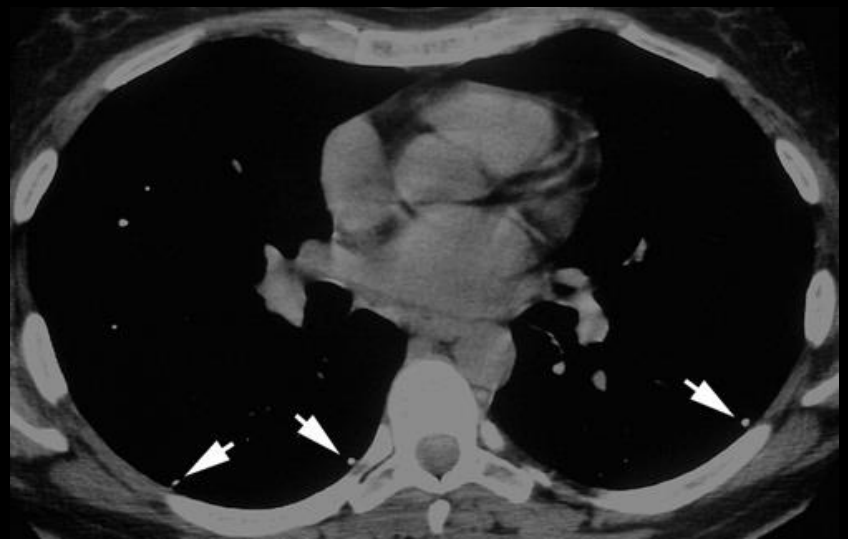

Tuberculose (miliar)

Doentes expostos ao **Mycobacterium Tuberculosis**

- Manifestação de TB primária
- 1 a 3% dos casos de TB

Melhoria imagiológica rápida com o tratamento

- **Calcificação é pouco frequente**

Tuberculose (miliar)

Imagiologia

- Nódulos (2-3 mm) com distribuição difusa
  - Predomínio nos **lobos inferiores**
- Adenopatias
  - Unilaterais (direita) ou bilaterais
  - Necrose
  - Podem calcificar
- Derrame pleural
  - Unilateral
  - Pode calcificar

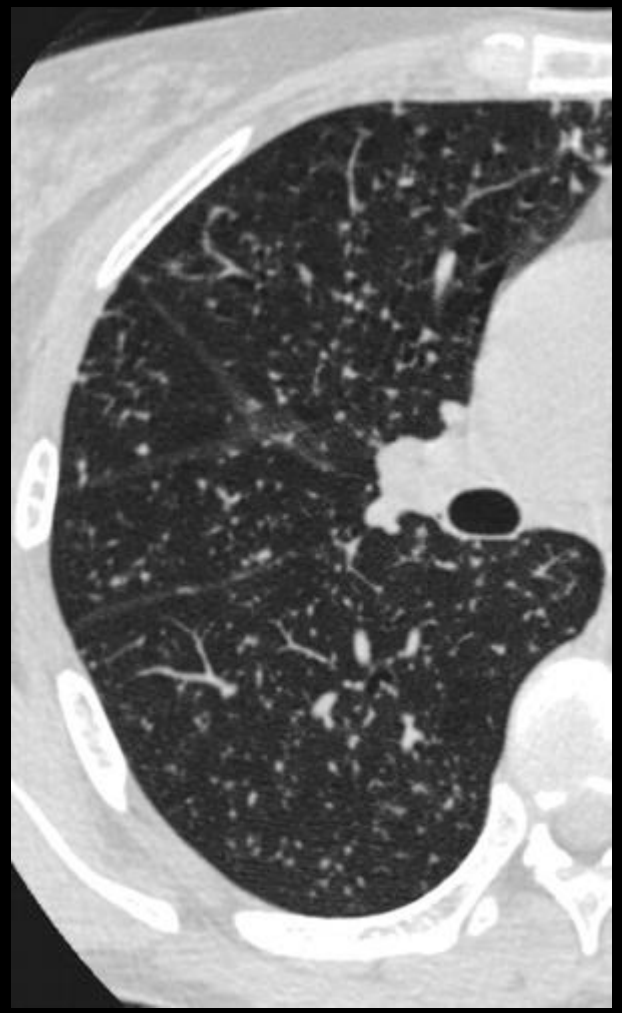

Amiloidose

Doença sistémica pela deposição extracelular de **amilóide**

- Pode envolver qualquer órgão

Epidemiologia

- 5ª - 6ª década de vida

Três formas de Amiloidose Pulmonar:

- Intersticial difusa
- **Nodular**
- Traqueobrônquica

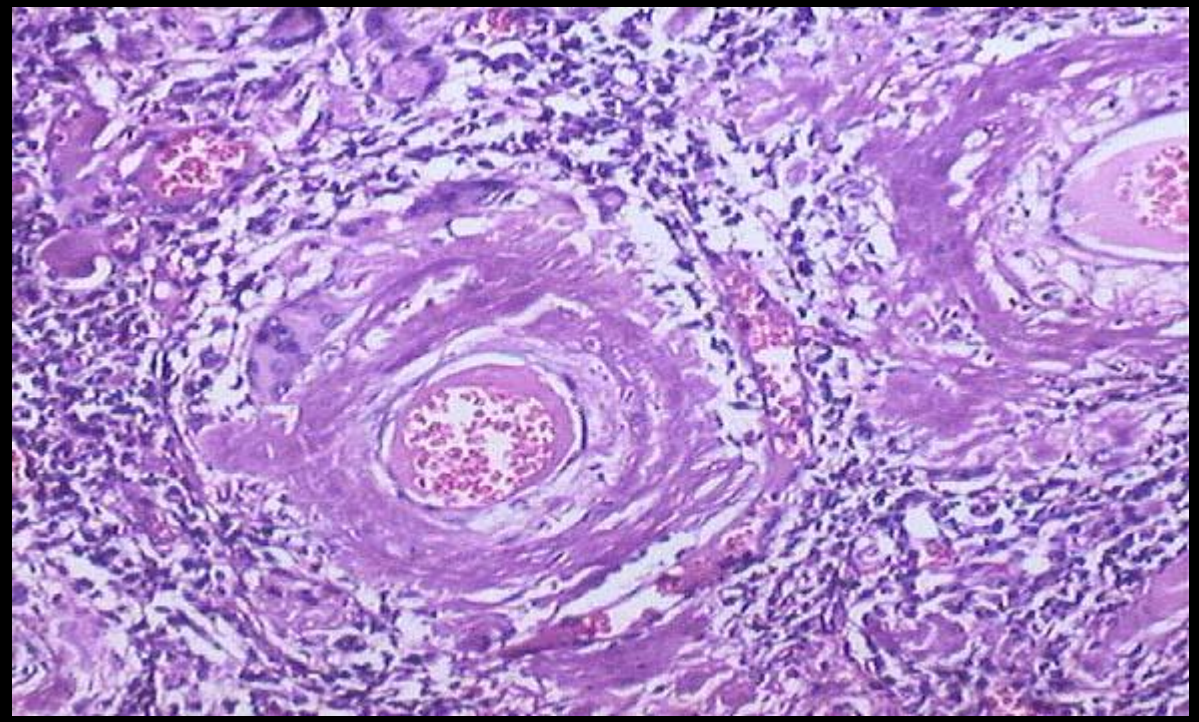

Amiloidose nodular

Imagiologia

Nódulo único ou múltiplos

- Lobos inferiores
- Contornos lobulados
- Tamanho variável (0.5 a 15 cm)
- Calcificação central e irregular (50%)
- Crescimento lento, durante anos
- Podem cavitar (raro)

Adenopatias (Forma Sistémica)

- Podem calcificar

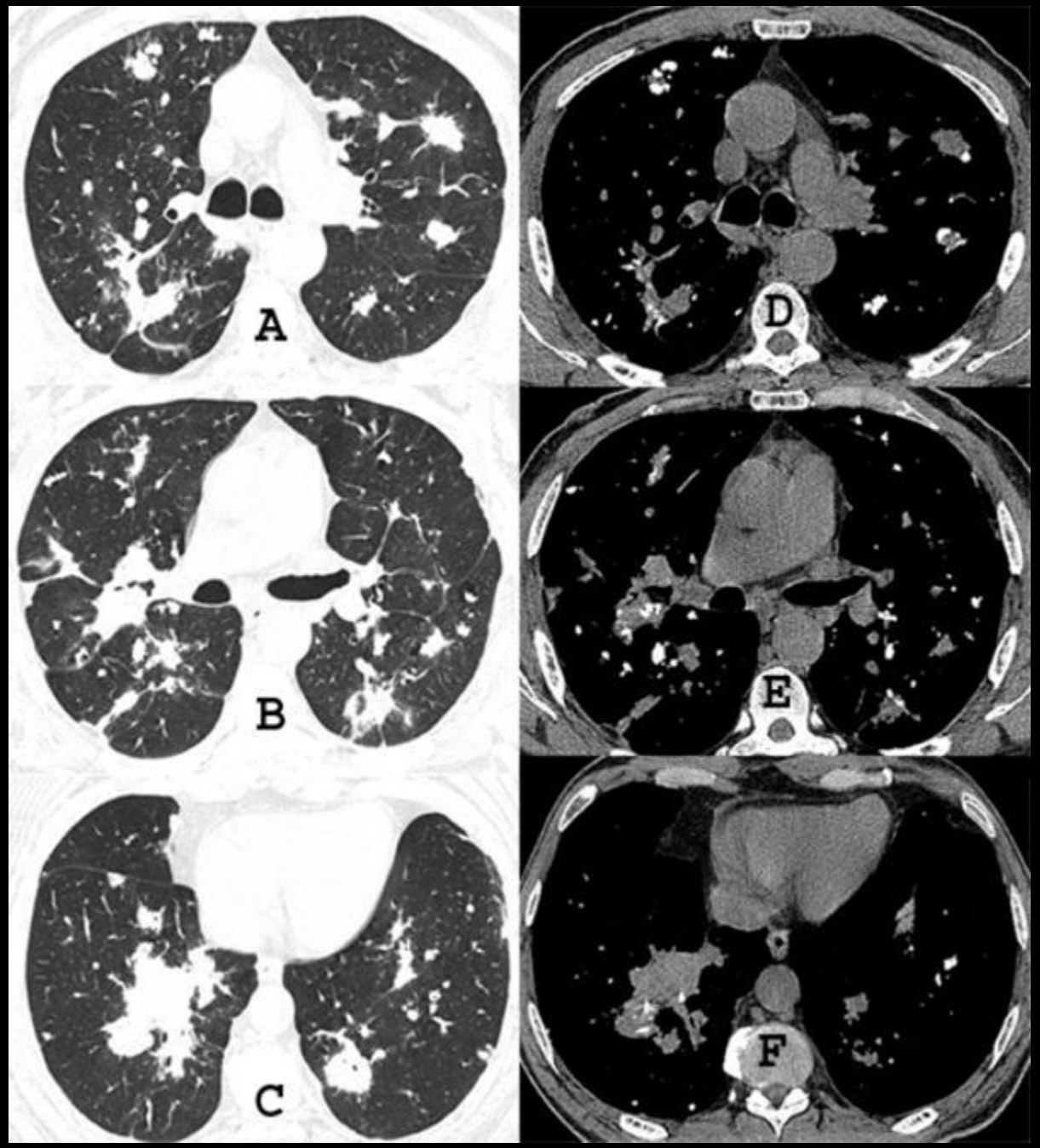

?

História clínica

Seguido em consulta de Cardiologia por Estenose mitral de longa evolução

- Área valvular 1,1 cm^2
- Doente não considerado para Valvulotomia pela idade e co-morbilidades

Evolução

Agudização da DPOC

- Internamento
- Morte 3 semanas após a realização da TC tórax
- Não foi realizada autópsia

Diagnóstico provável

Ossificação pulmonar difusa secundária à estenose mitral

Ossificação pulmonar difusa secundária à estenose mitral

Causa mais frequente de OPD

- 2ª a 4ª década de vida
- Após a 6ª década

Raros casos descritos na literatura

- Primeira descrição em 1932 [Salinger]
- 3 a 13 % dos doentes com estenose mitral de longa evolução
- Percentagem maior em autópsias

Doença indolente e de lenta progressão

Ossificação pulmonar difusa secundária à estenose mitral

Fisiopatologia

Várias teorias

- Congestão pulmonar
- Proliferação de tecido conjuntivo
- Deposição de hemossiderina
- **Pequenas hemorragias pulmonares recorrentes**

História de lesões pulmonares repetidas (?)

- Pneumonias recorrentes

Cálcio e fósforo séricos normais

Ossificação pulmonar difusa secundária à estenose mitral

Clínica

Assintomáticos

Sinais e sintomas de estenose mitral

- Dispneia
- Fadiga
- Edema dos membros inferiores
- Hemoptses (raras)

Testes de função pulmonar

- Doença pulmonar restritiva
- Diminuição da capacidade de difusão

Ossificação pulmonar difusa secundária à estenose mitral

Imagiologia

Sinais de estenose mitral

Opacidades micronodulares calcificadas

- Poupam os ápices
- Mais numerosas nas **bases pulmonares**
- **Assimétricas**
- Subpleurais
- Podem convergir, formando trabéculas

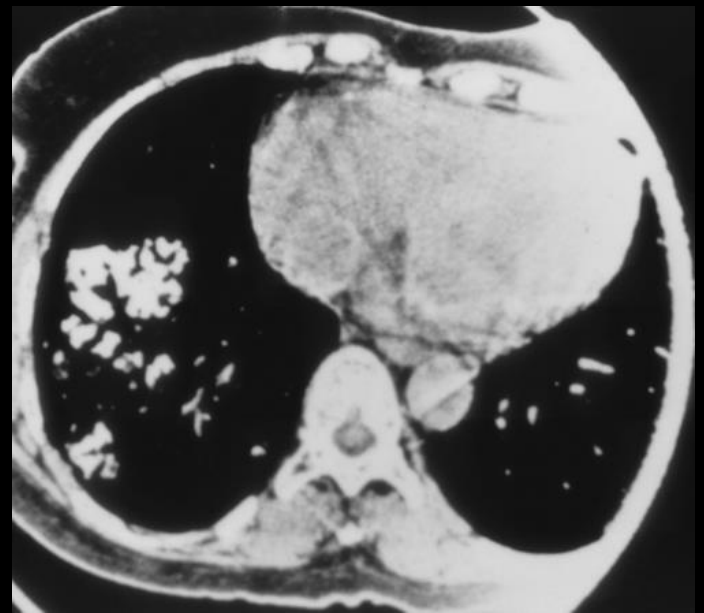

Ossificação pulmonar difusa secundária à estenose mitral

Imagiologia

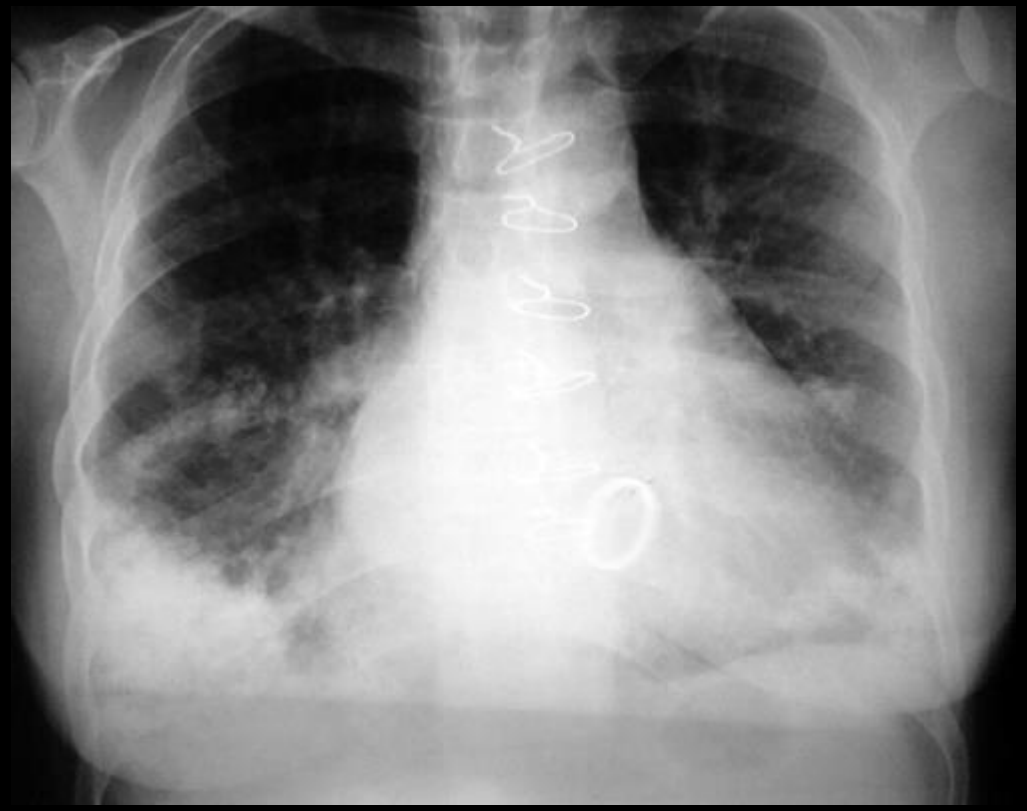

Ossificação pulmonar difusa secundária à estenose mitral

Histologia

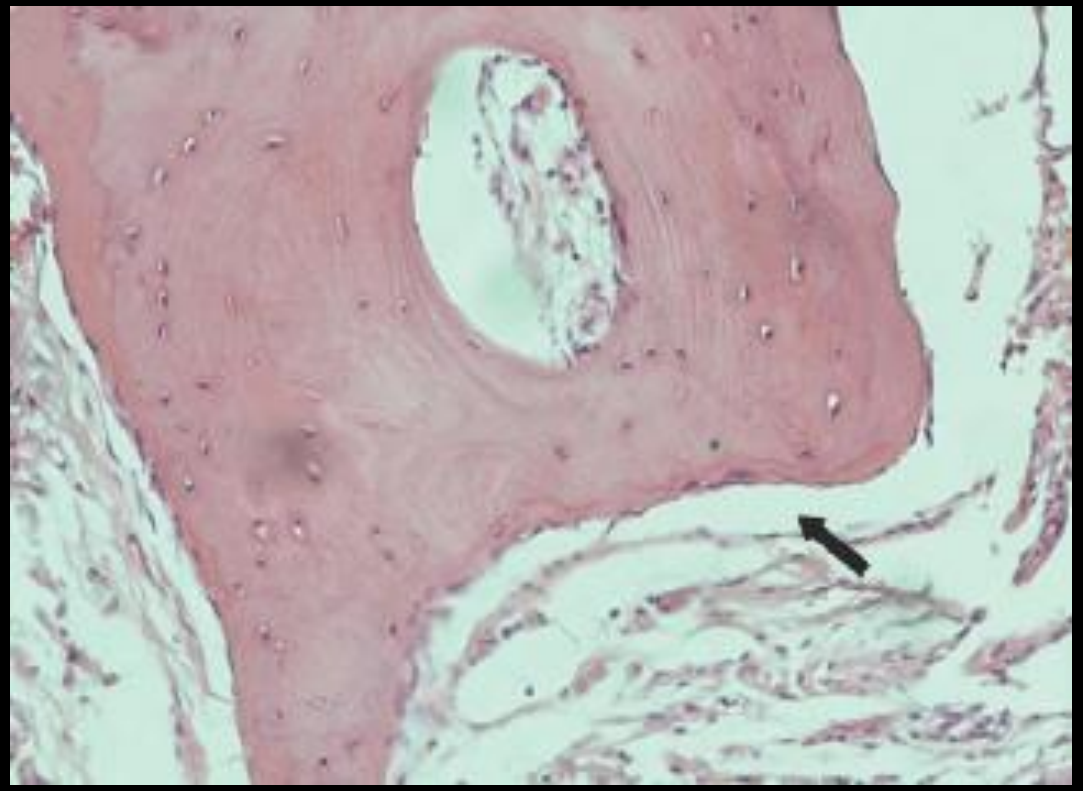

Ossificação pulmonar difusa secundária à estenose mitral

Tratamento

Tratamento da estenose mitral

Corticóides sistémicos e dietas baixas em cálcio sem benefício

Varfarina e **bifosfonatos** são potenciais terapêuticas

- Benefício ainda por comprovar

Bibliografia

Calcificações parenquimatosas pulmonares

1. Brown K., Mund D., Aberle D. et al. Intrathoracic calcifications: Radiographic features and differential diagnoses, Radiographics (1994) 14:1247-1261

2. Bendayan D., Barziv Y., Kramer M. Pulmonary calcifications: a review. Respiratory Medicine (2000) Vol 94, issue 3, 190-193.

3. Khan A., Jahdali H., Allen C. et al. The calcified lung nodule: What does it mean? Annals of Thoracic Medicine (2010) 67-79

OPD

4. Salinger H. Die Knochenbildungen in der Lunge mit besonderer Berucksichtigung der tuberösen Form. Fortschr. Roentgenstr. 1932; 46:269.

5. Galloway R., Epstein E. and Coulshed N. Pulmonary ossific nodules in mitral valve disease. *Br Heart J* 1961; 23(3): 297–307.

6. Wilson W., Sasaki R. and Johnson C. Disseminated Nodular Pulmonary Ossification in Patients with Mitral Stenosis. Ahassociation. *Circulation* 1959; 19: 323-331 doi: 10.1161/01.CIR.

7. Burkett A., Coffey N. and Voduc N. Diffuse pulmonary ossification as a rare cause of interstitial lung disease. *Can Respir J* 2014; 21(1): 23–24.

8. Chan E., Morales D., Welsh C. et al.Calcium deposition with or without bone formation in the lung.Am J Respir Crit Care Med. 2002 165(12):1654-69.

9. Konoglou M., Zaragoulidis P., Baliaka A. et al. Lung ossification: an orphan disease. Journal of thoracic disease. 2013, Vol 5, No 1

10. Woolley K., Stark P. Pulmonary Parenchymal Manifestations of Mitral Valve Disease. Radiographics. 1999, Vol 19, issue 4.

Bibliografia

MAP

11. Francisco F., Silva J., Hochhegger B., et al. Pulmonary alveolar microlithiasis. State-of-the-art review. Respiratory Medicine (2013) vol 107, 1-9.

12. Ahmad K., Gupta M., Dhungel K. et al. Pulmonary Alveolar Microlithiasis: A rare case Report. Iranian Journal of Medicine Sciences (2013) 267-270.

13. Siddiqui N. and Fuhrman C. Best cases from the AFIP: Pulmonary Alveolar Microlithiasis. Radiographics (2011) vol 31, issue 2.

14. Chang L., Bux S., Liam C., et al. Sandstorm Appearance of Pulmonary Alveolar Microlithiasis Incidentally Detected in a young, Asymptomatic Male. Korean Journal of Radiology (2013). 859-862.

Calcificações metastáticas

15. Alkan O., Tokmak N., Demir S., et al. Metastic Pulmonary Calcification in a Patient with chronic renal failure. J Radiol case Rep. (2009), 14-19.

16. Bozi L., Melo A., Marchiori E. Pulmonary metastic calcification: a case report. Radiol Bras (2012), vol 45, n.5.

17. Castillo M., Gimeno M., Carro B. et al. Diffuse pulmonary calcification in a patient with renal insufficiency. Archivos de Bronconeumologia (2005). 41:587-9. vol 41.

Bibliografia

Silicose

18. Chong S., Lee K., Chung m., et al. Pneumoconiosis: Comparision of Imaging and pathologic Findings. Radiographics (2006), 26:59-77.

19. Satija B., Kumar S., Ojha U. et al. Spetrum of high-resolution computed tomography imaging in occupational lung disease. Indian journal of radiology and imaging (2013), vol 23, issue 4, 287-296.

Metástases pulmonares com calcificações

20. Seon J., Im J., Goo J., et al. Atypical Pulmonary metastases: Spectrum of radiologic findings. Radiographics (2001). vol 21, issue 2.

21. Maile C., Rodan B., Godwin J. et al. Calcification in pulmonary metastases. British journal of radiology (1982), 55, 108-113.

Bibliografia

Pneumonia por Varicela

22. Gasparetto E., Warszawiak D., Tazoniero P. et al. Varicella pneumonia in immunocompetent adults: report of two cases, with emphasis on high-resolution computed tomography findings . Brazilian journal of infectious diseases 2005. vol 9. n.3.

23. Franquet T. Imaging of Pulmonary Viral Pneumonia. Radiology (2011). vol 260, issue 1.

24. Floudas M., Kanakis A., Andreopoulos et al. Nodular lung calcifications following varicella zoster virus pneumonia. QJMed (2008), 101:159.

25. Kim J., Ryu C., Lee S. High-resolution CT finding of varicella Zoster Pneumonia. AJR (1999), 172:113-116.

Metástases pulmonares com calcificações

26. Burrill J., Williams C., Bain G. et al. Tuberculosis: a radiologic review. Radiographics (2007), vol 27, issue 5.

Amiloidose

27. Vieira I., Marchiori E., Zanetti G. et al. Pulmonary amyloidosis with calcified nodules and masses - a six-year computed tomography follow-up: a case report. Case Journal (2009), 2:6540.